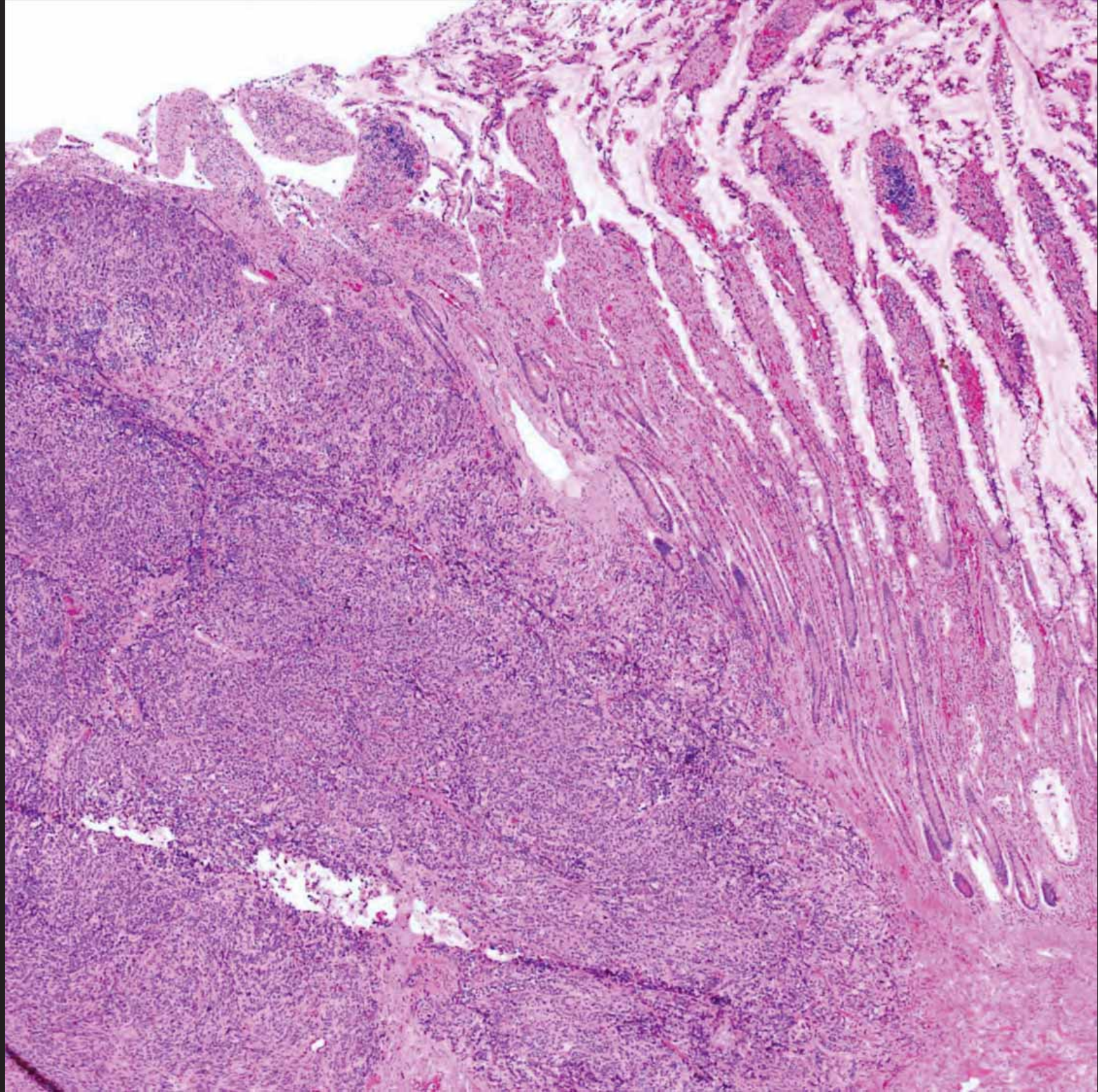


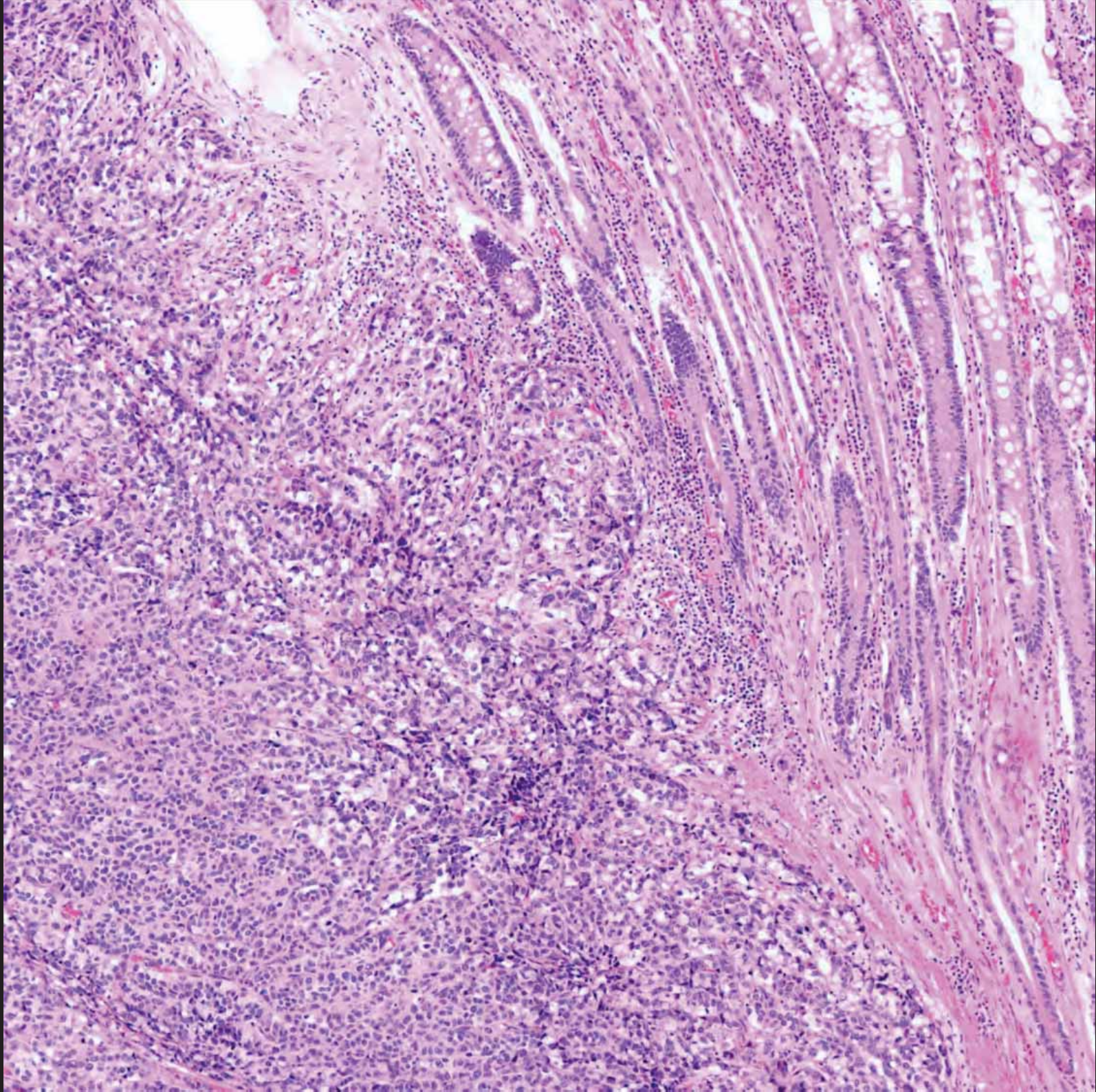
# Crowdsource

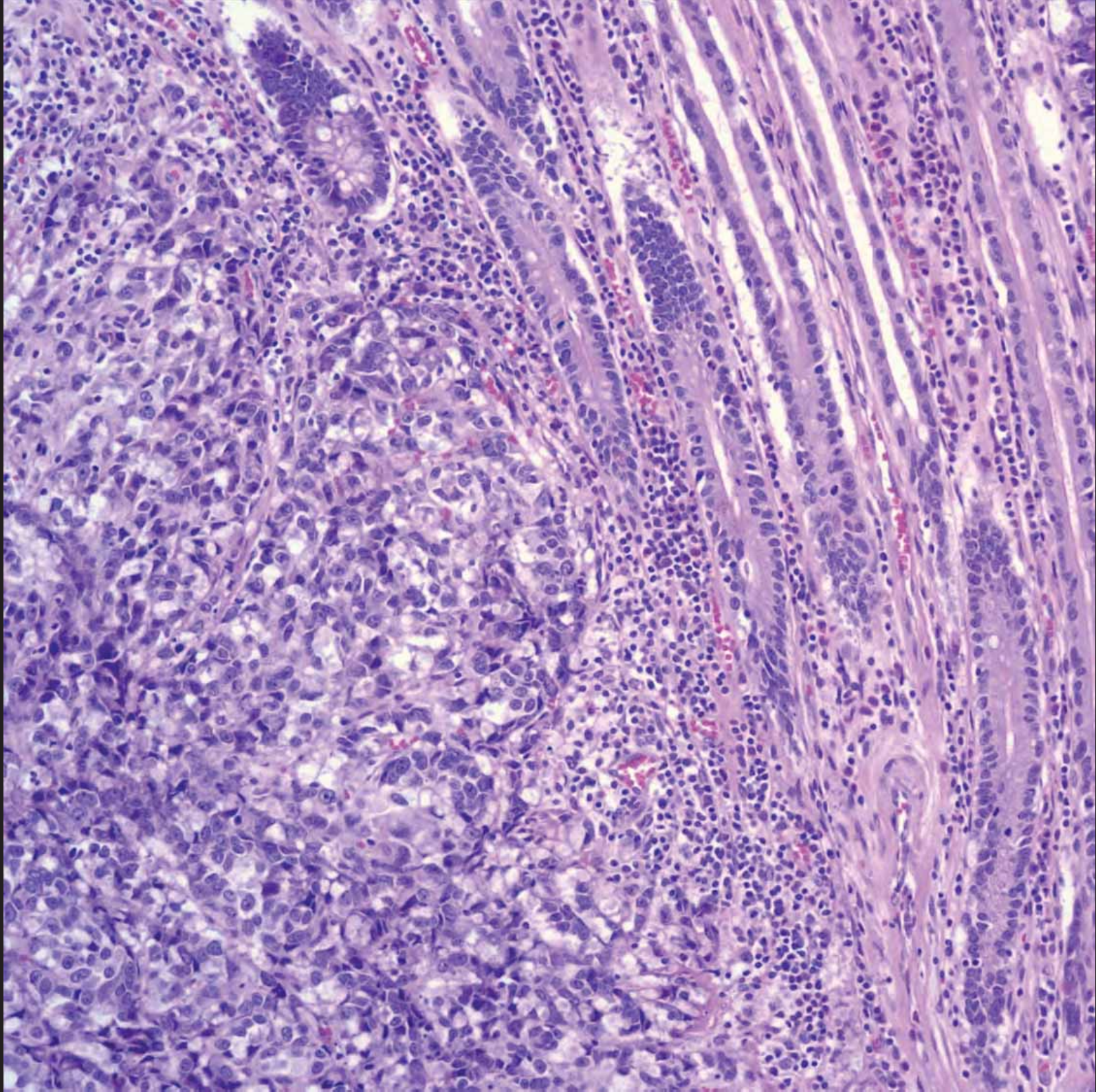
Gathering Ideas About  
potential new or emerging  
entities

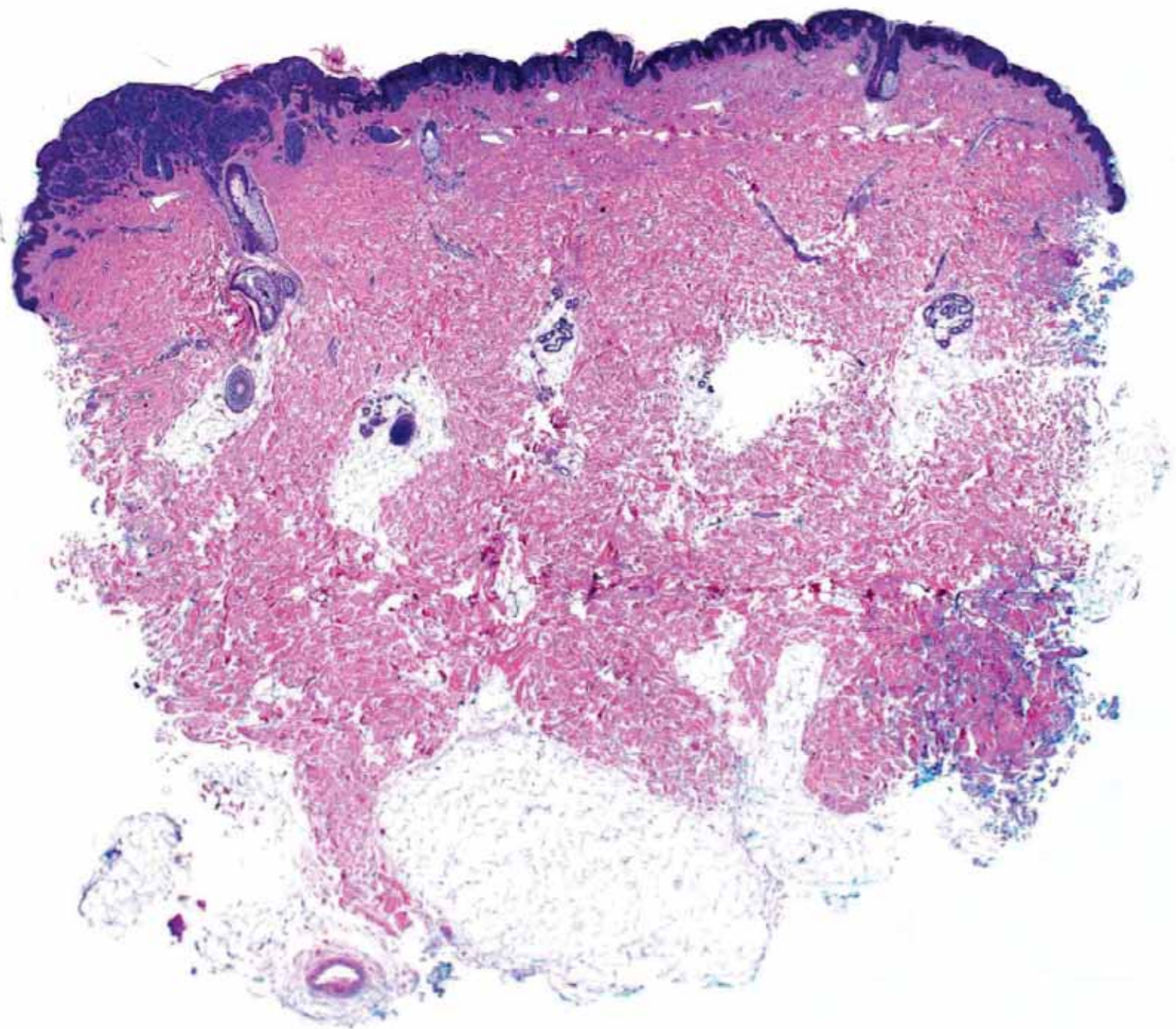
Philip E. LeBoit, M.D.

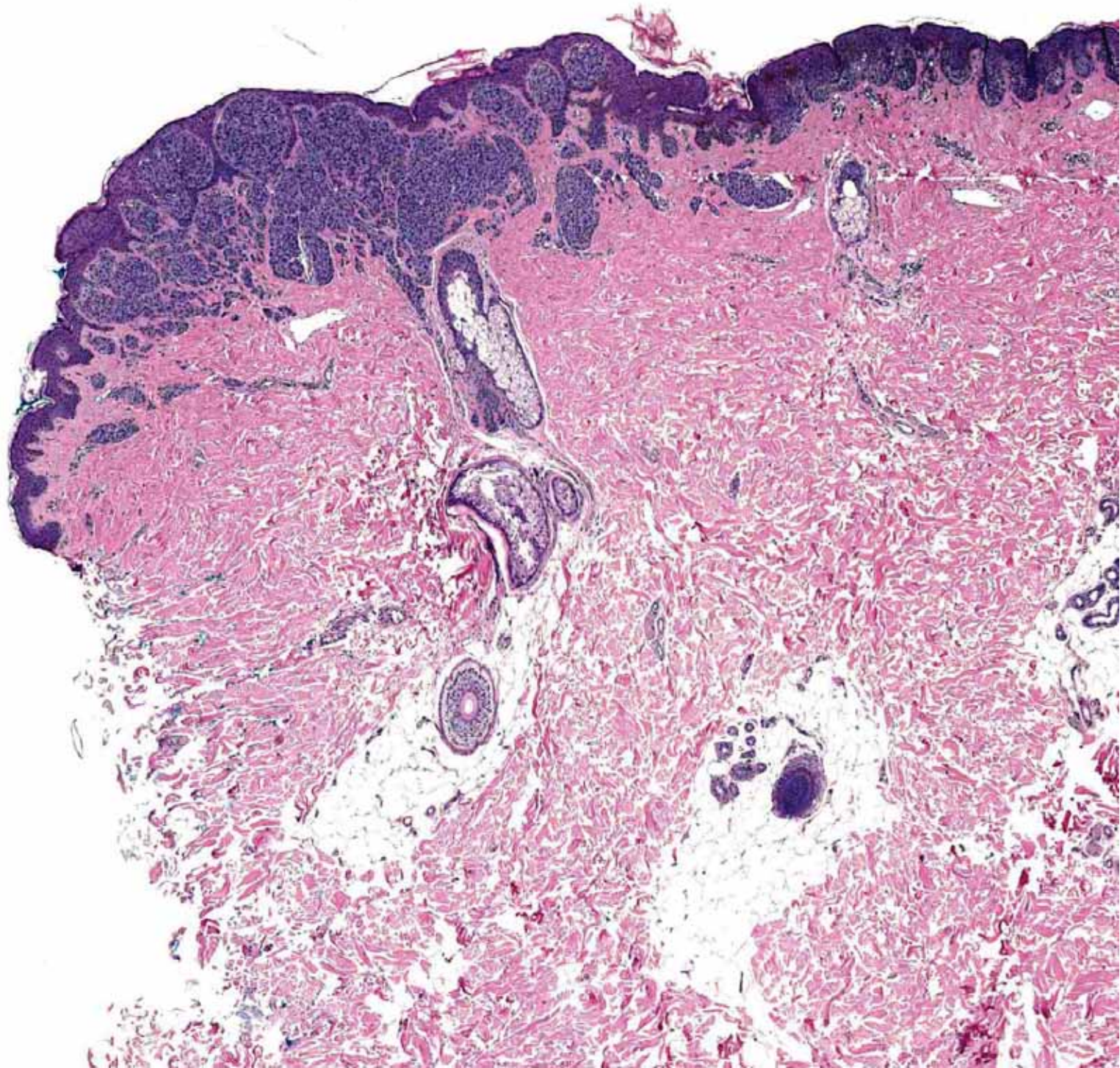
Univ. of California, San Francisco

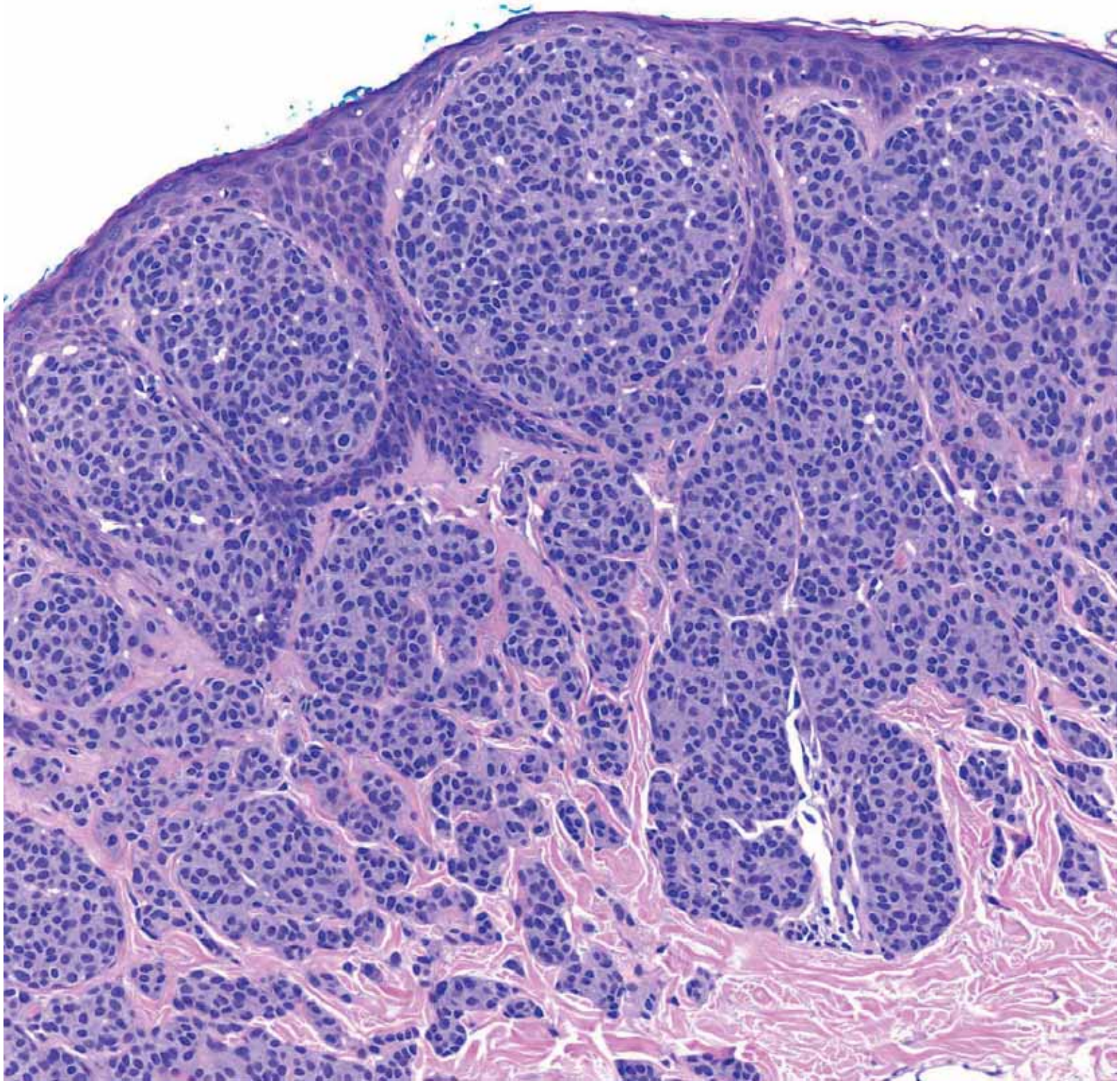


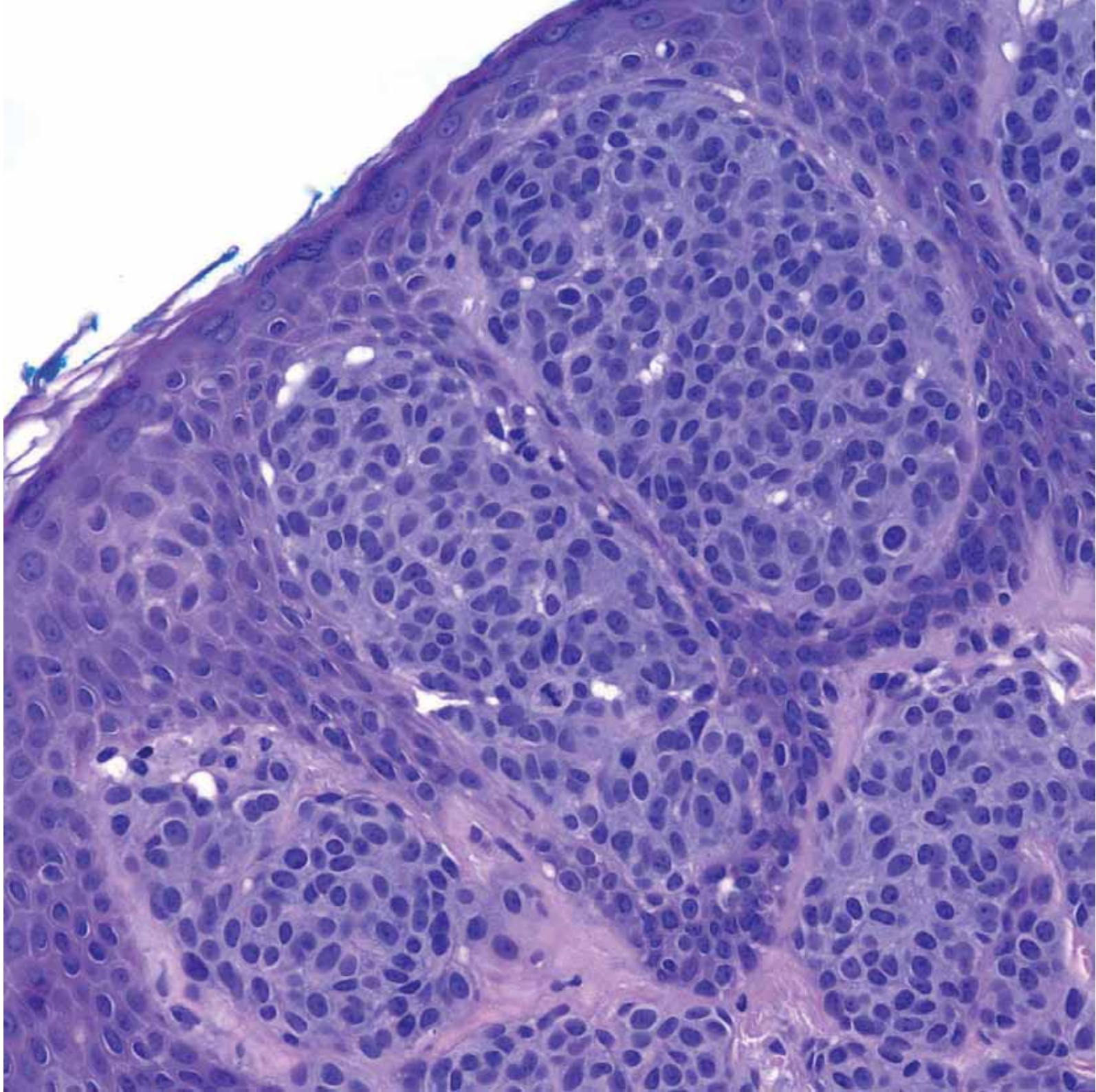


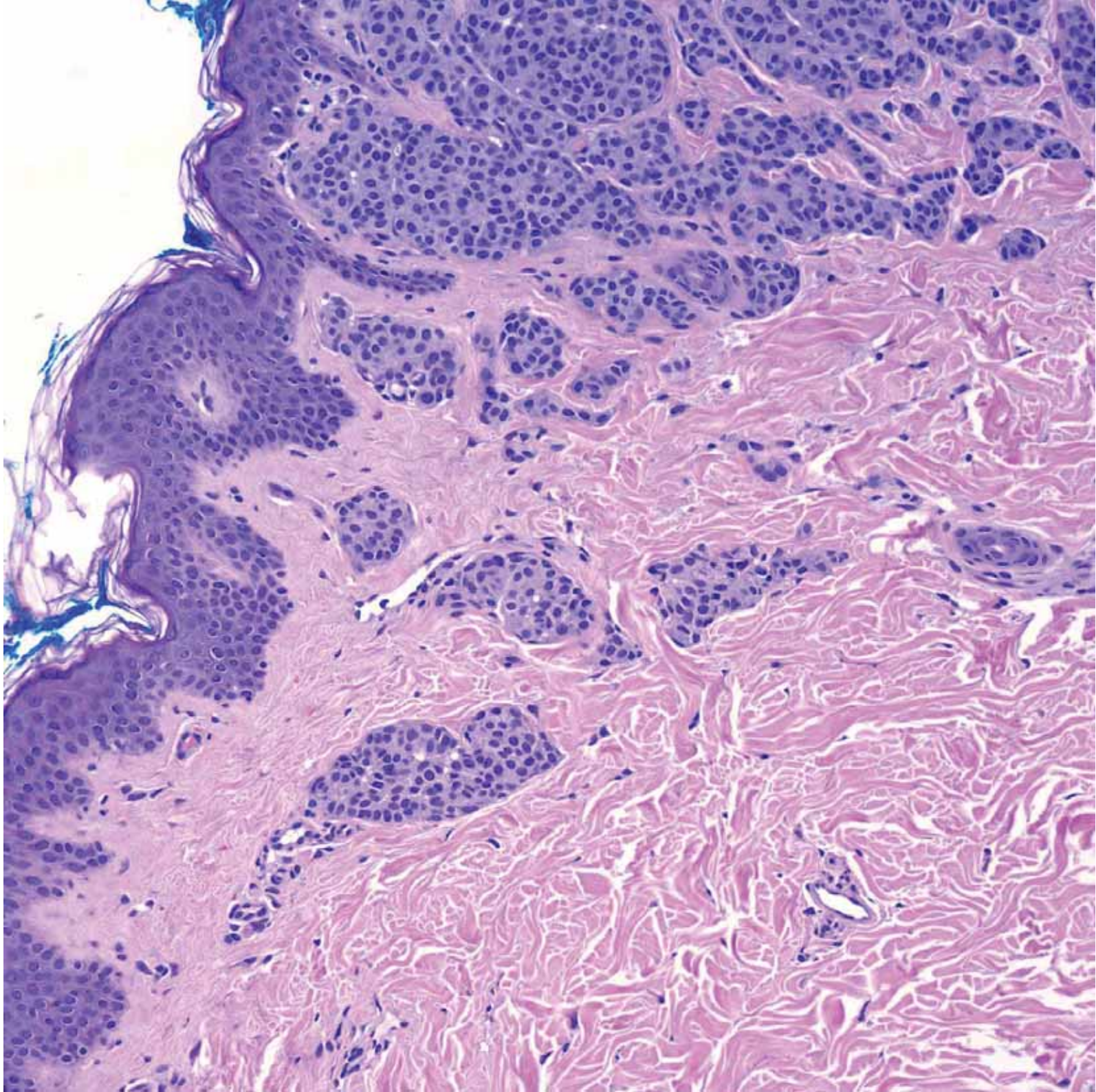


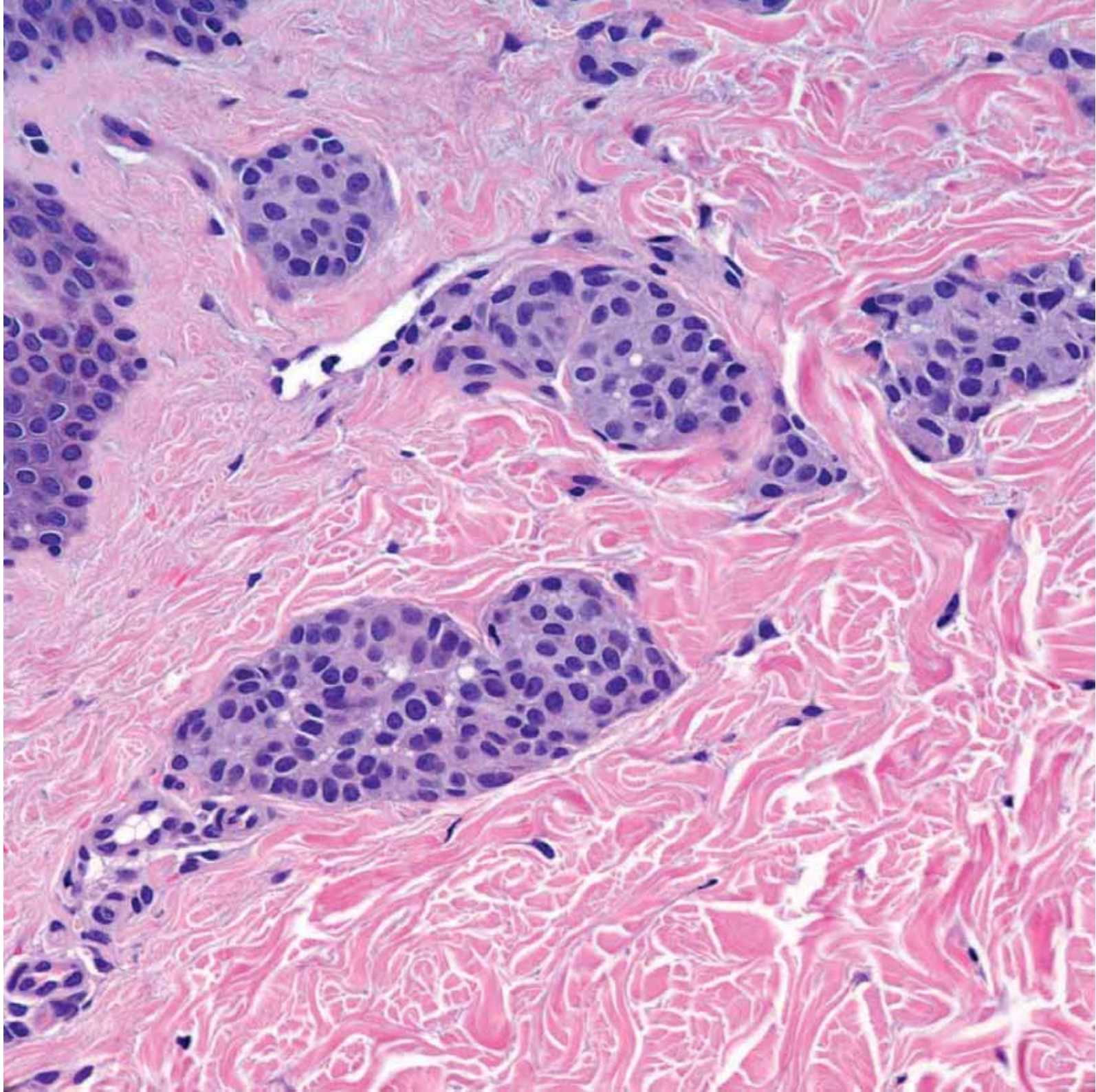




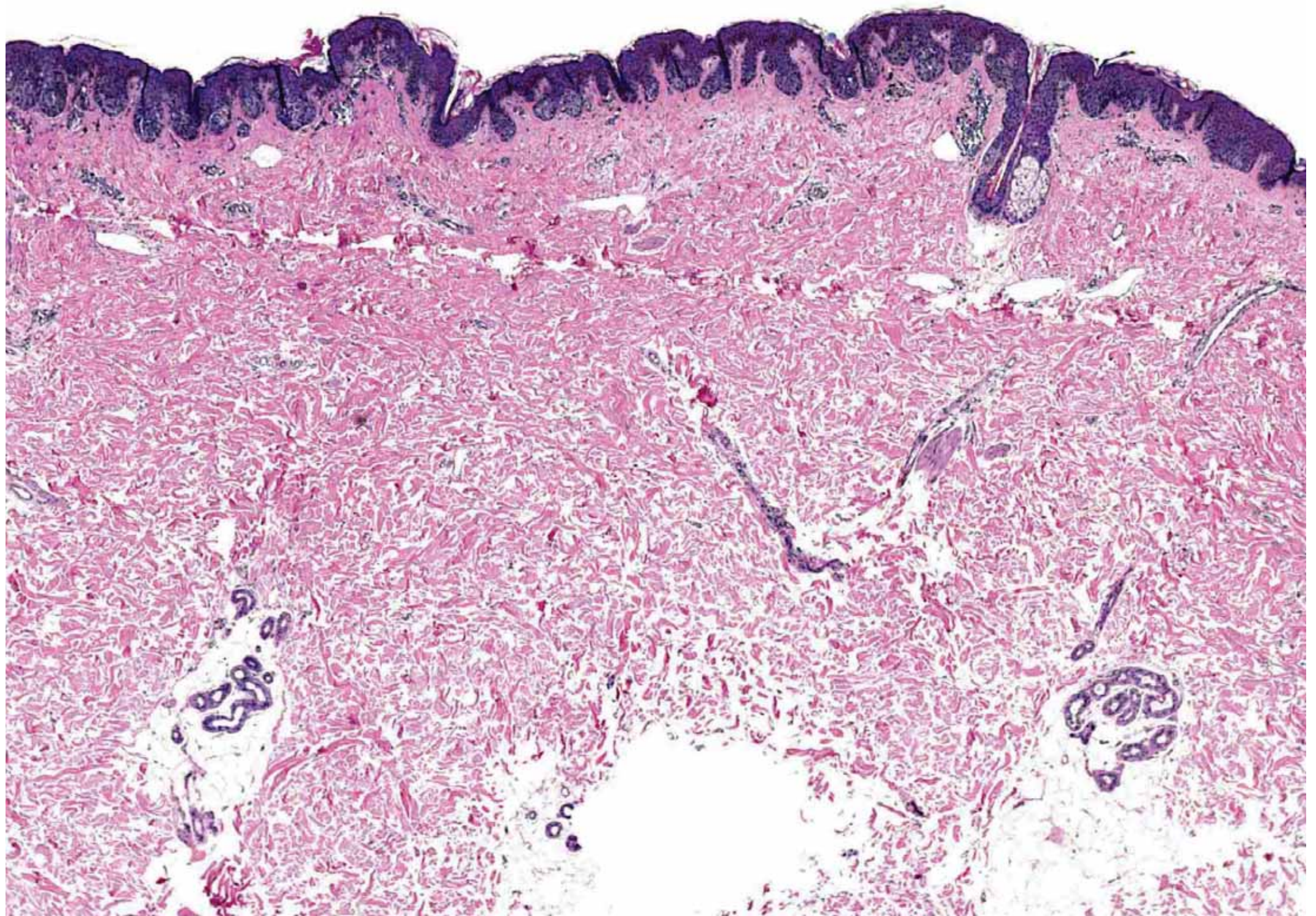


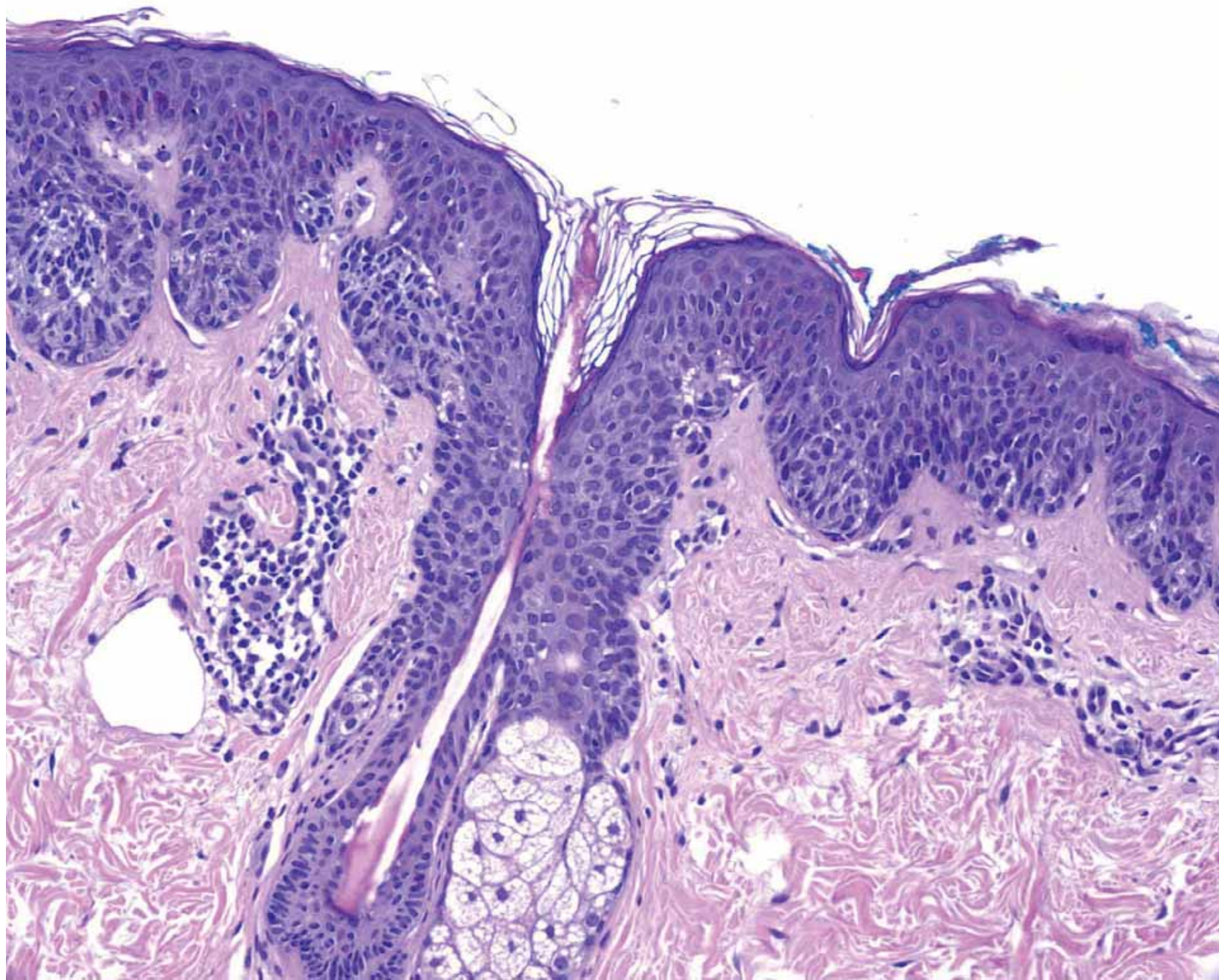


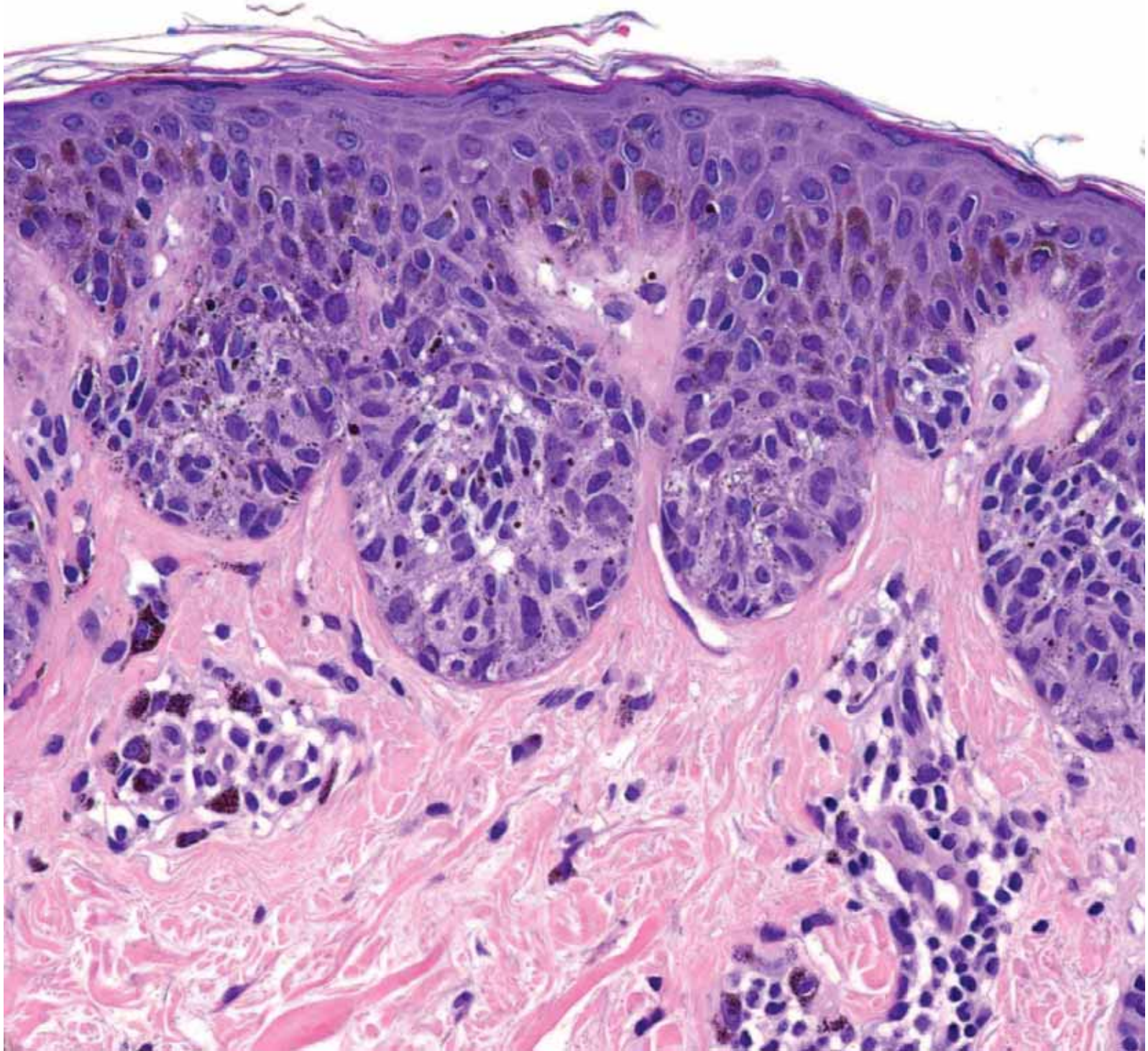


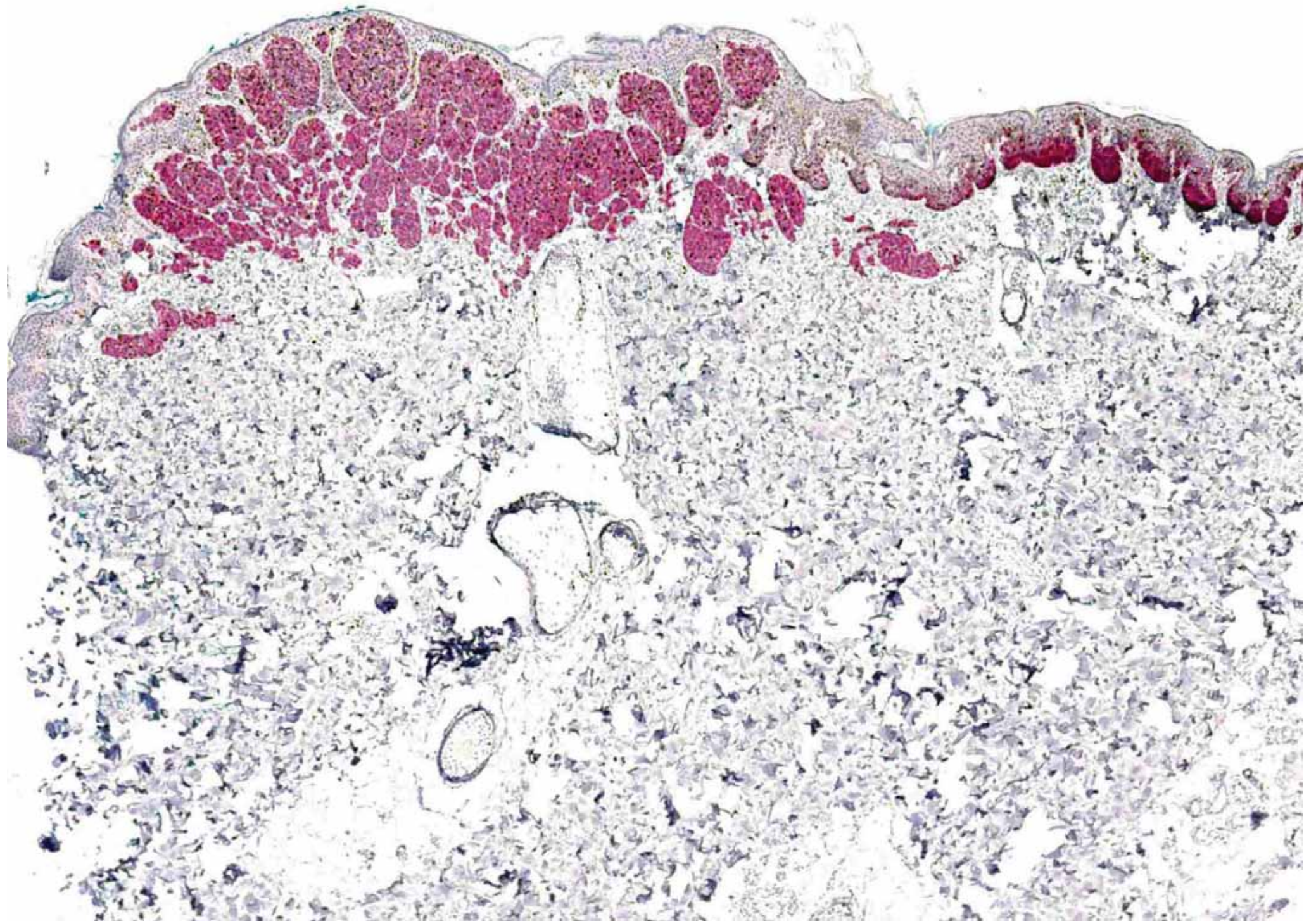


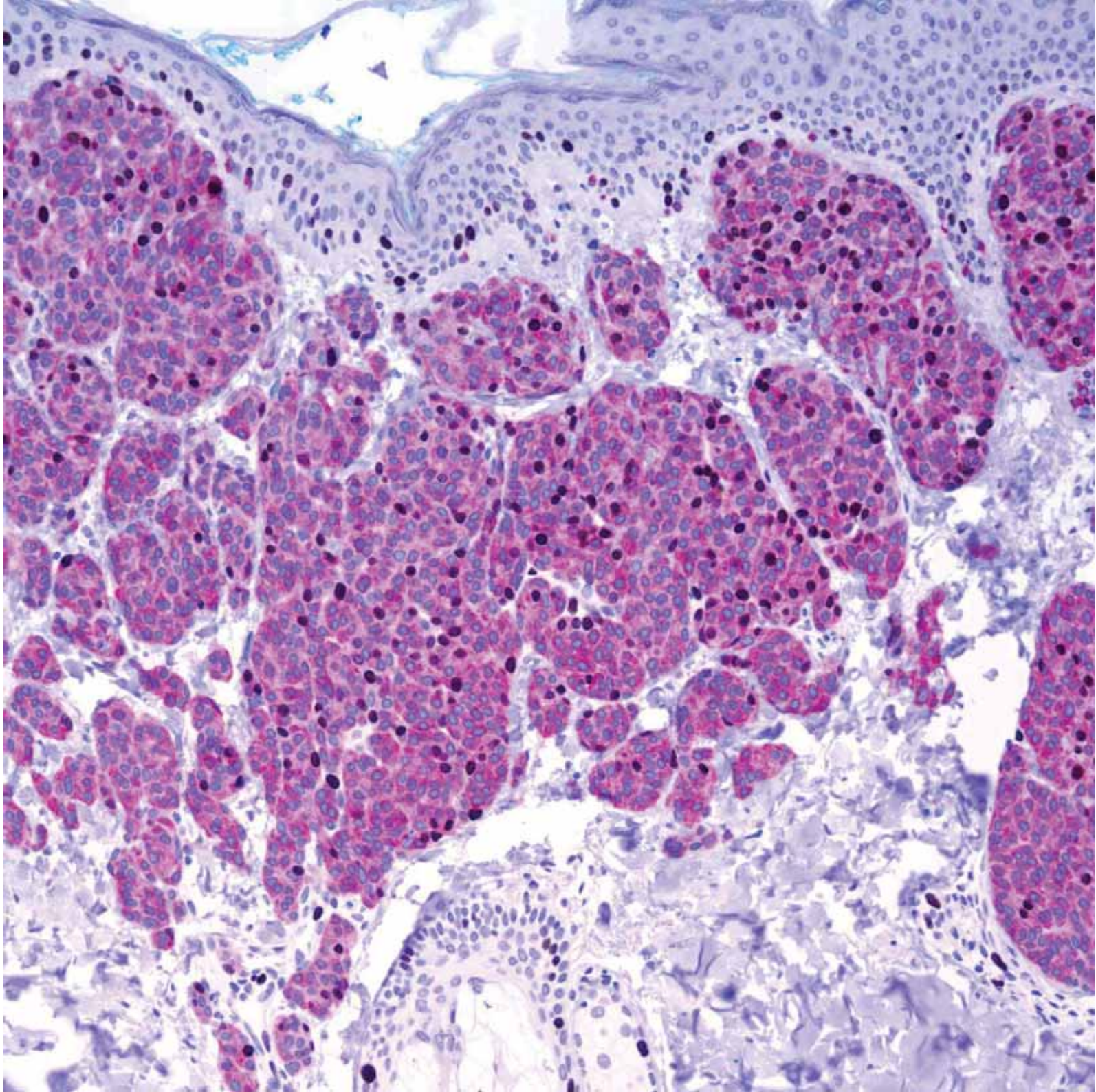
Failure to disperse or lose cytoplasm can be a clue to the diagnosis of nevoid melanoma



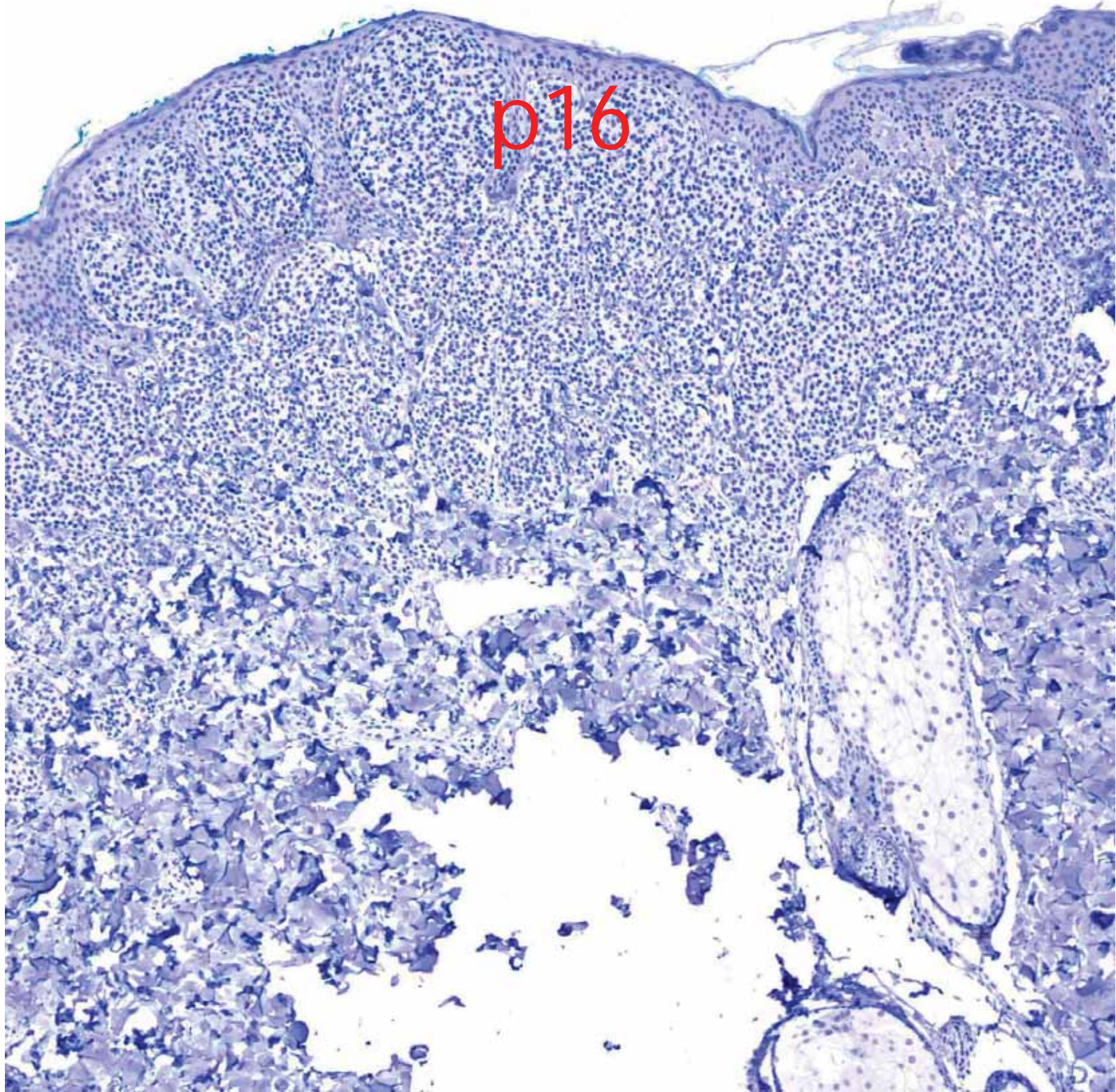


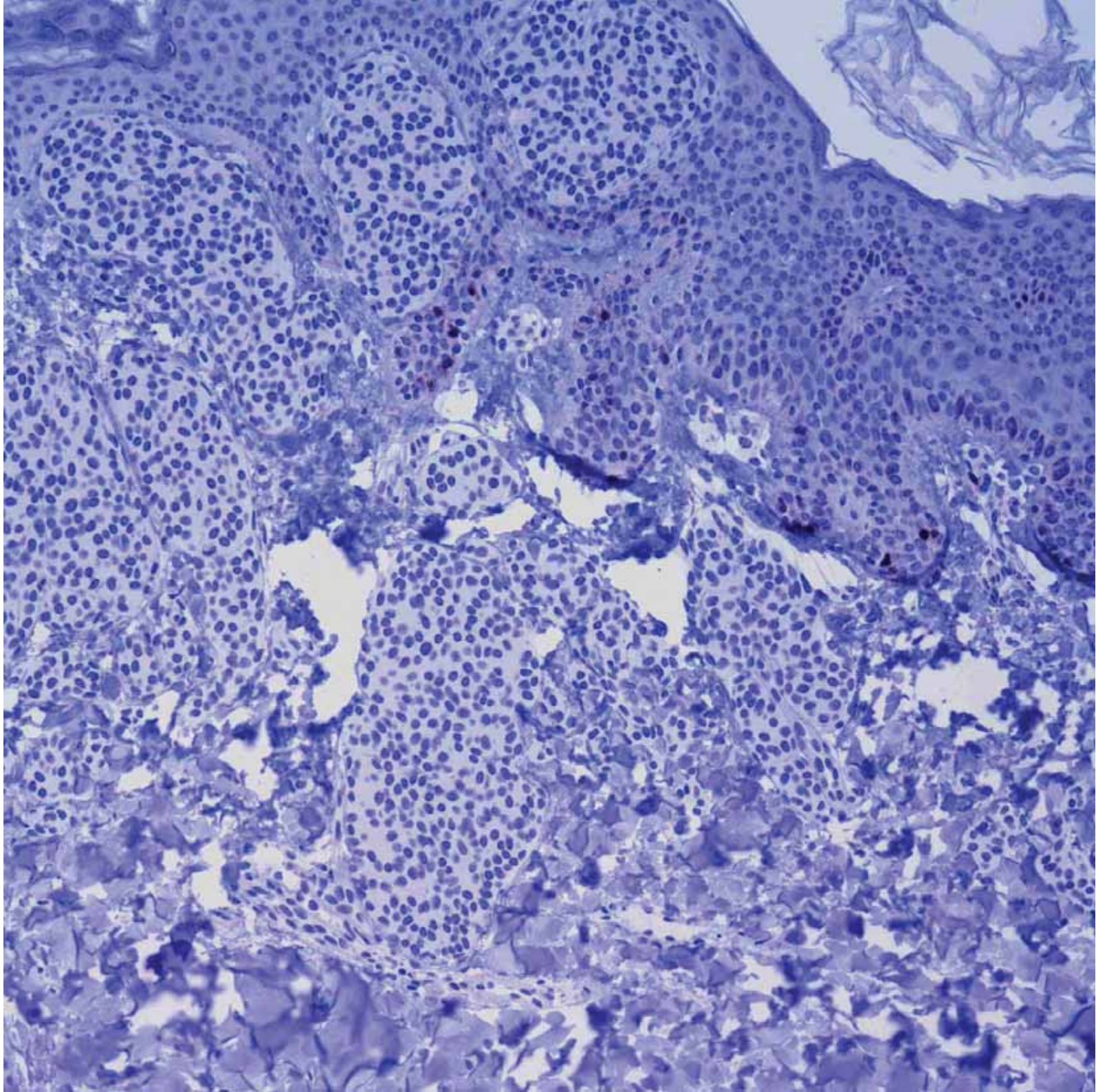


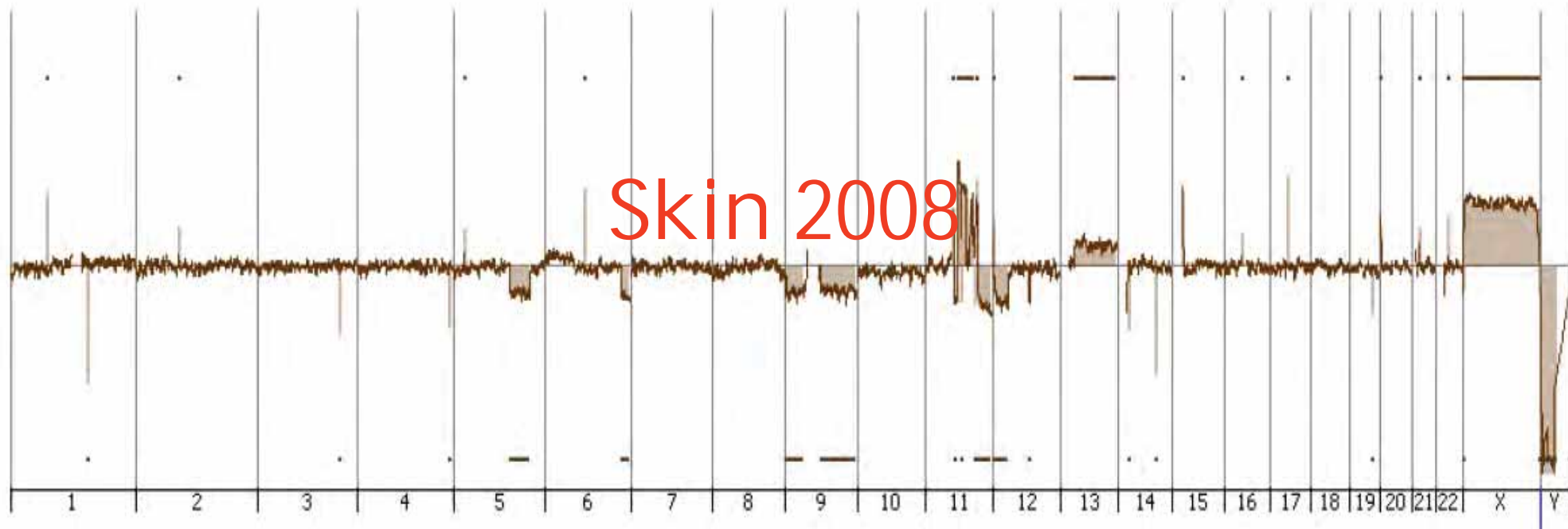




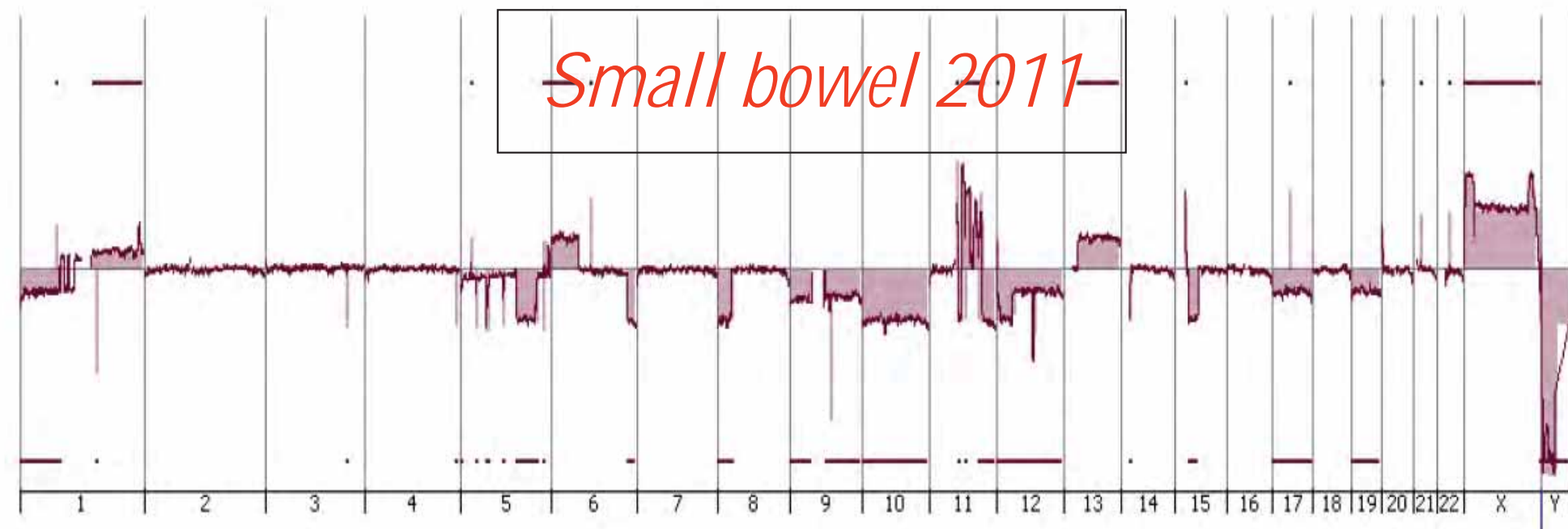
p16







Skin 2008



*Small bowel 2011*

# Molecular fingerprinting

- Copy number changes
- Mutational analysis
  - Simple sequencing
  - High throughput sequencing



# Congenital nevus-like melanoma

- Proposed definition: A melanoma with pattern and cytology resembling that of a congenital nevus, superficial or superficial and deep
- Is this worth describing as a variant of nevoid melanoma?

Sclectosing melanocytic proliferations in the  
dysplastic nevus- nevoid melanoma spectrum

## PARENCHYMAL-STROMAL INTERACTIONS IN NEOPLASIA

Theoretical considerations and observations in melanocytic neoplasia

WALLACE H. CLARK, JR., MARGARET A. TUCKER and ALISA M. GOLDSTEIN

---

The paper briefly reviews the reciprocal and continuous reciprocal interactions between epithelia, mesenchyme, and extracellular matrix in the development and maintenance of organismal form in multicellular organisms in the animal kingdom and describes the progressive changes in parenchymal-stromal interactions in melanocytic neoplastic development and progression. In addition to the parenchymal stromal form in non-lesional skin seven different and unique stromal patterns are described. These have been termed: 1) The stroma (diff-regress) of programmed differentiation leading to lesional regression characteristic of common nevi; 2) Concentric eosinophilic fibroplasia (cef), the hallmark of precursor nevi (dyplastic nevi) with and without melanocytic nuclear atypia; 3) Fibroplasia with angiogenesis (fa) commonly seen in superficial spreading melanoma without metastatic competence (SSM); 4) Lamellar fibroplasia (lf) seen in precursor nevi and melanomas with and without metastatic competence; 5) Diffuse fibroplasia with angiogenesis (dfa), 6) Narrow, uniform concentric eosinophilic fibroplasia (nucef), 7) No parenchymal-stromal interaction (nopsi); the last three being seen in the heterogeneous stroma of melanomas of the superficial spreading type with metastatic competence. The changes in neoplastic stroma proceed in concert with the changes in the parenchyma characteristic of melanocytic tumor progression.

---

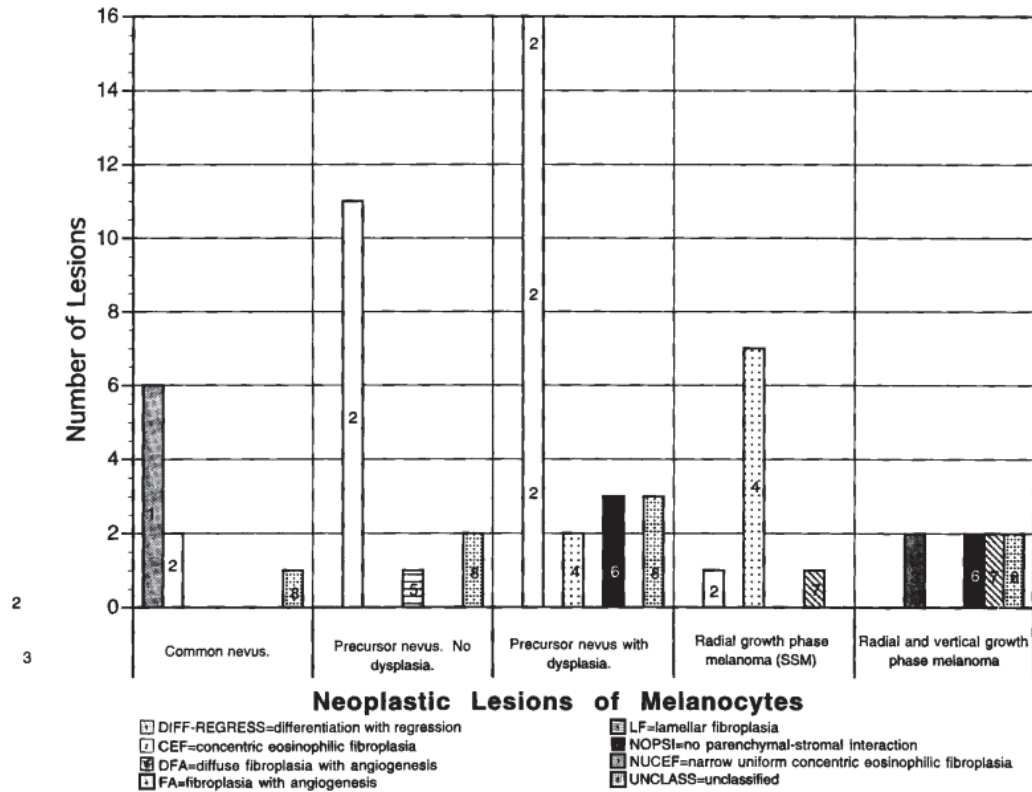
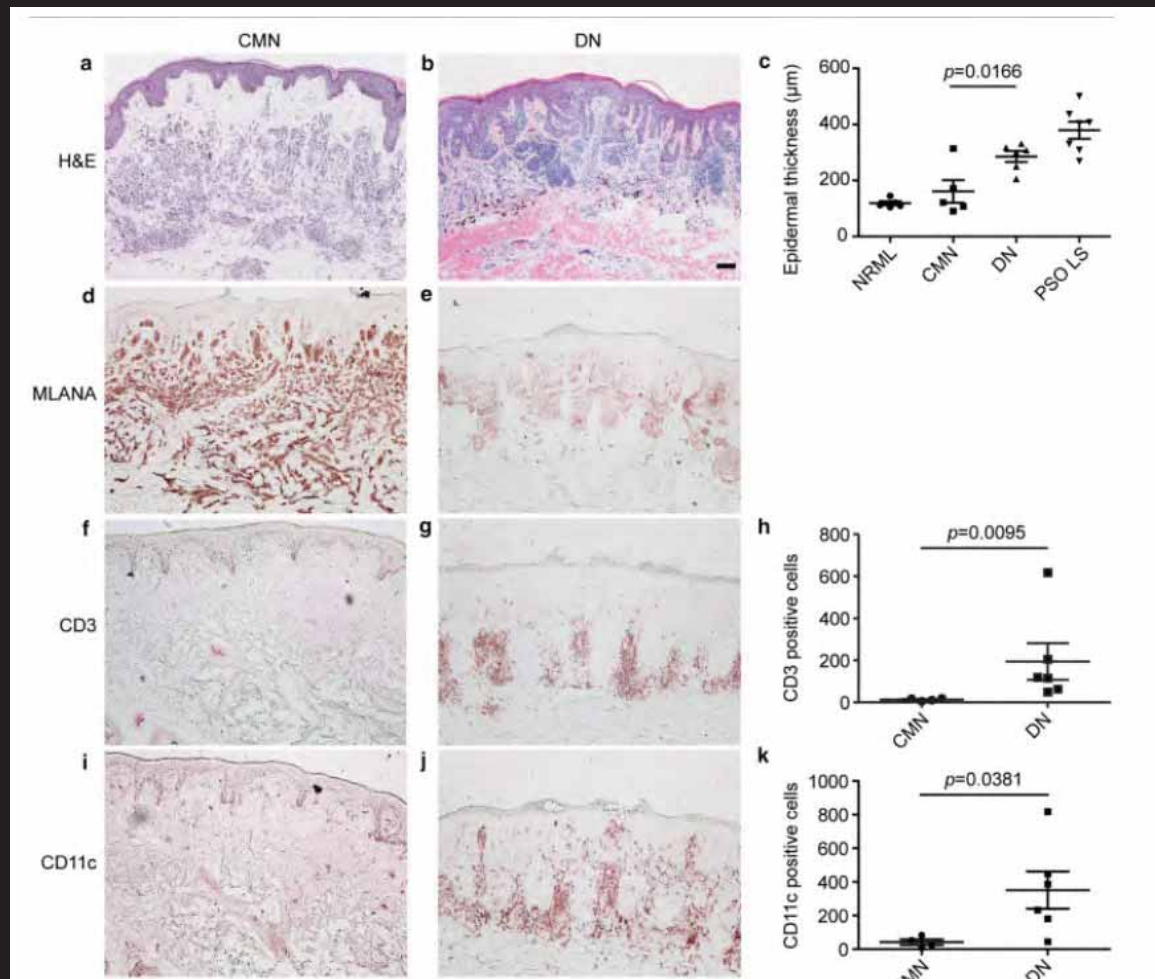


Fig. 1. Stromal patterns in melanocytic neoplasia.



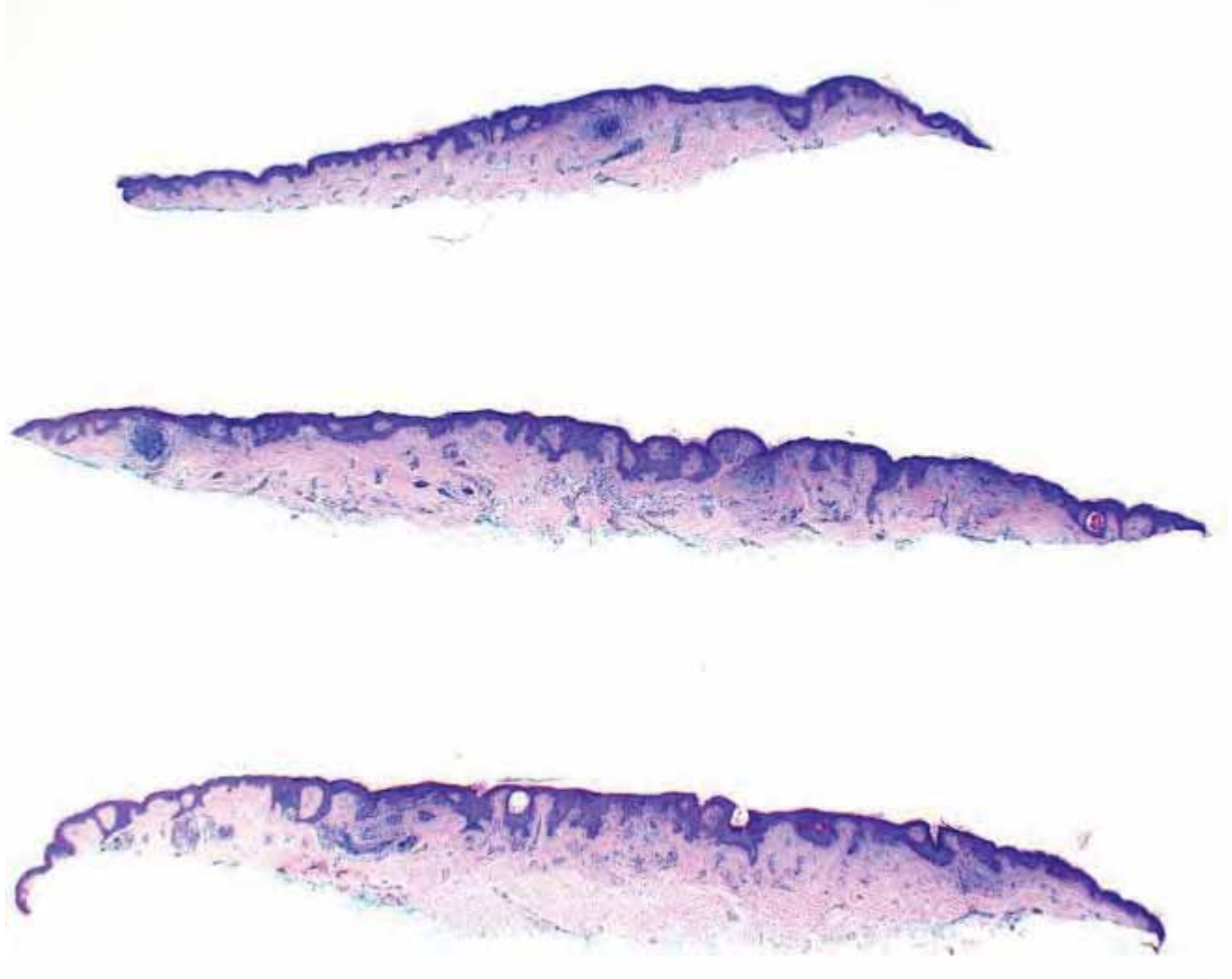
## Discrimination of Dysplastic Nevi from Common Melanocytic Nevi by Cellular and Molecular Criteria

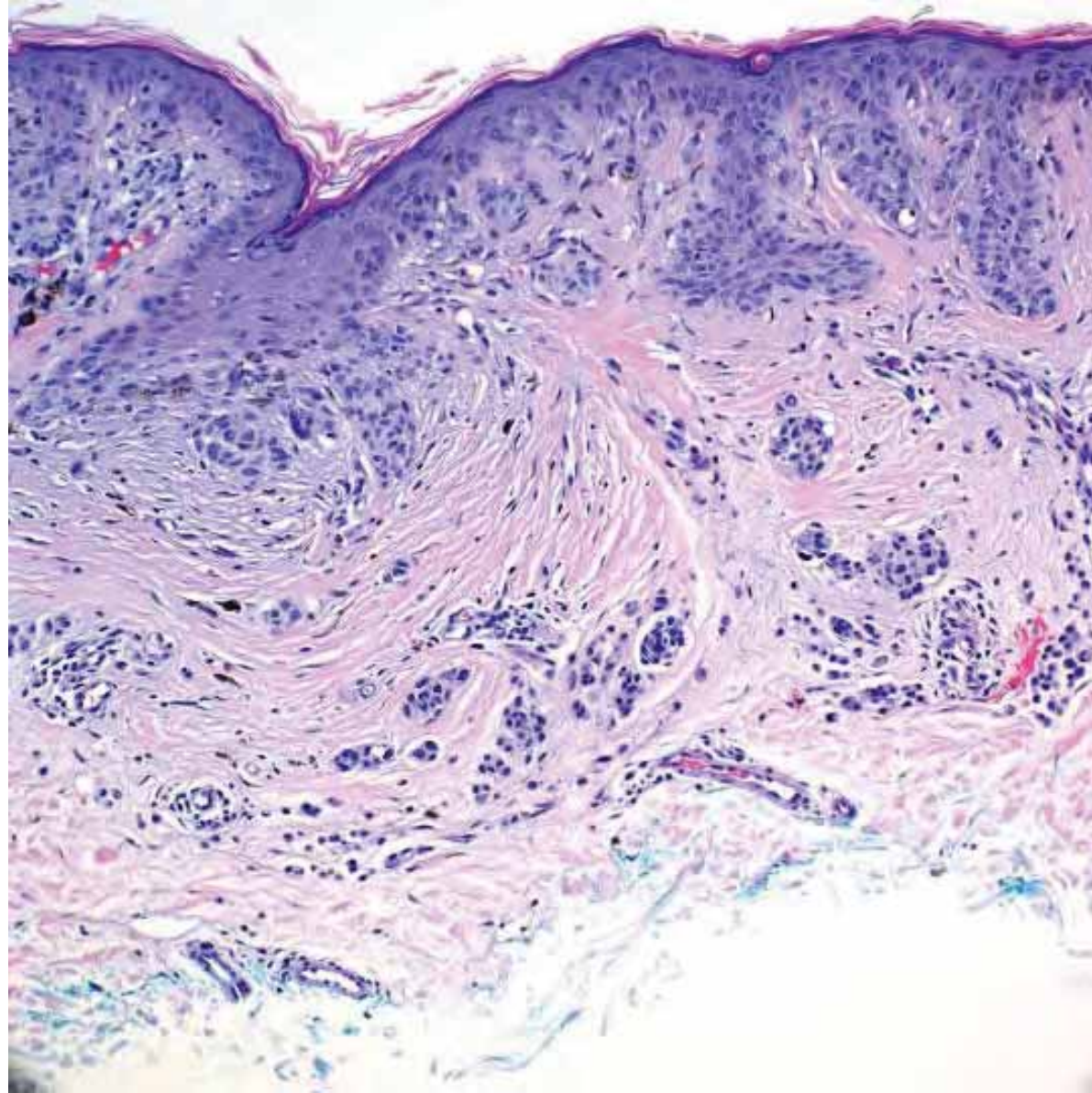


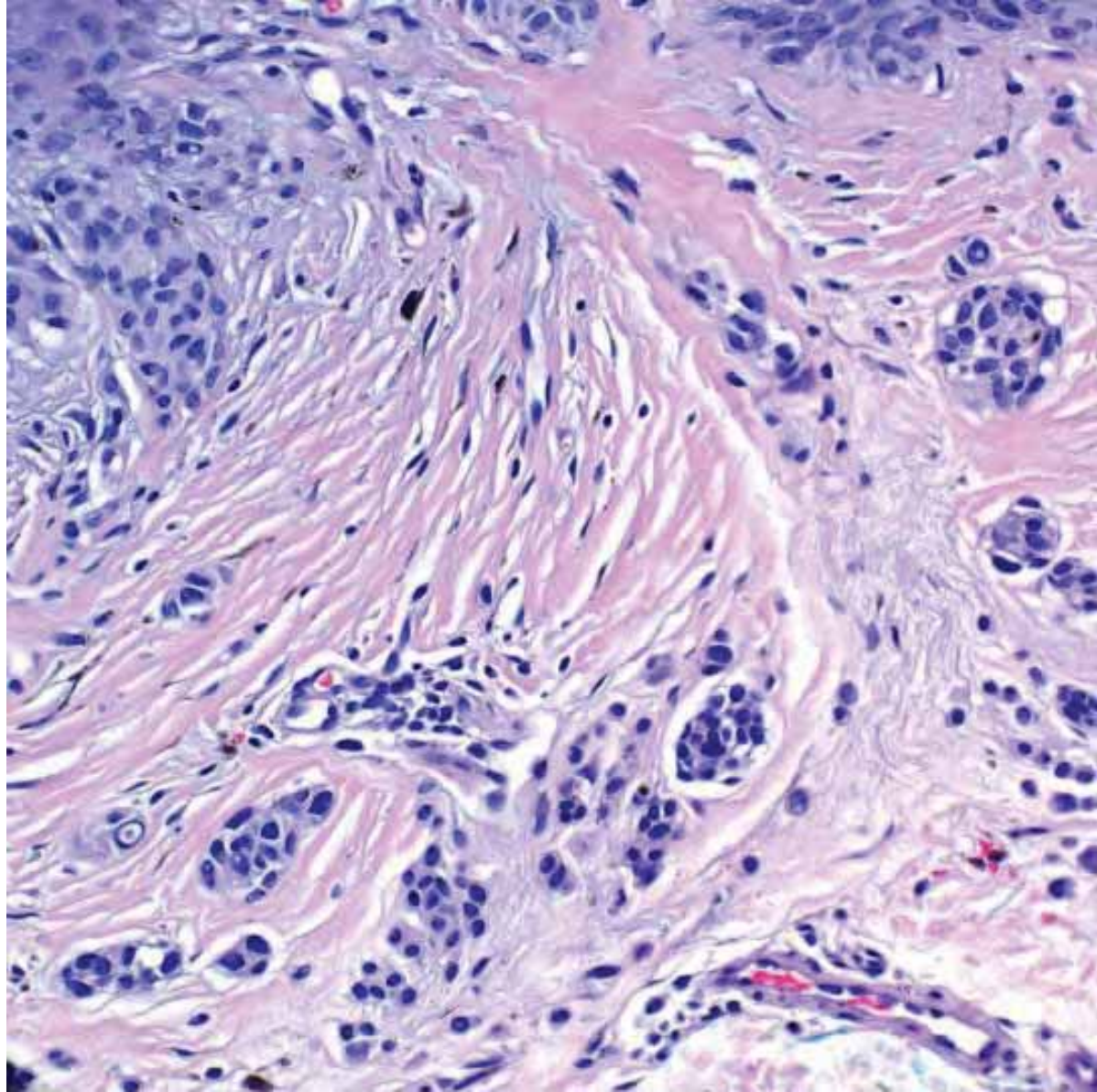
Hiroshi Mitsui<sup>1</sup>, Felix Kiecker<sup>2</sup>, Avner Shemer<sup>1</sup>, Maria Vittoria Cannizzaro<sup>1,5</sup>, Claire Q.F. Wang<sup>3</sup>, Nicholas Gulati<sup>1</sup>, Hanako Ohmatsu<sup>1</sup>, Kejal R. Shah<sup>3</sup>, Patricia Gilleaudeau<sup>1</sup>, Mary Sullivan-Whalen<sup>1</sup>, Inna Cueto<sup>1</sup>, Neil Scott McNutt<sup>1</sup>, Mayte Suárez-Fariñas<sup>1,6</sup> and James G. Krueger<sup>1</sup>

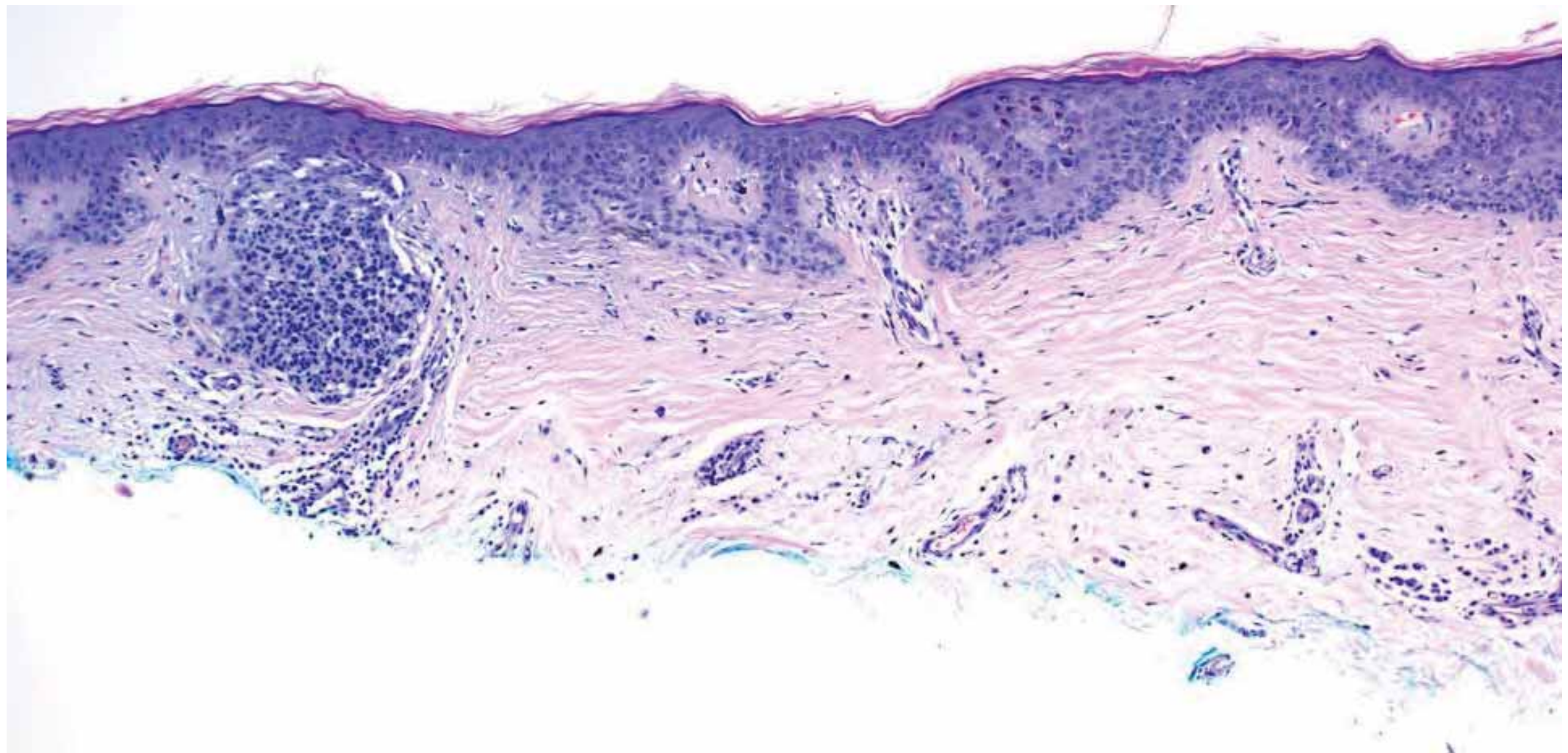
# Clark's (dysplastic) nevus, fibroplasia

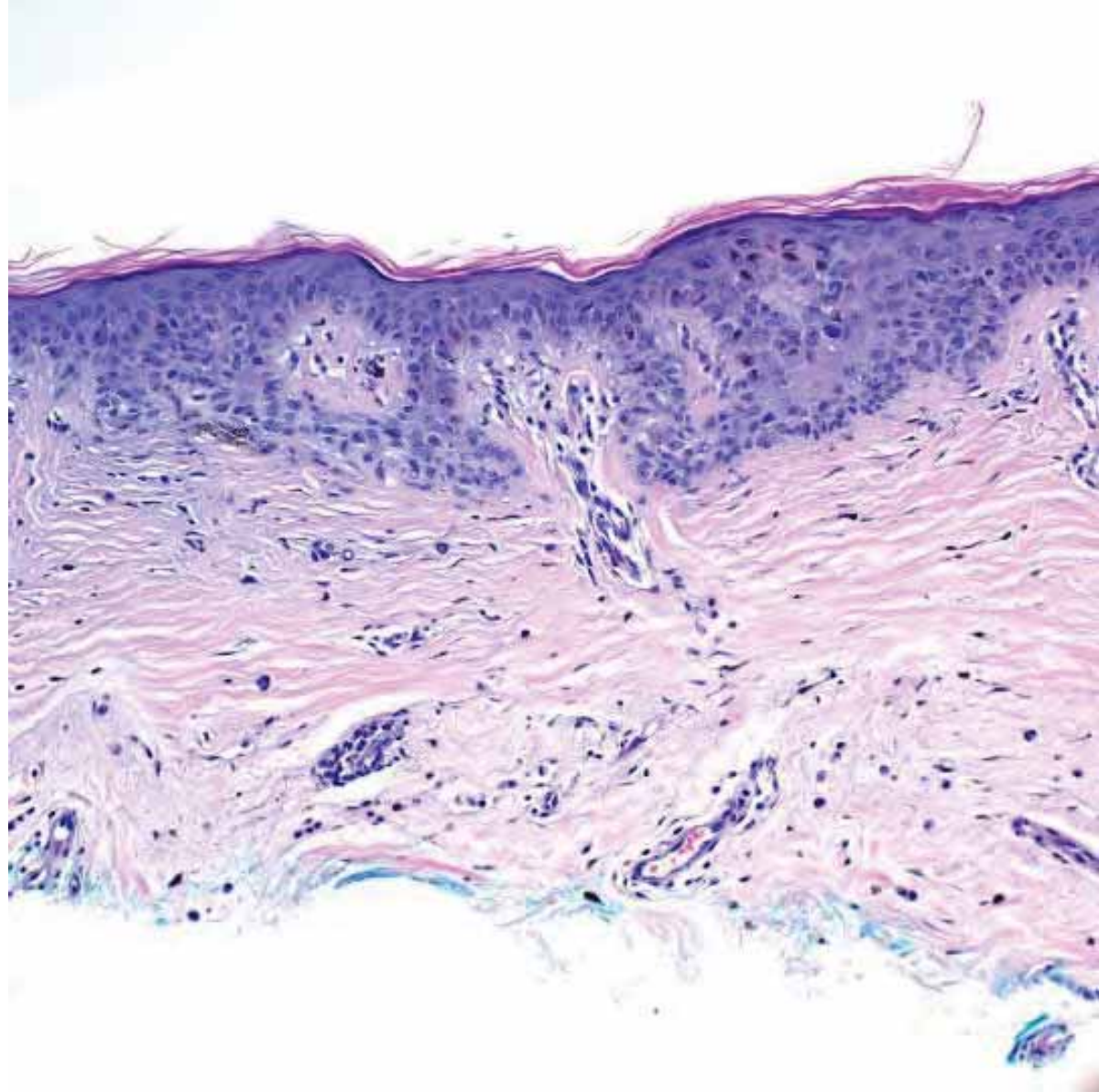
- Lamellar
- Concentric
- ? The same process
- ? Immunological scar (Reed)

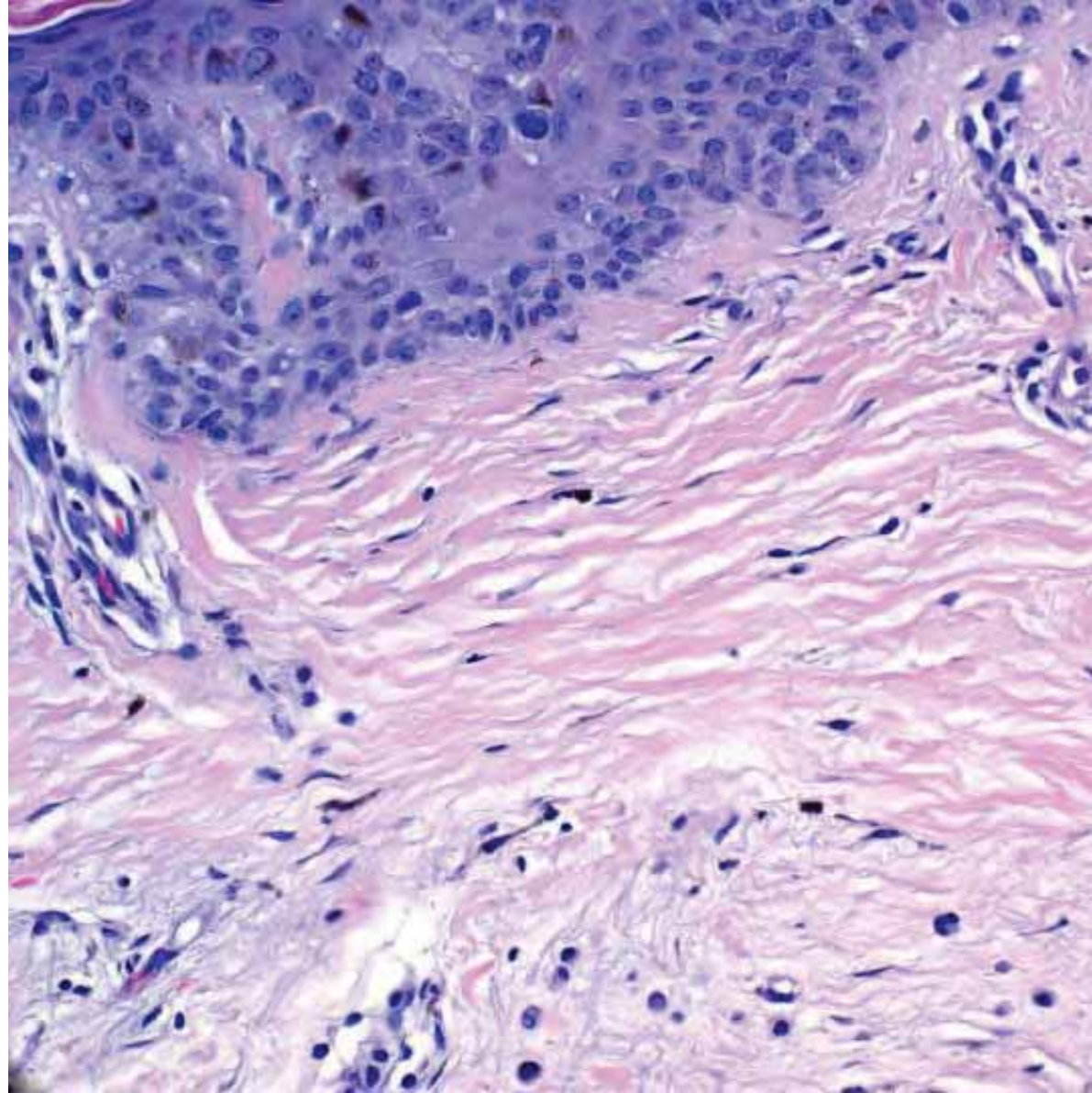


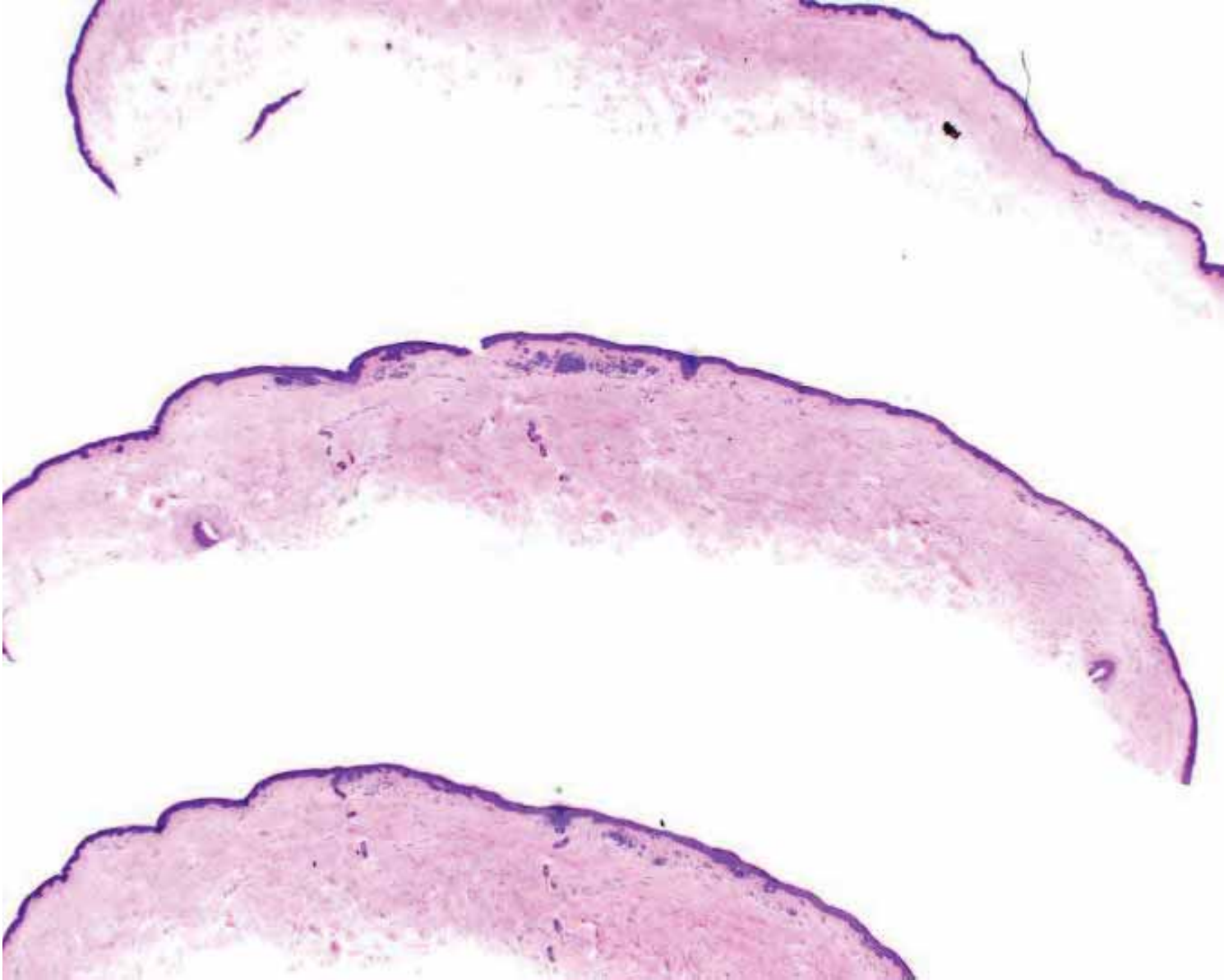


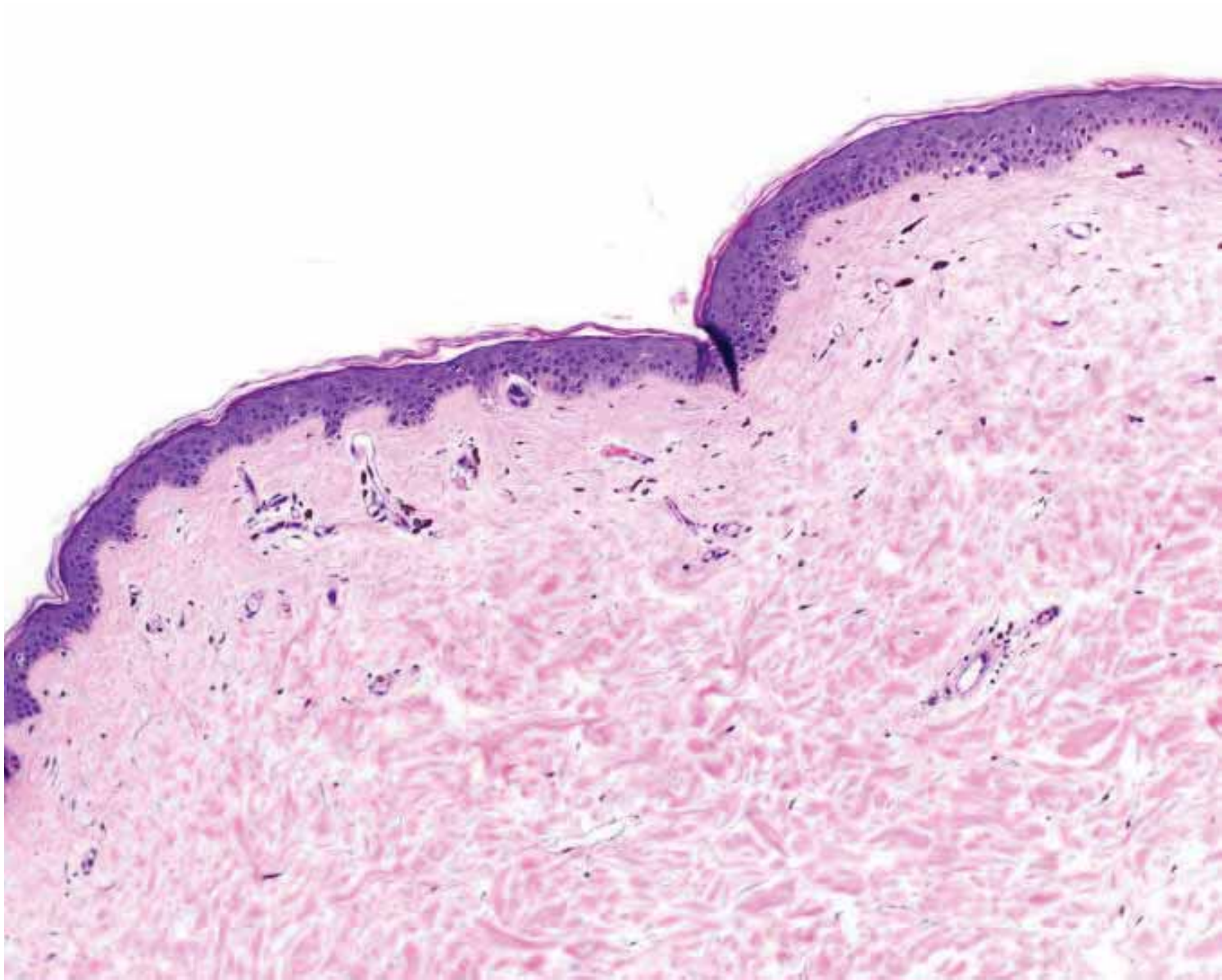


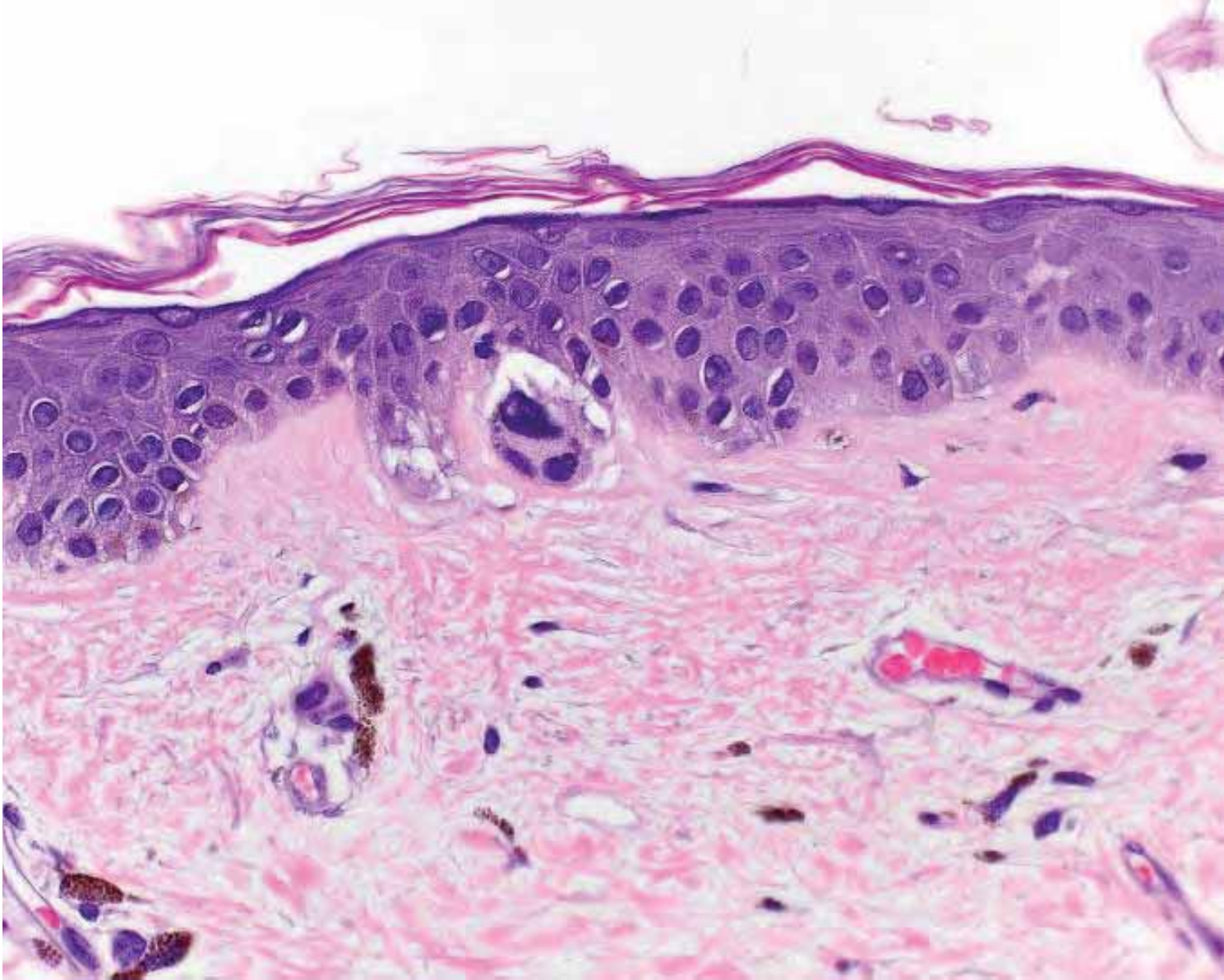


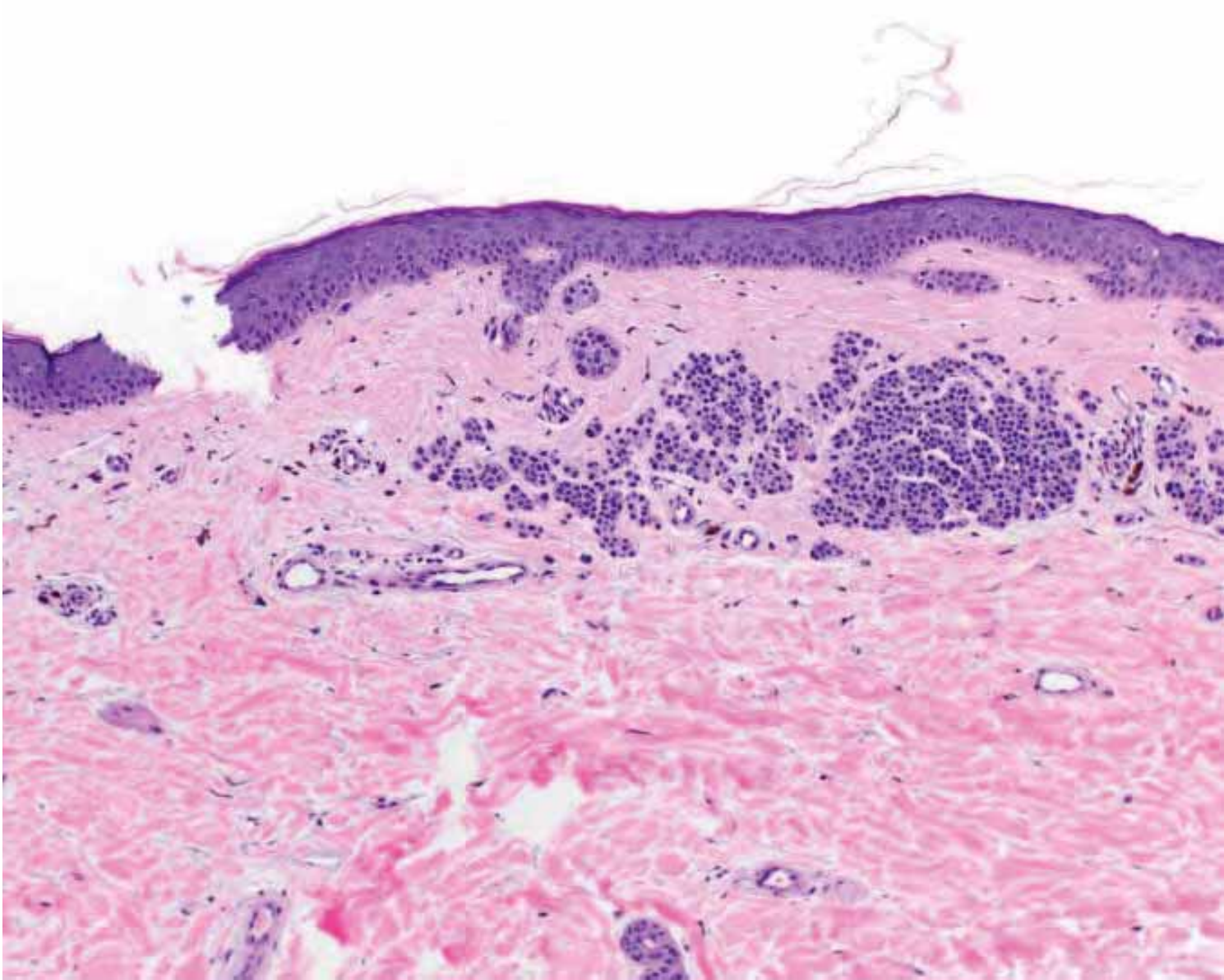


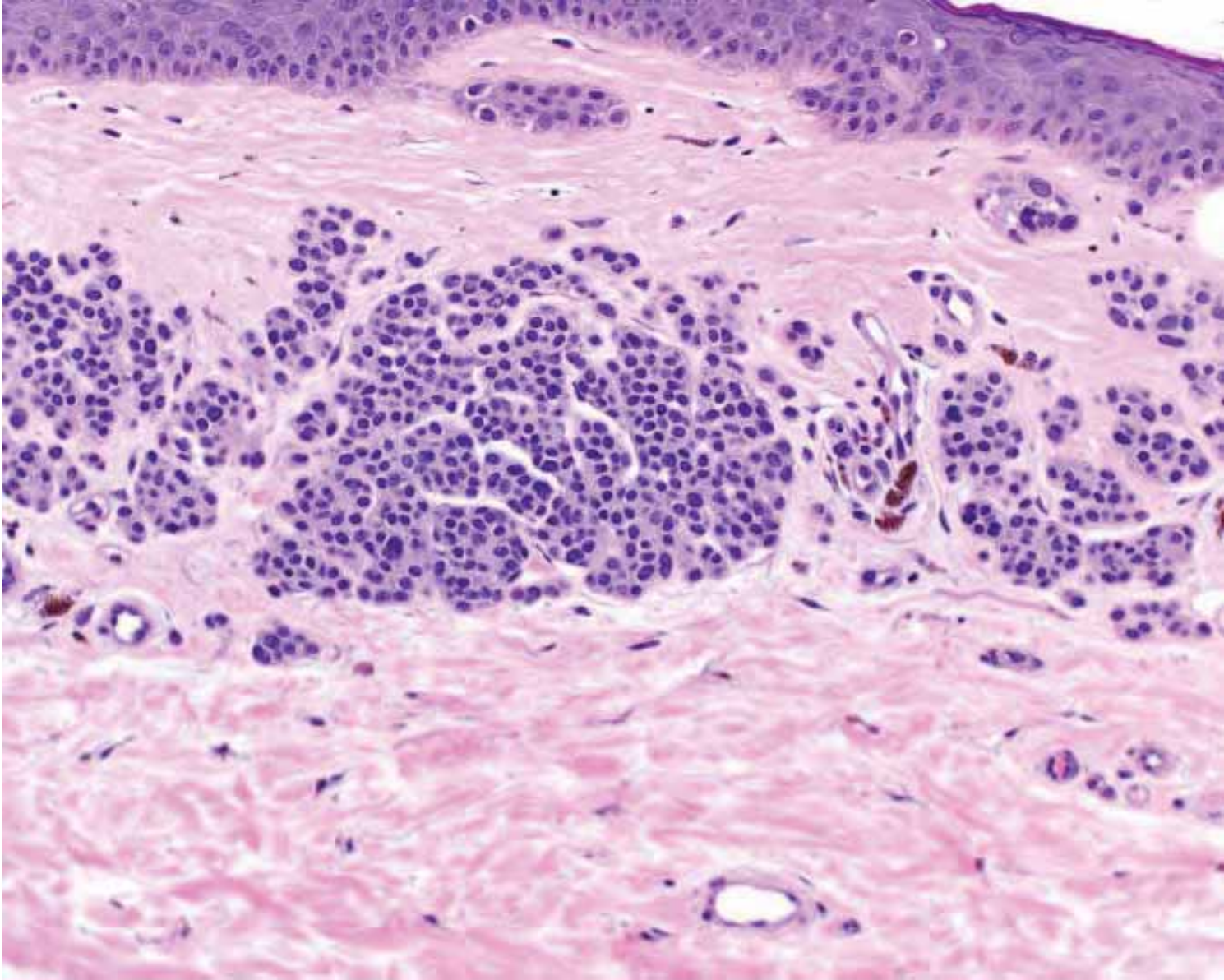


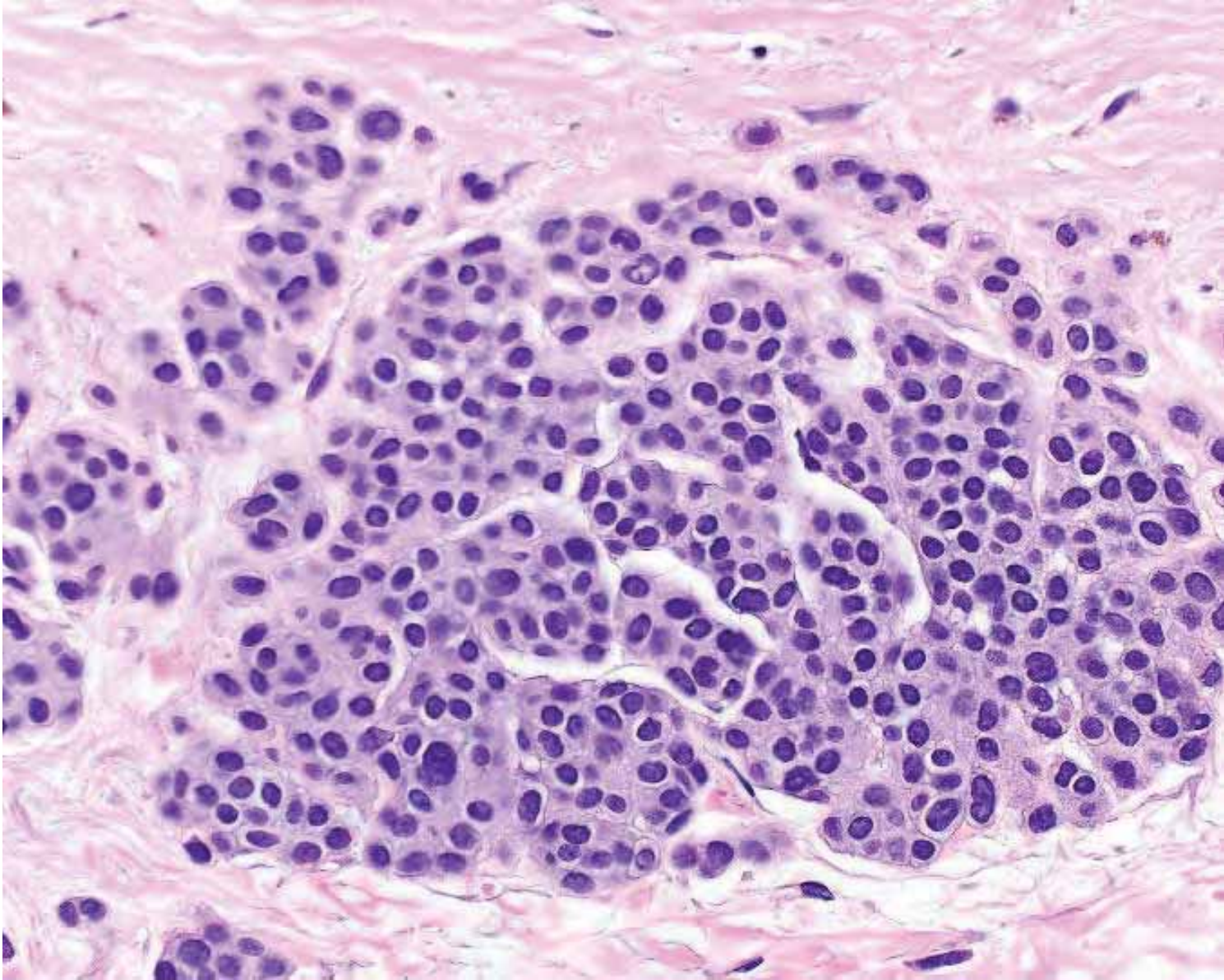


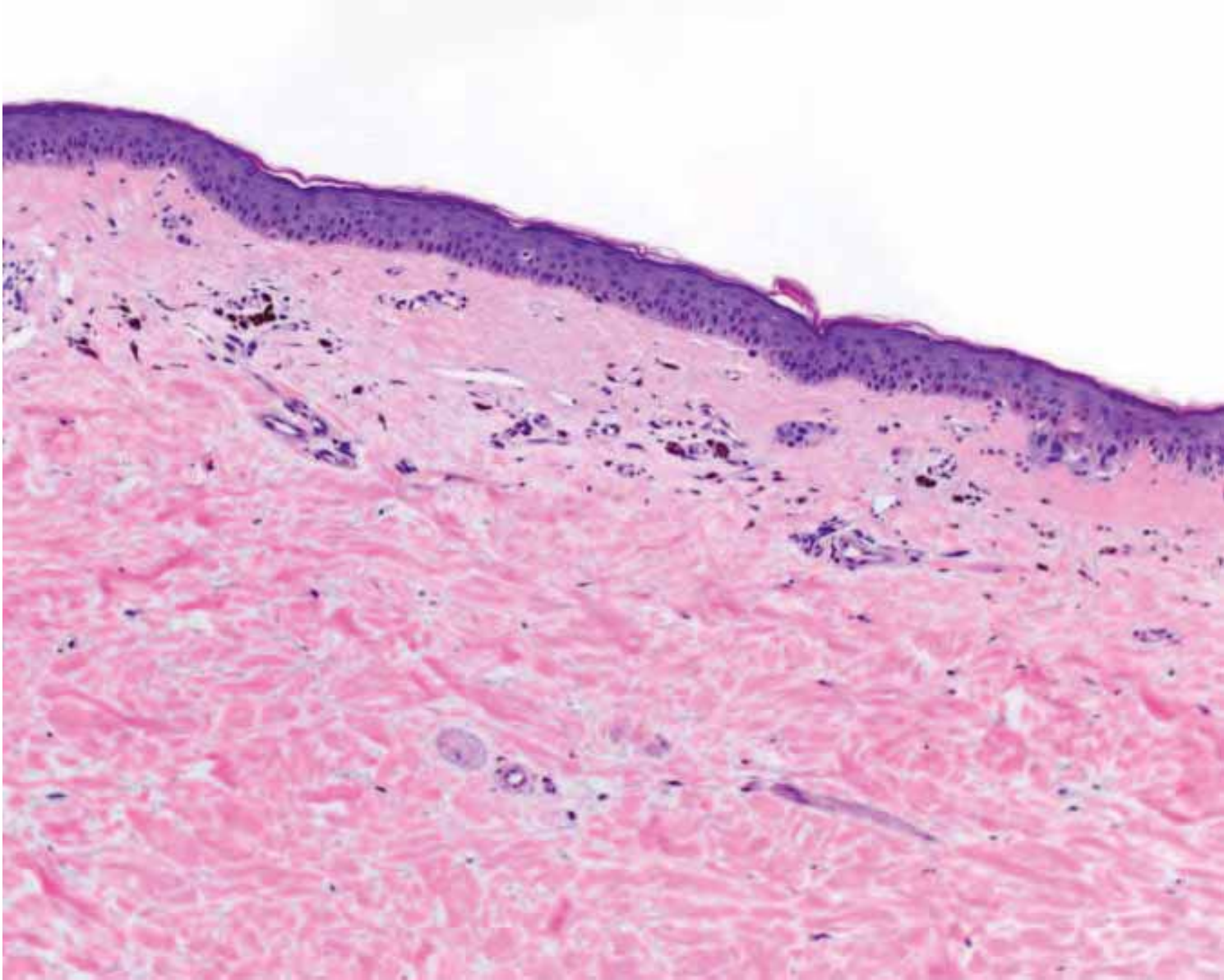


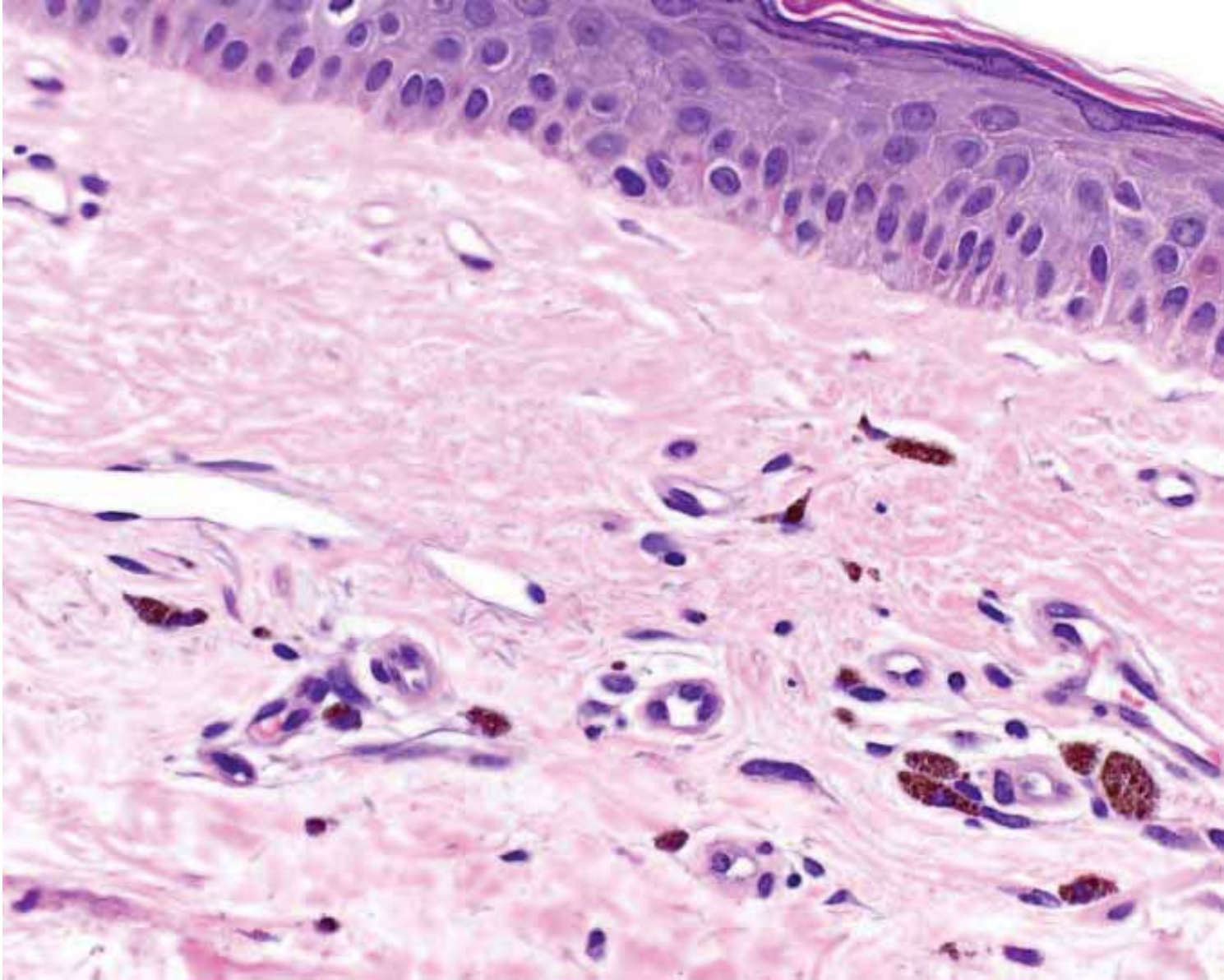


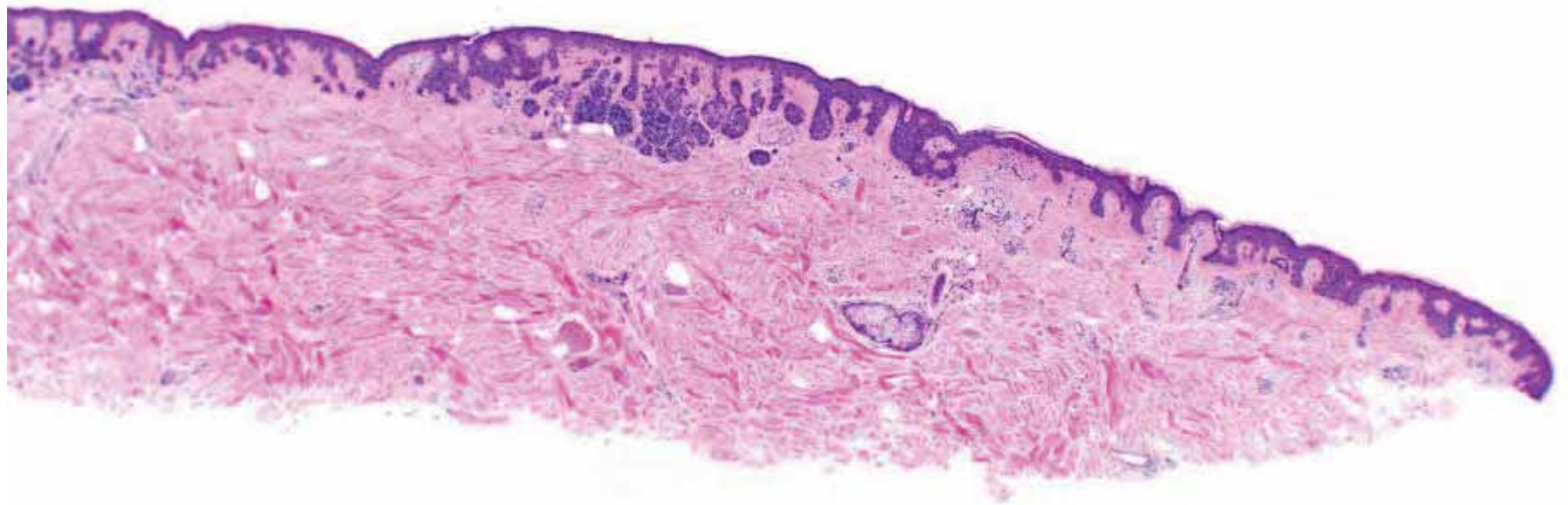


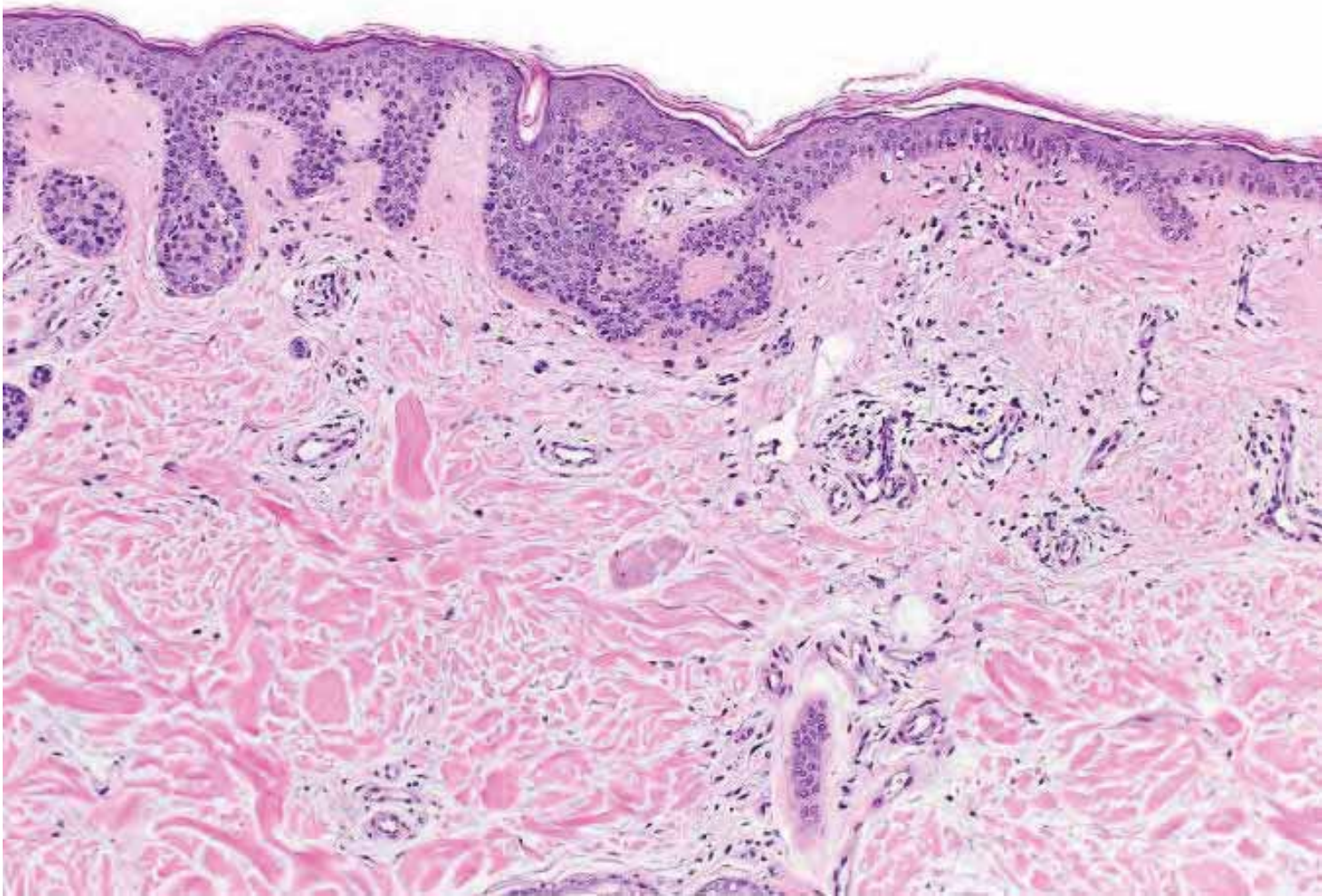


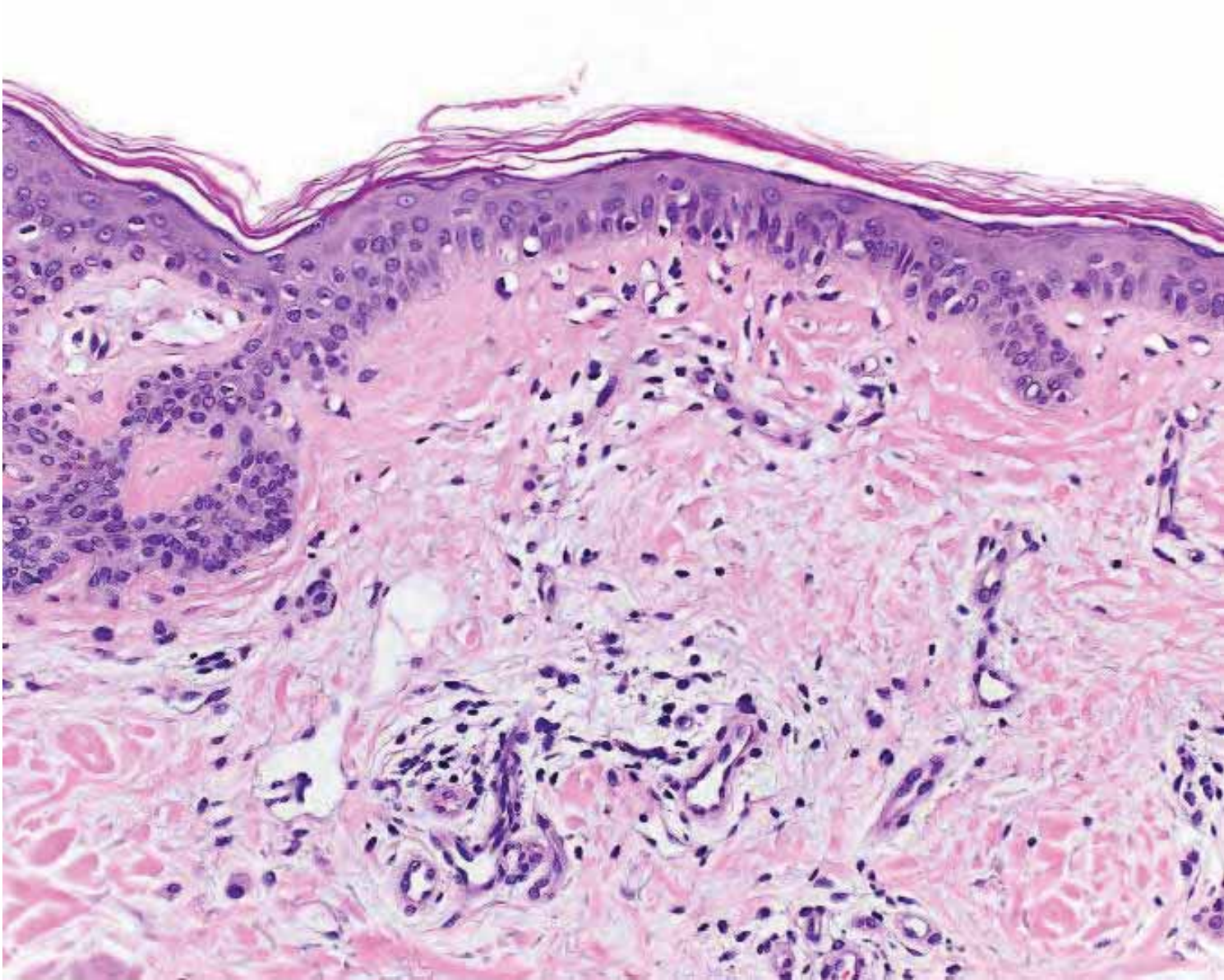


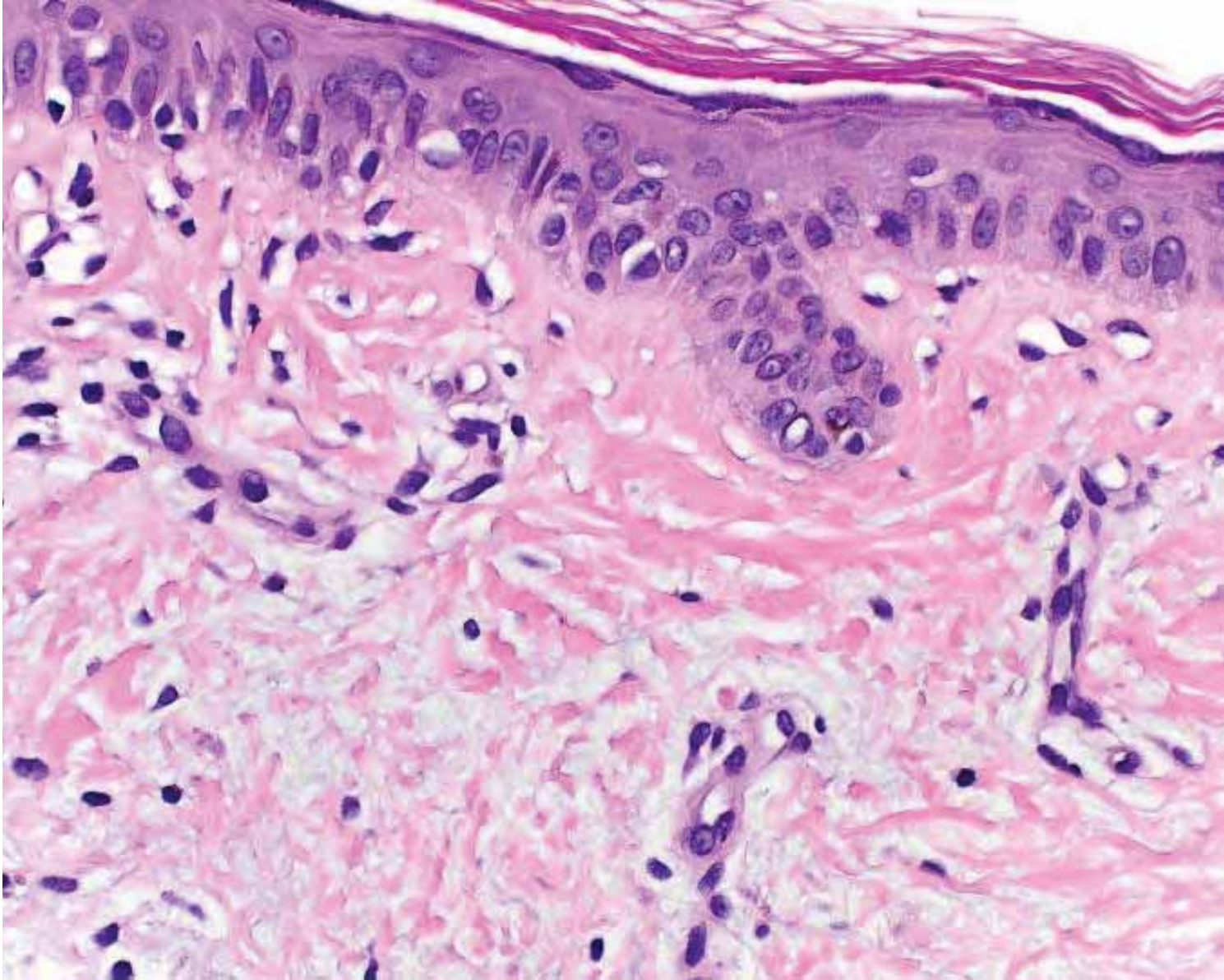


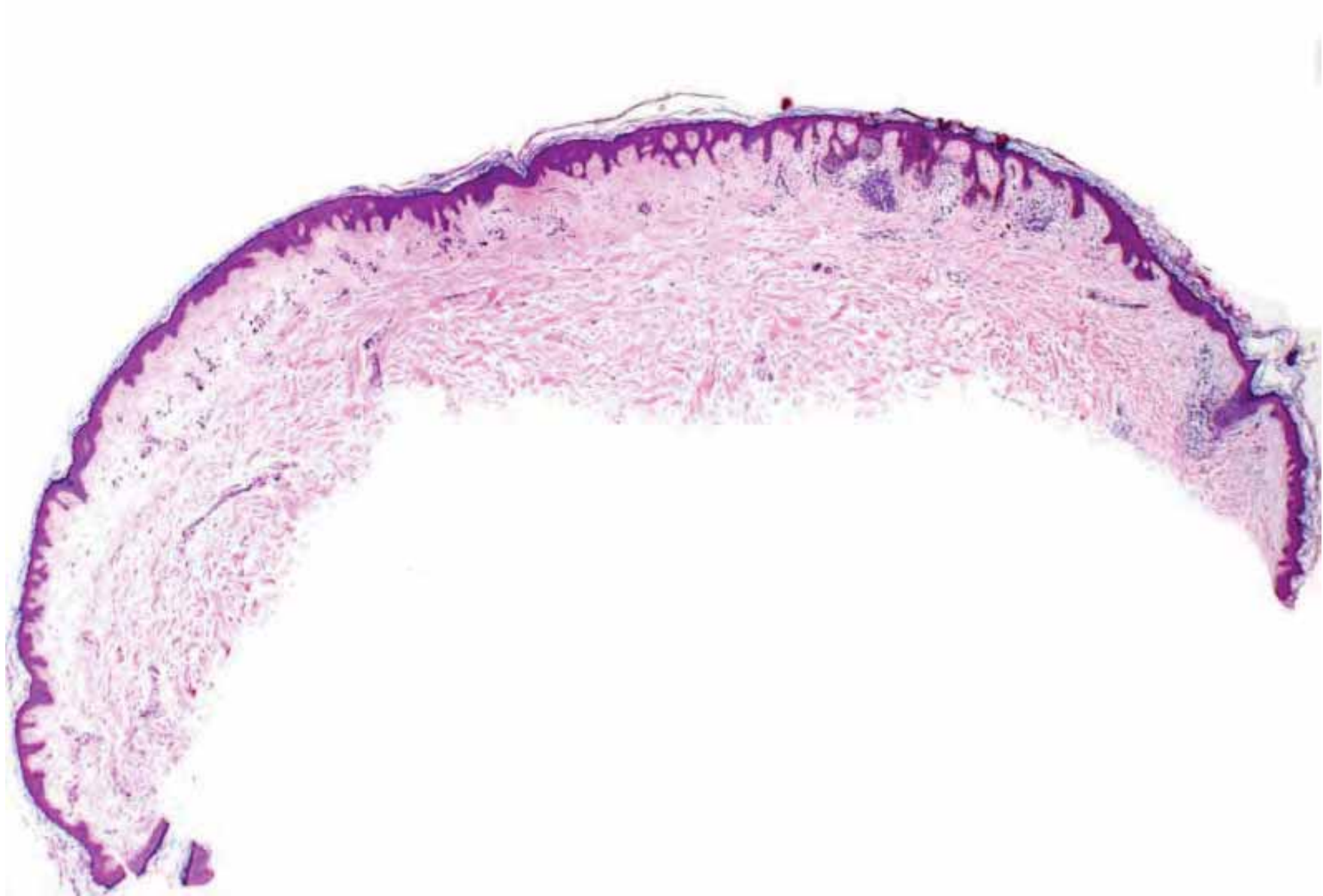


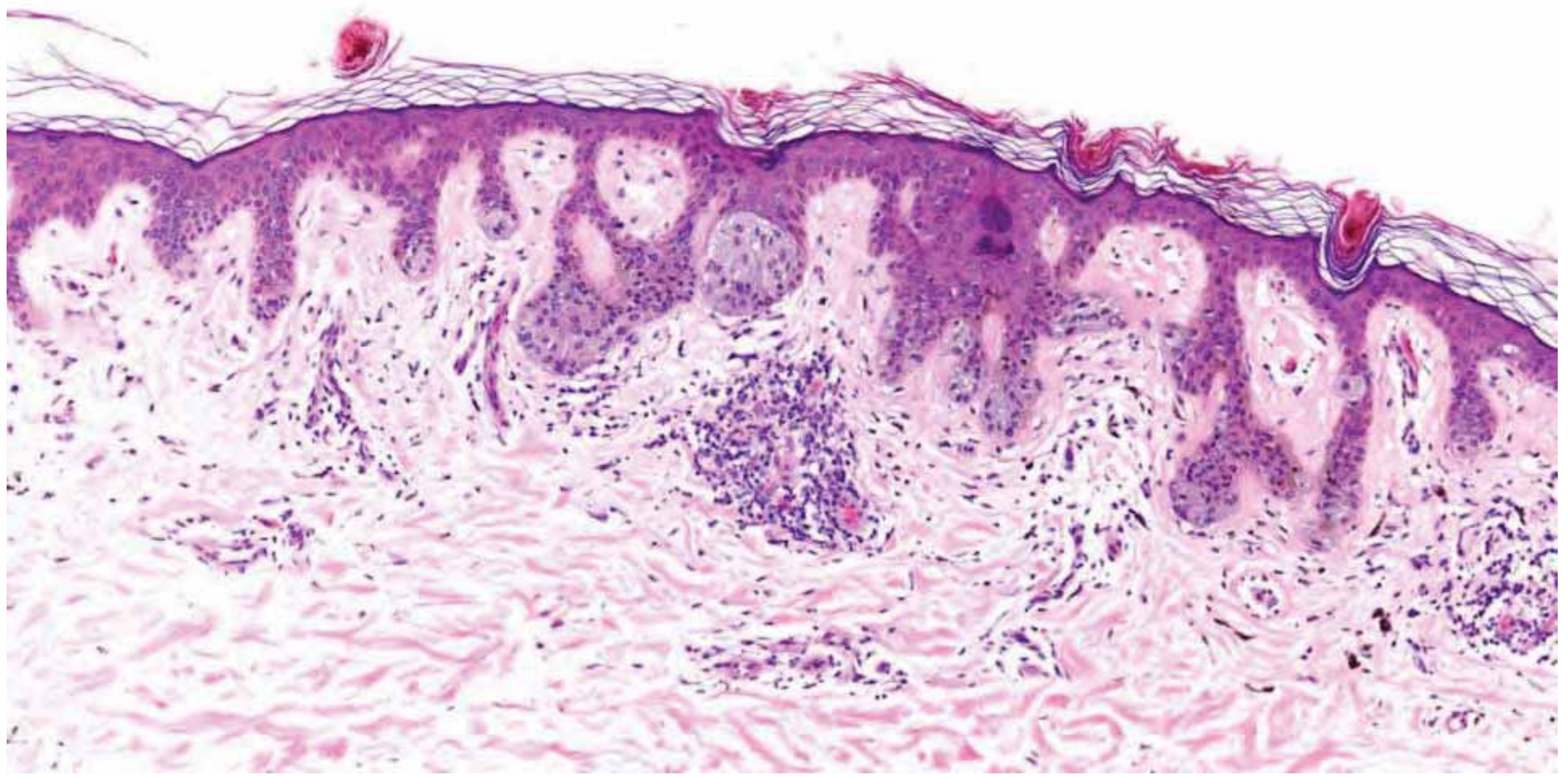


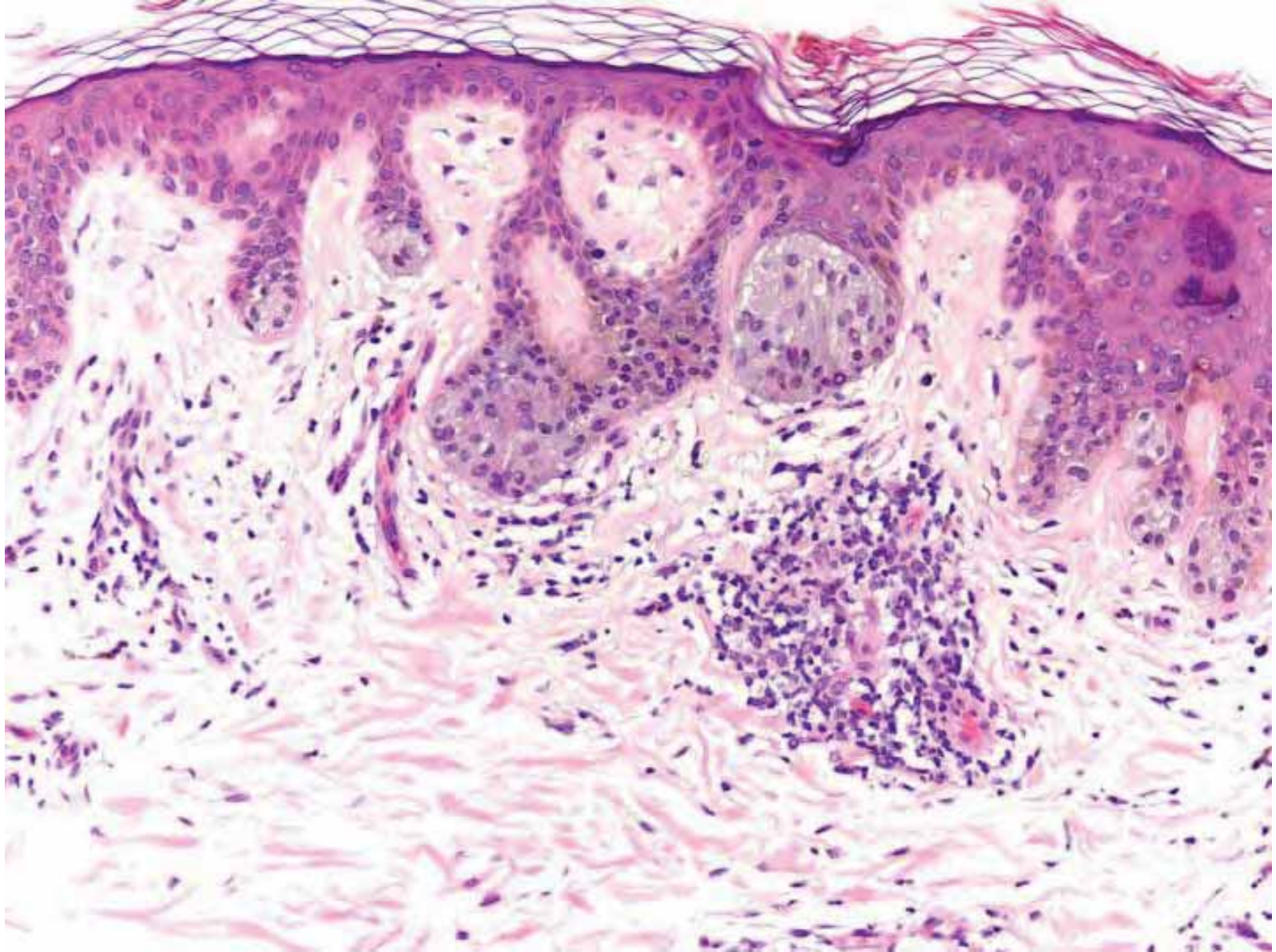


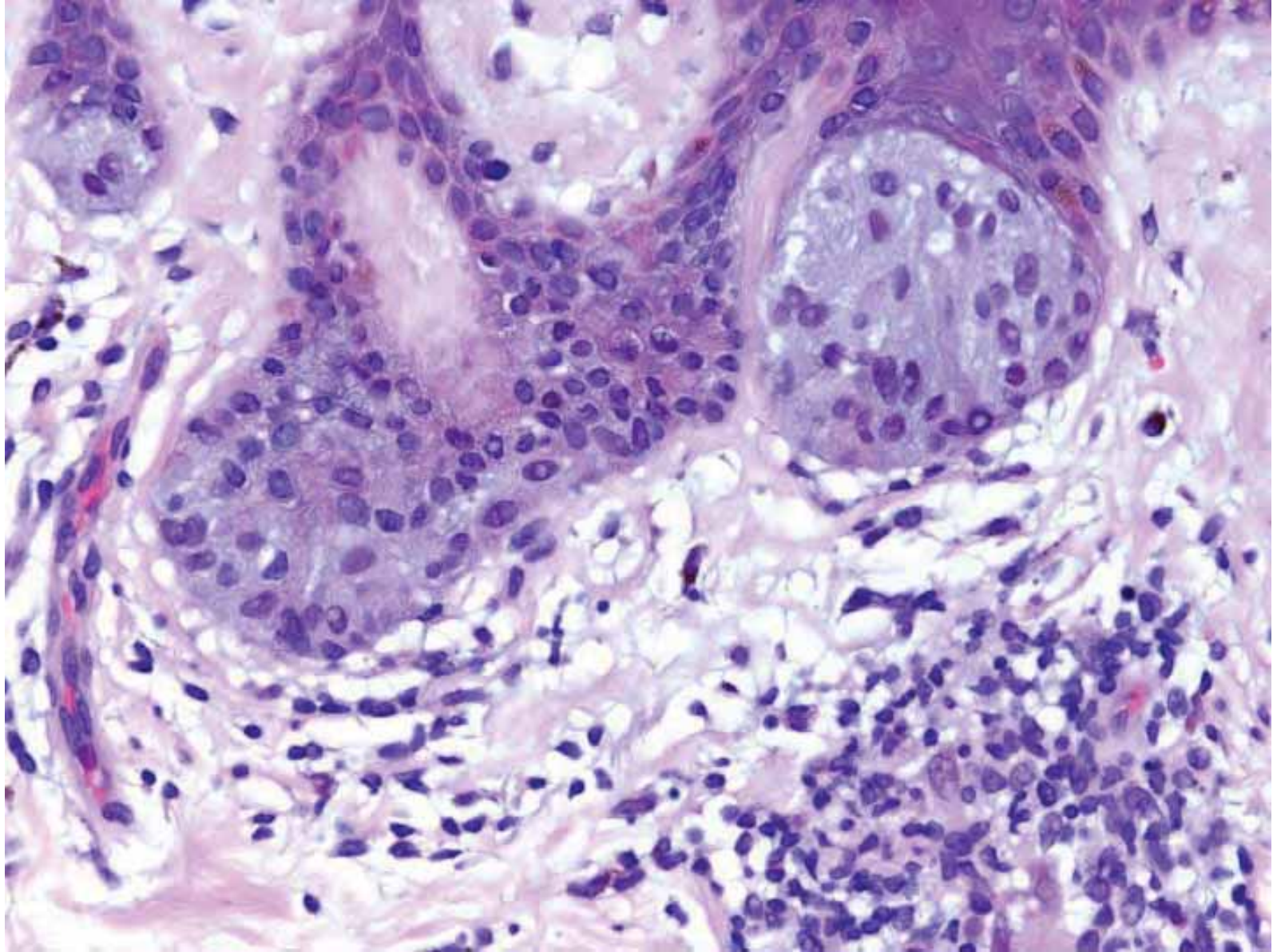


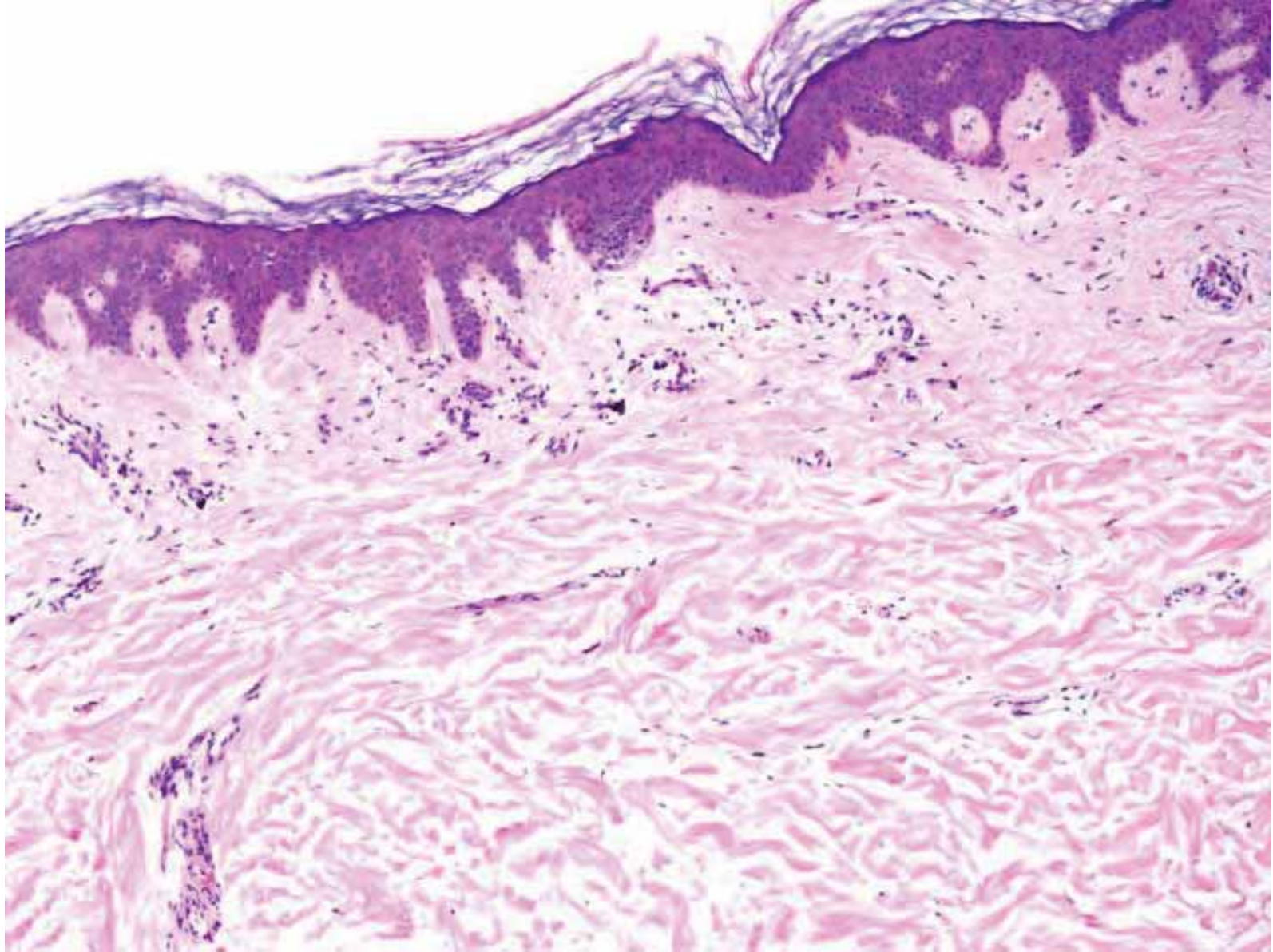


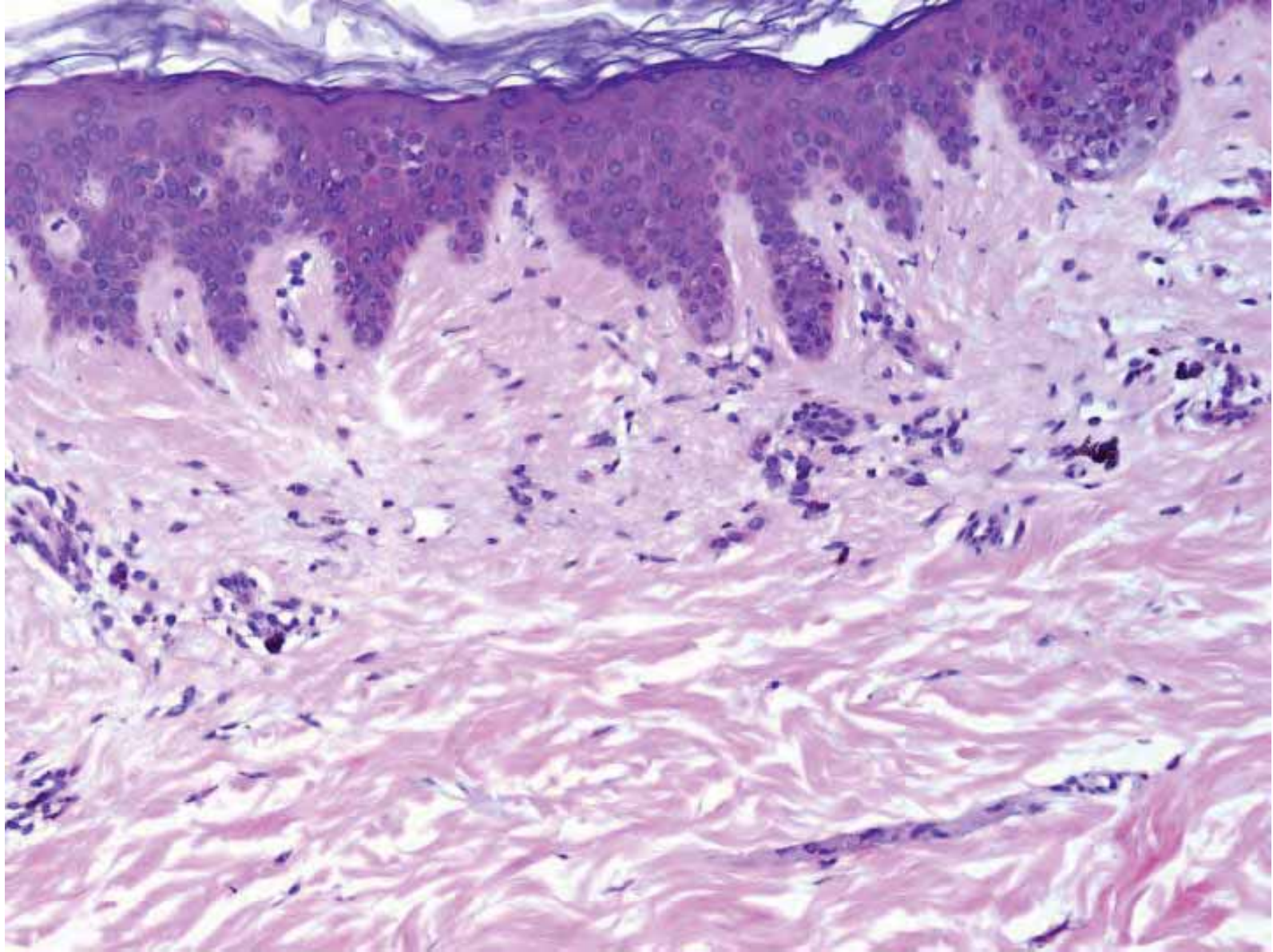


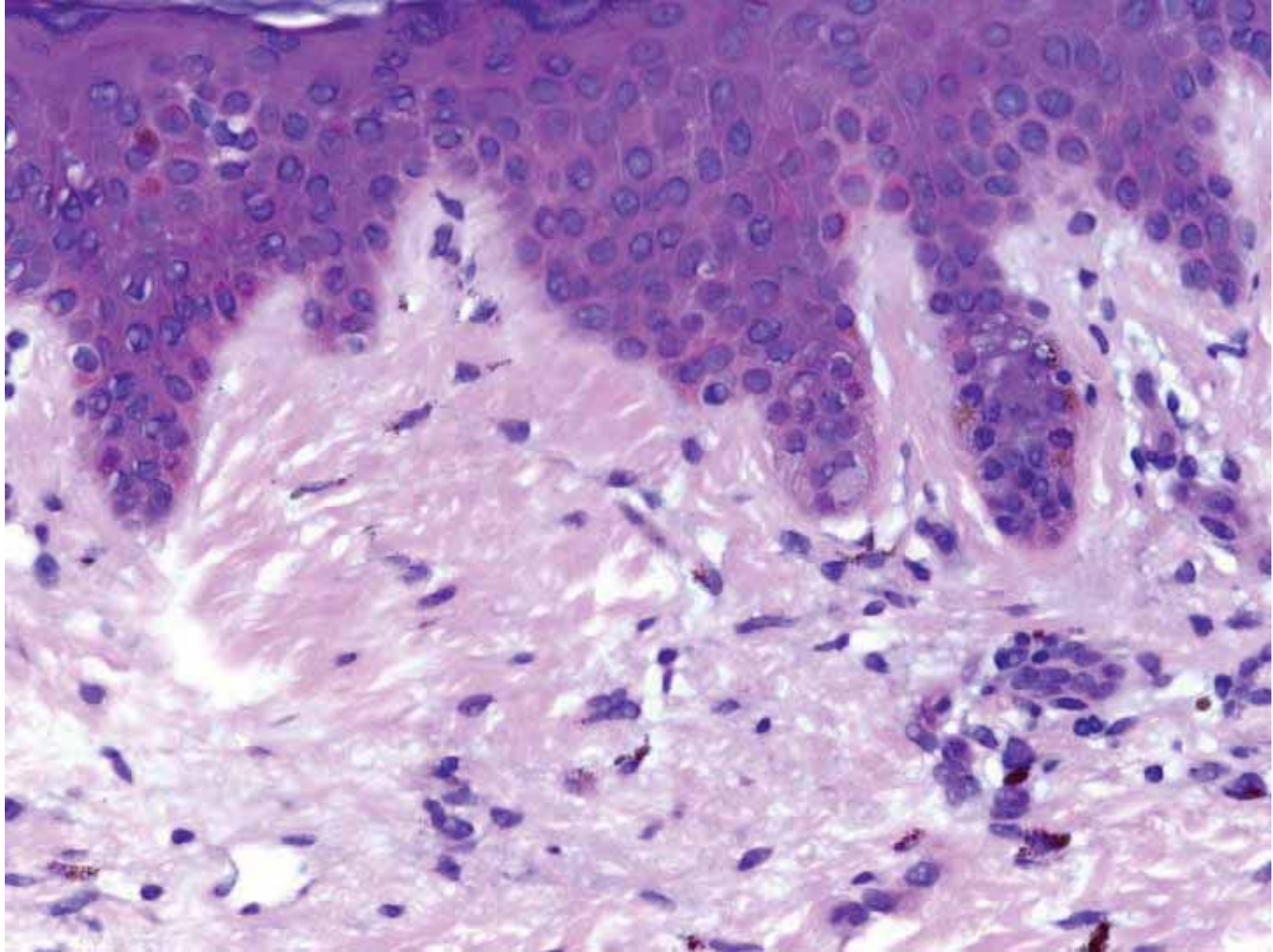


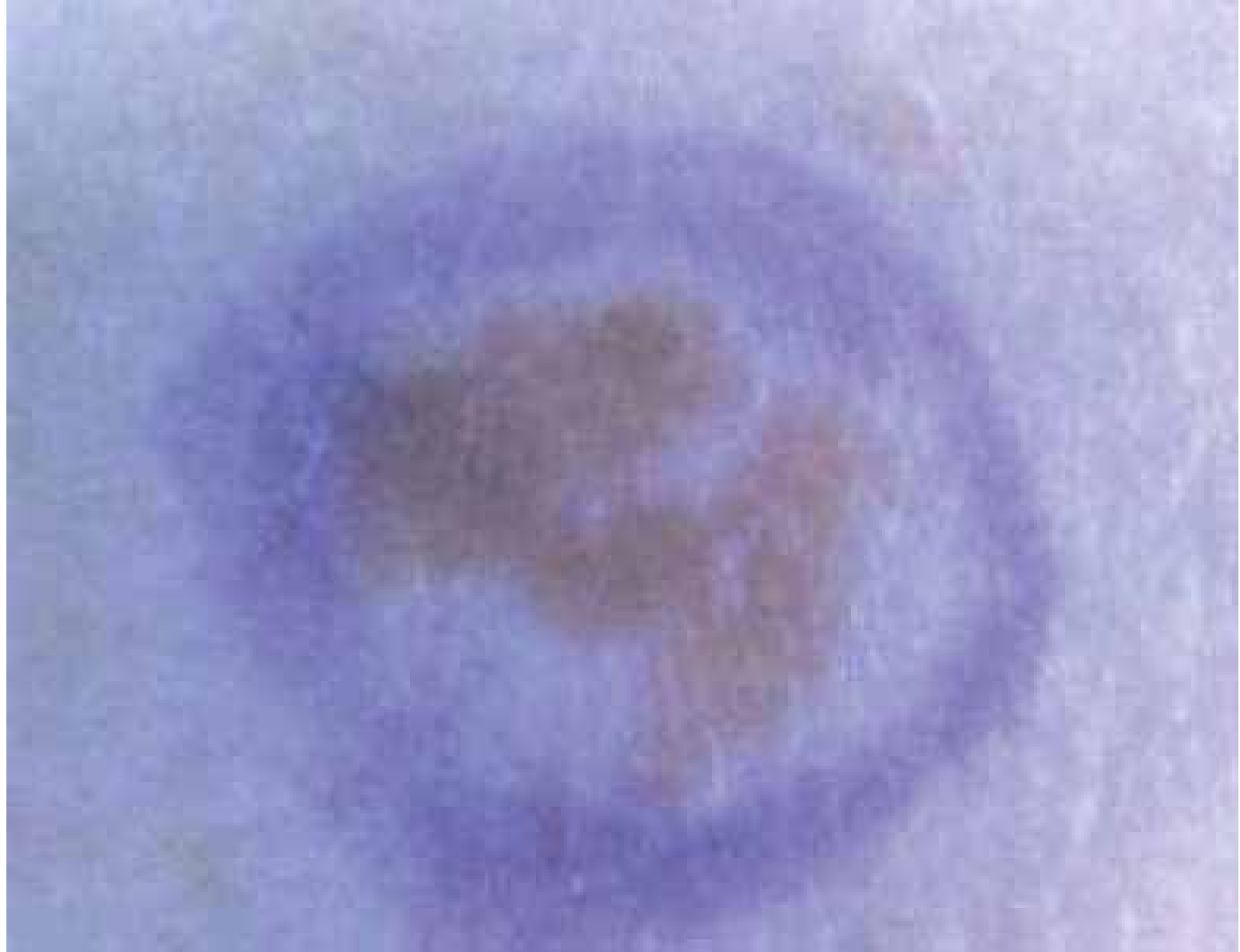











# Clark's (dysplastic) nevus, florid fibroplasia

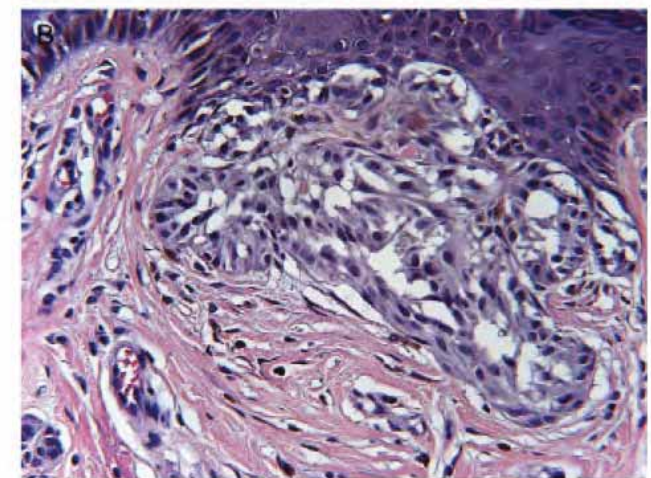
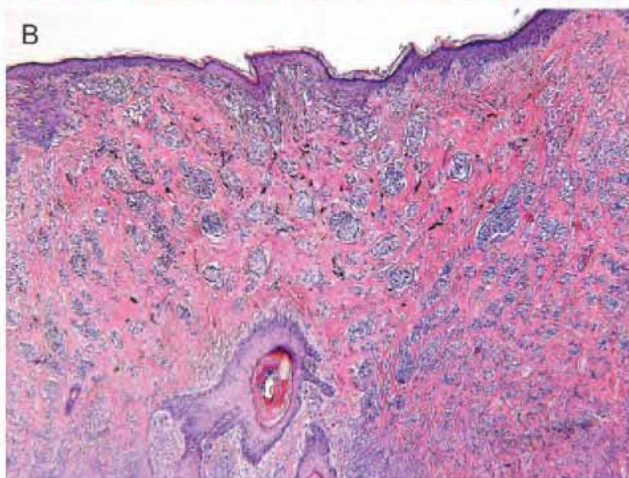
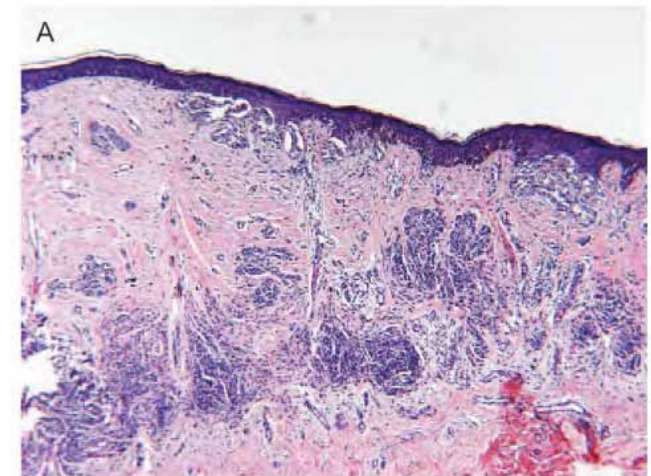
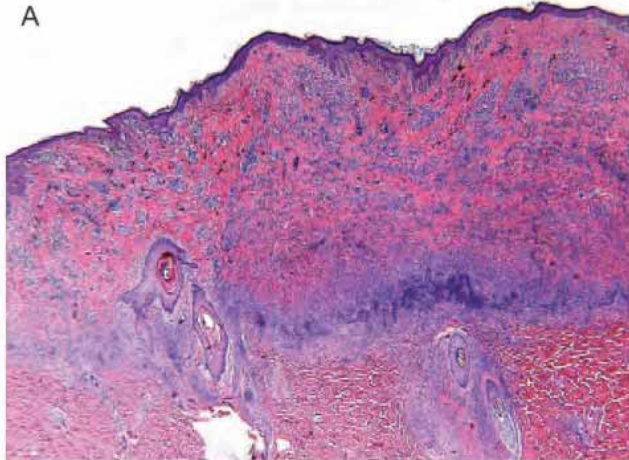
Sclerosing nevus with pseudomelanomatous features

The screenshot shows a PubMed search results page. The search query is "sclerosing nevus with pseudomelanomatous features". The page displays 8 results, with 5 articles found by citation matching. The results list includes:

- Sclerosing nevus with pseudomelanomatous features. Fabrizio G, et al. J Cutan Pathol. 2008. PMID: 18537860
- Sclerosing nevus with pseudomelanomatous features: dermoscopic and confocal aspects. Bombonato C, et al. J Eur Acad Dermatol Venereol. 2019. PMID: 30317655
- Sclerosing nevus with pseudomelanomatous features and regressing melanoma with nevoid features. Ferrara G, et al. J Cutan Pathol. 2009. PMID: 19586505 No abstract available.

The interface includes a search bar, filters for "MY NCBI FILTERS", a "RESULTS, BY YEAR" bar chart, and "TEXT AVAILABILITY" options for "Abstract" and "Free full text".

Fabrizi et al.



---

## **“Clark/dysplastic” nevi with florid fibroplasia associated with pseudomelanomatous features**

Christine J. Ko, MD, Jean L. Bologna, MD, and Earl J. Glusac, MD  
*New Haven, Connecticut*

**Background:** Melanocytic nevi may exhibit histologic features in common with cutaneous melanoma, creating diagnostic difficulties.

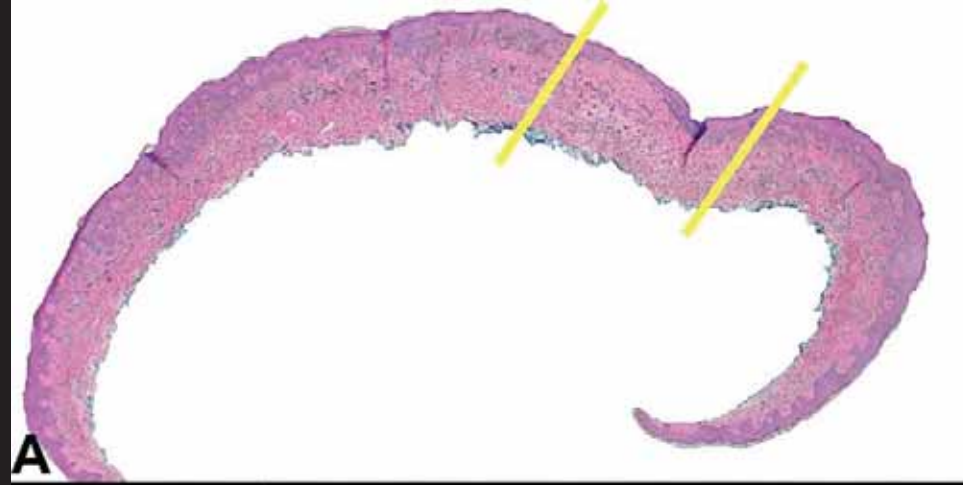**Objective:** We sought to assess the clinical behavior of melanocytic nevi with pseudomelanomatous features in association with dermal fibrosis.

**Methods:** Forty-two melanocytic nevi with pronounced fibrosis and associated pseudomelanomatous changes were collected and studied clinically and histologically.

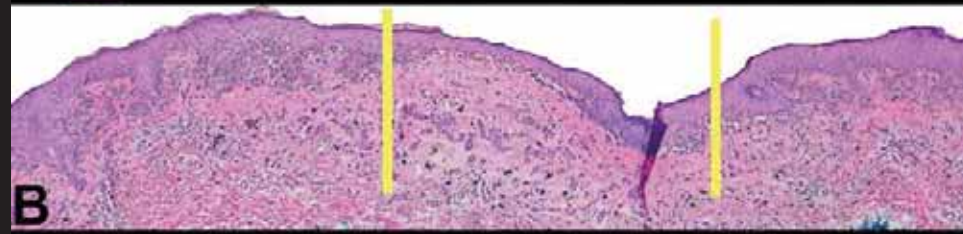
**Results:** The fibrosis was centrally located and laminated in appearance. It imparted a trizonal appearance: a junctional component with prominent single cells and/or irregular nests, underlying fibrosis, and a mature dermal component. No recurrence or metastases were evident over an average follow-up period of 2 years.

**Limitations:** The follow-up period was short.

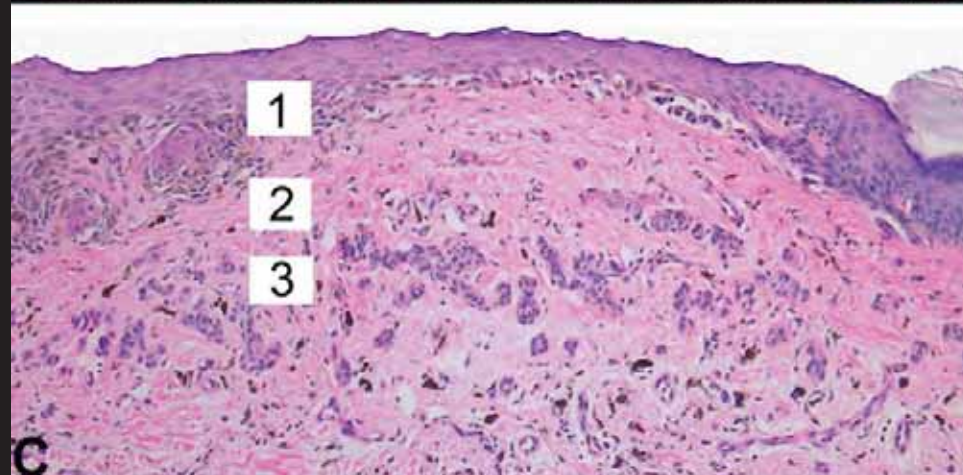
**Conclusions:** The central location and laminated appearance of the fibrosis suggest that this may represent the extreme end of a spectrum of fibroplastic changes in “Clark/dysplastic” nevi. Adjacent features of “Clark/dysplastic” nevi and limitation of pseudomelanomatous features to the perifibrotic focus are important in accurately identifying these lesions. Although melanocytic nevi with exaggerated fibroplasia may show foci with melanoma-like features, they do not appear to exhibit aggressive clinical behavior. (J Am Acad Dermatol 2011;64:346-51.)



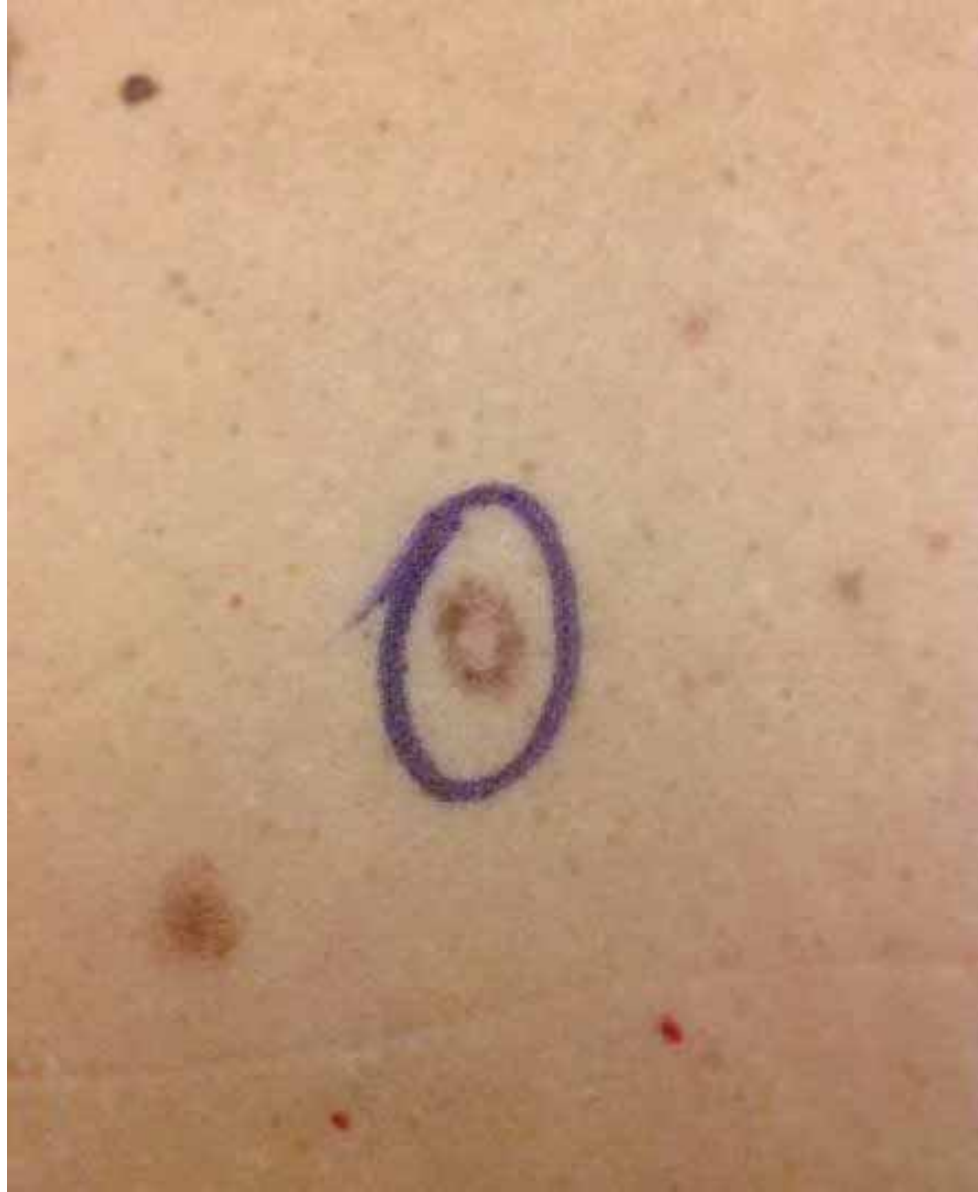**A**

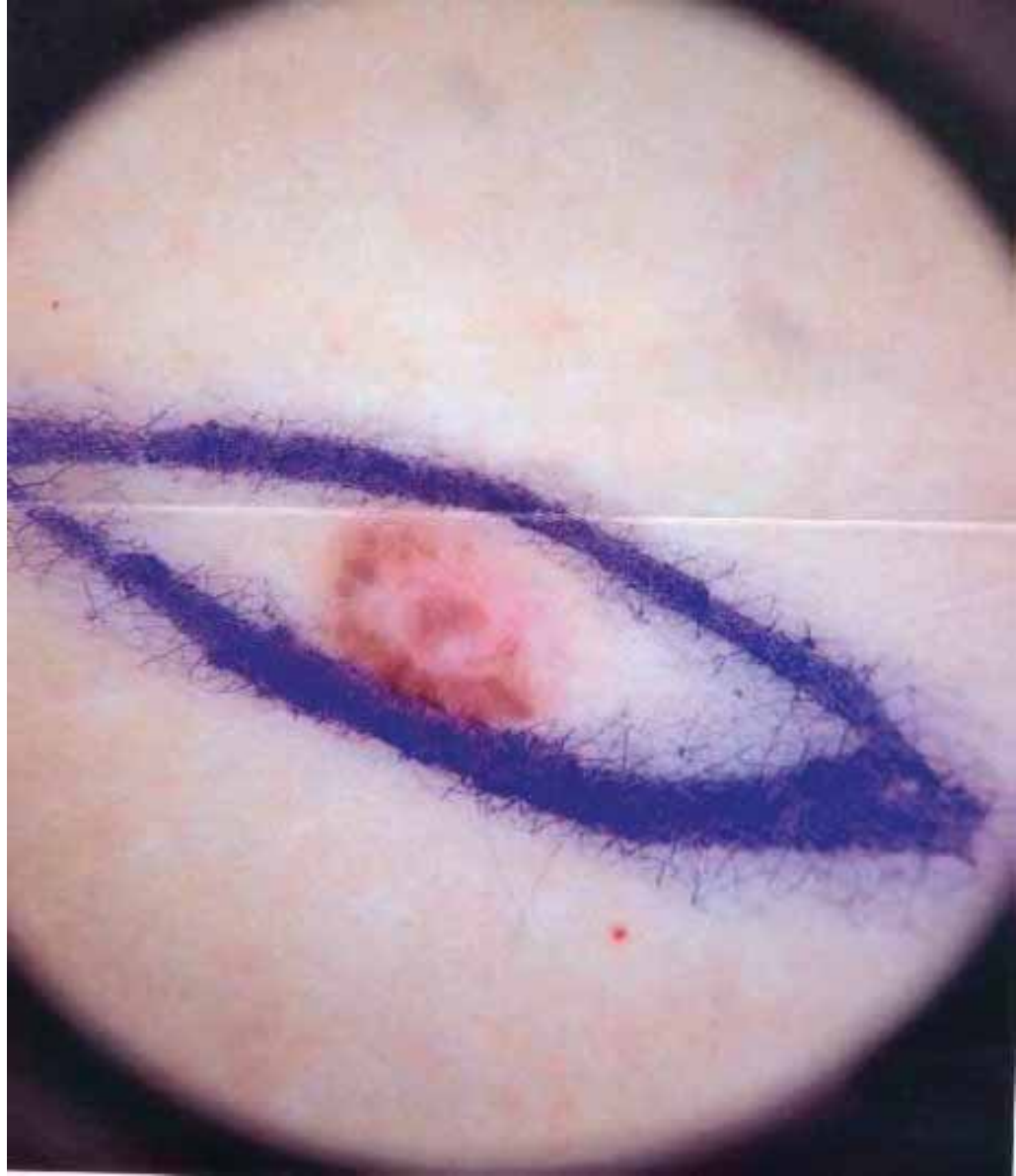

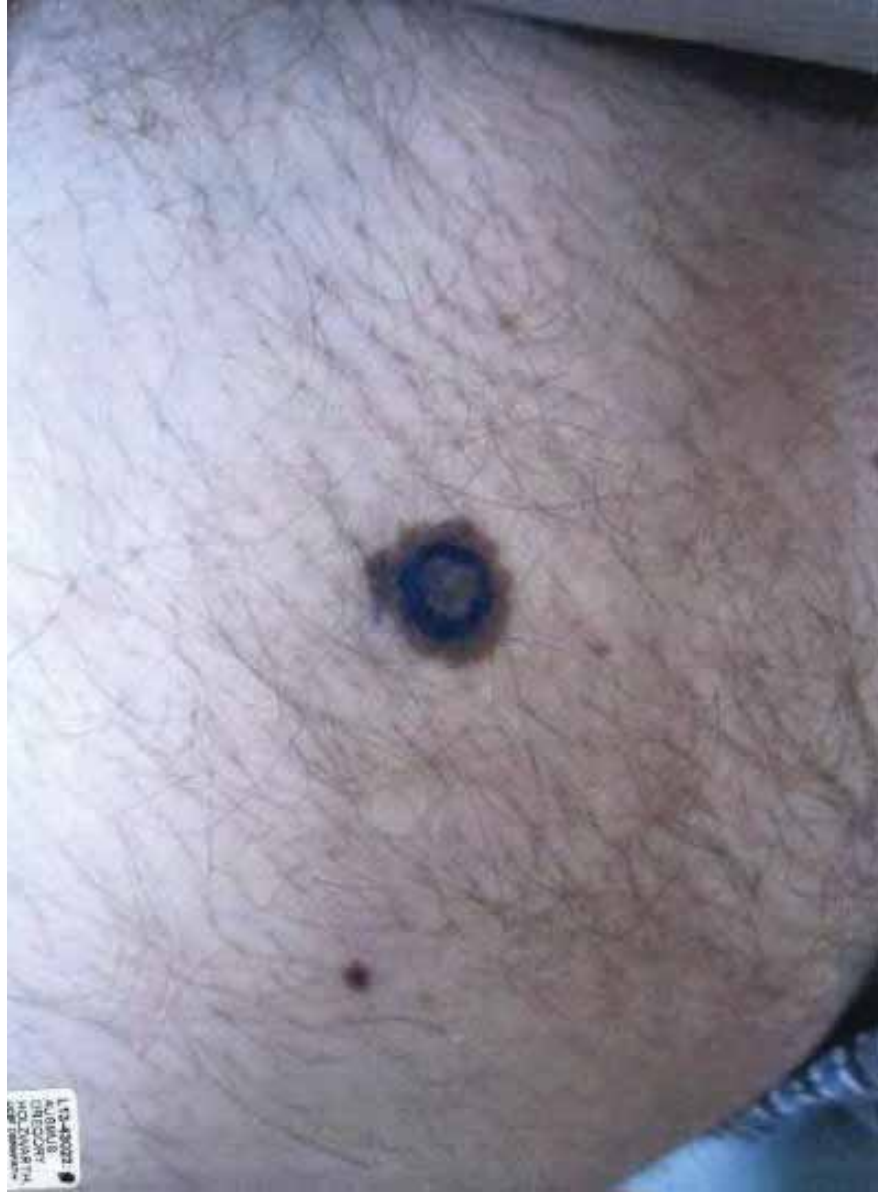**B**



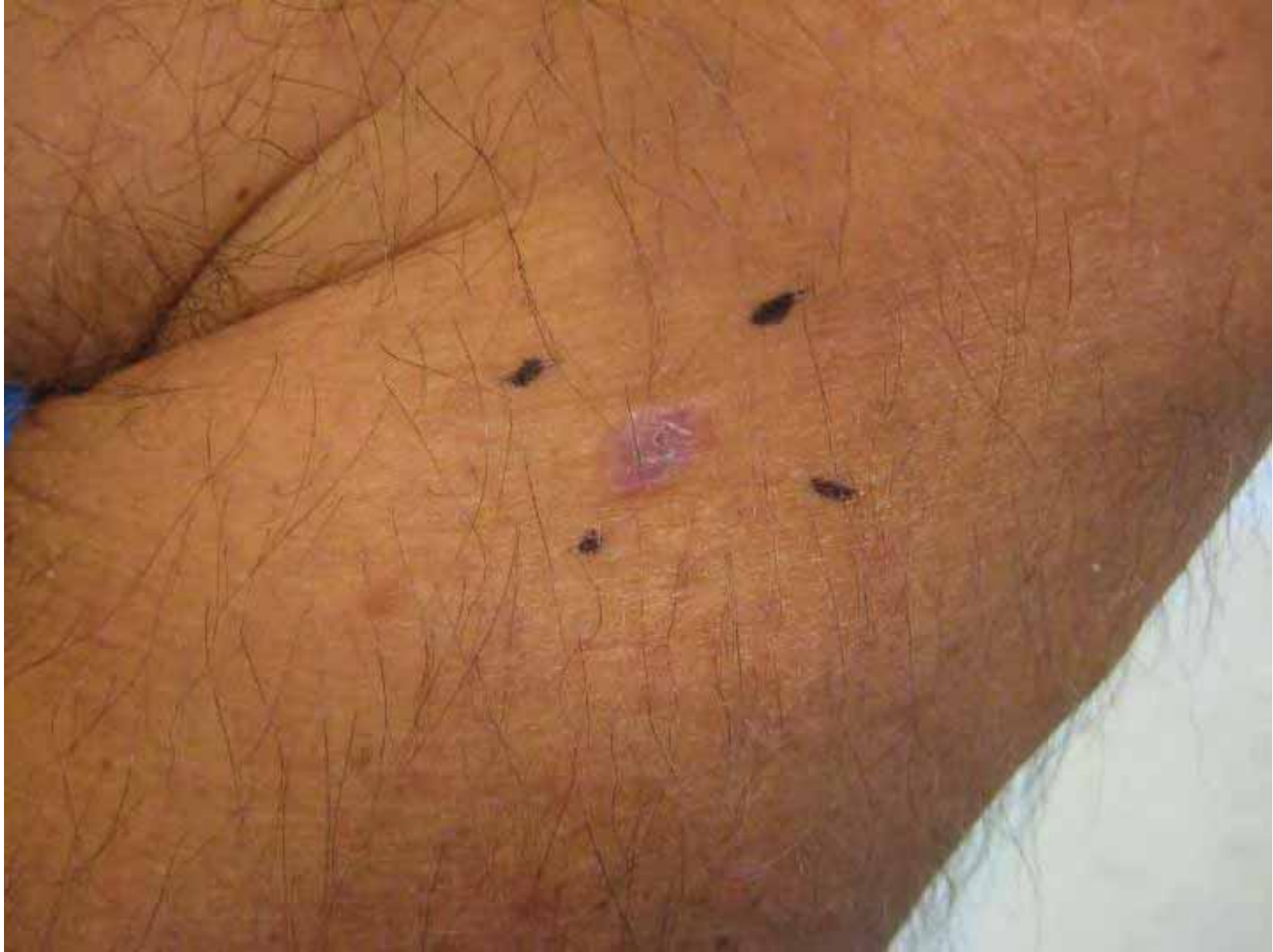**C**

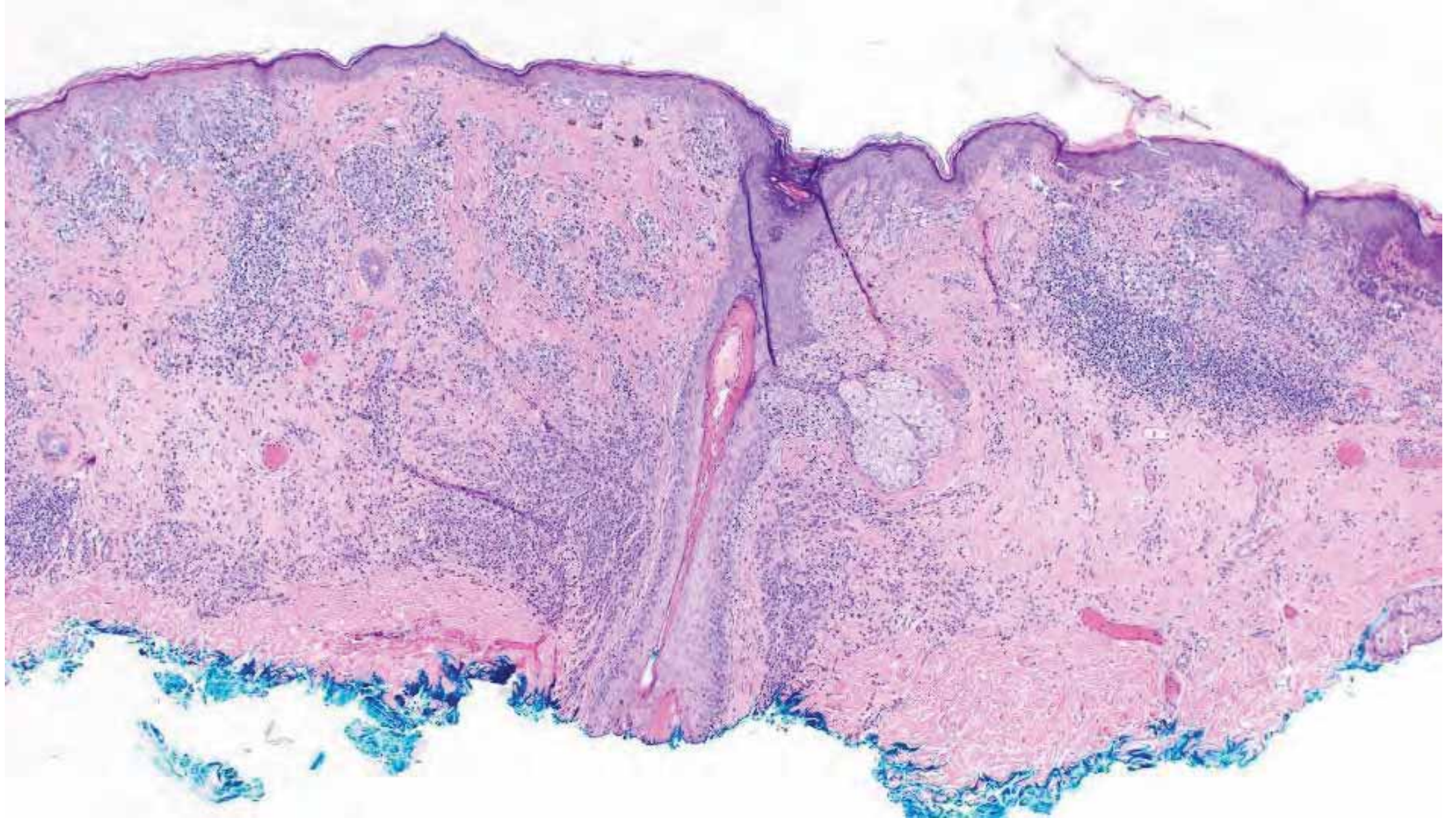

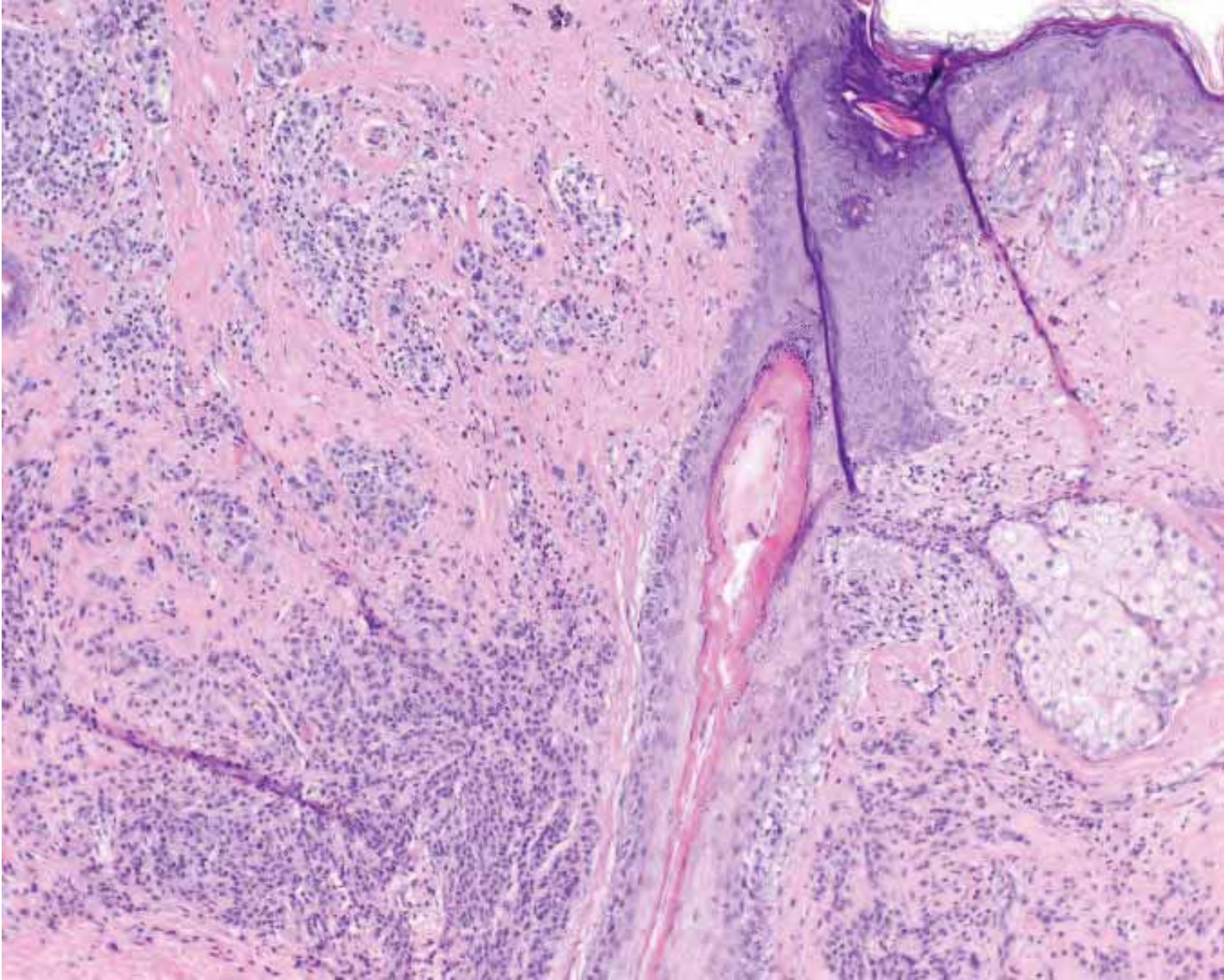


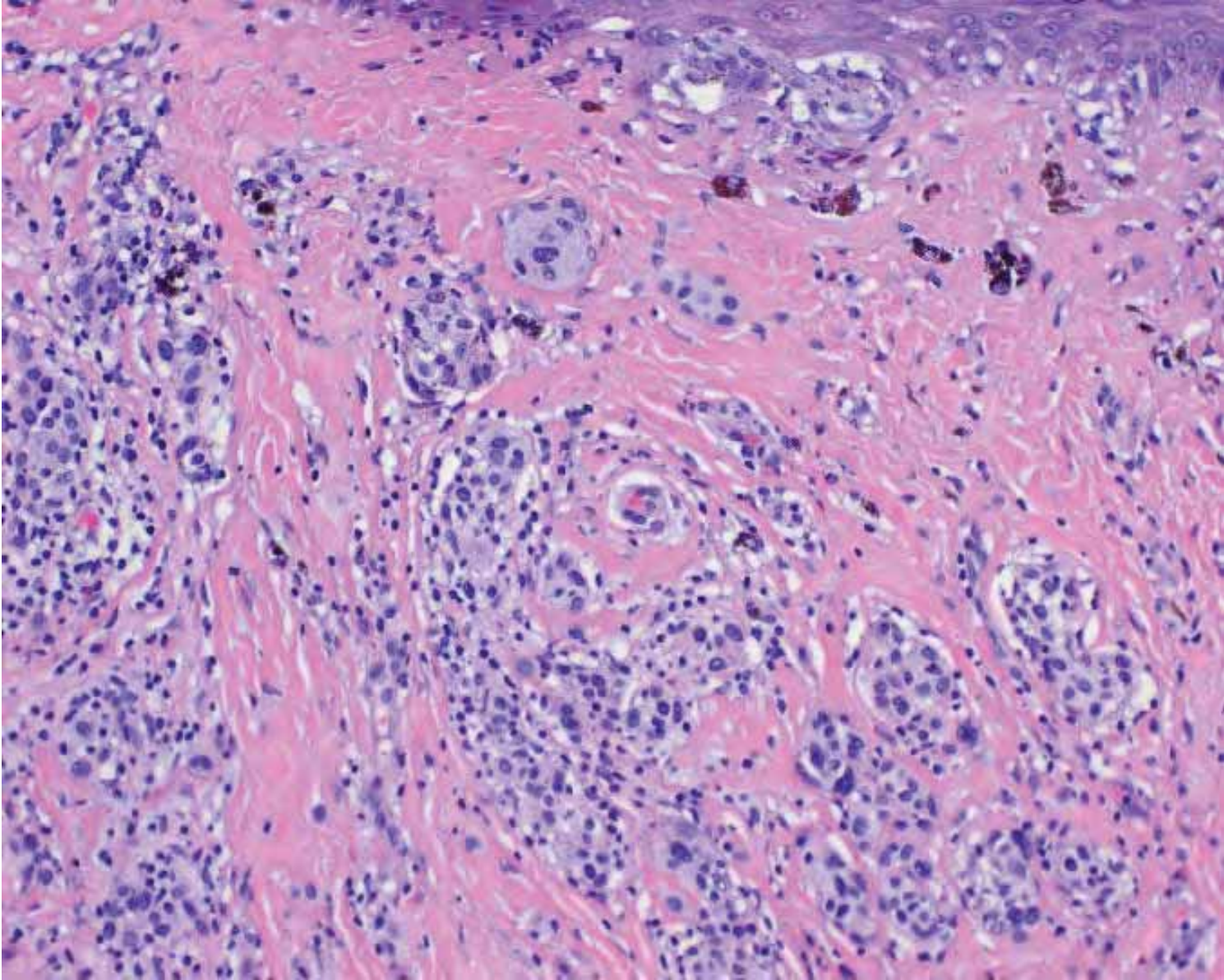


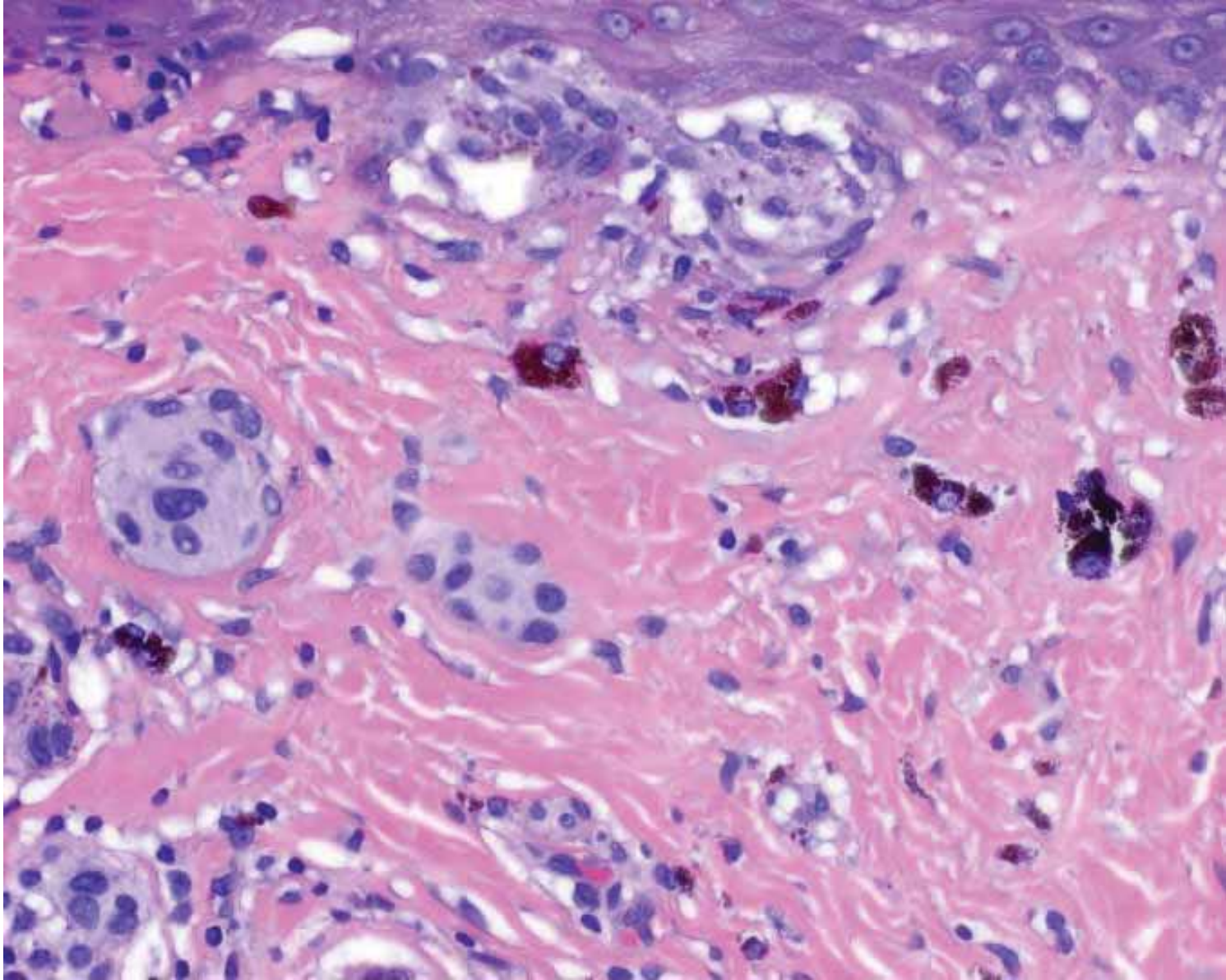
153-40022  
A. J. B. B. B.  
ANATOMY  
FOR TRAINING

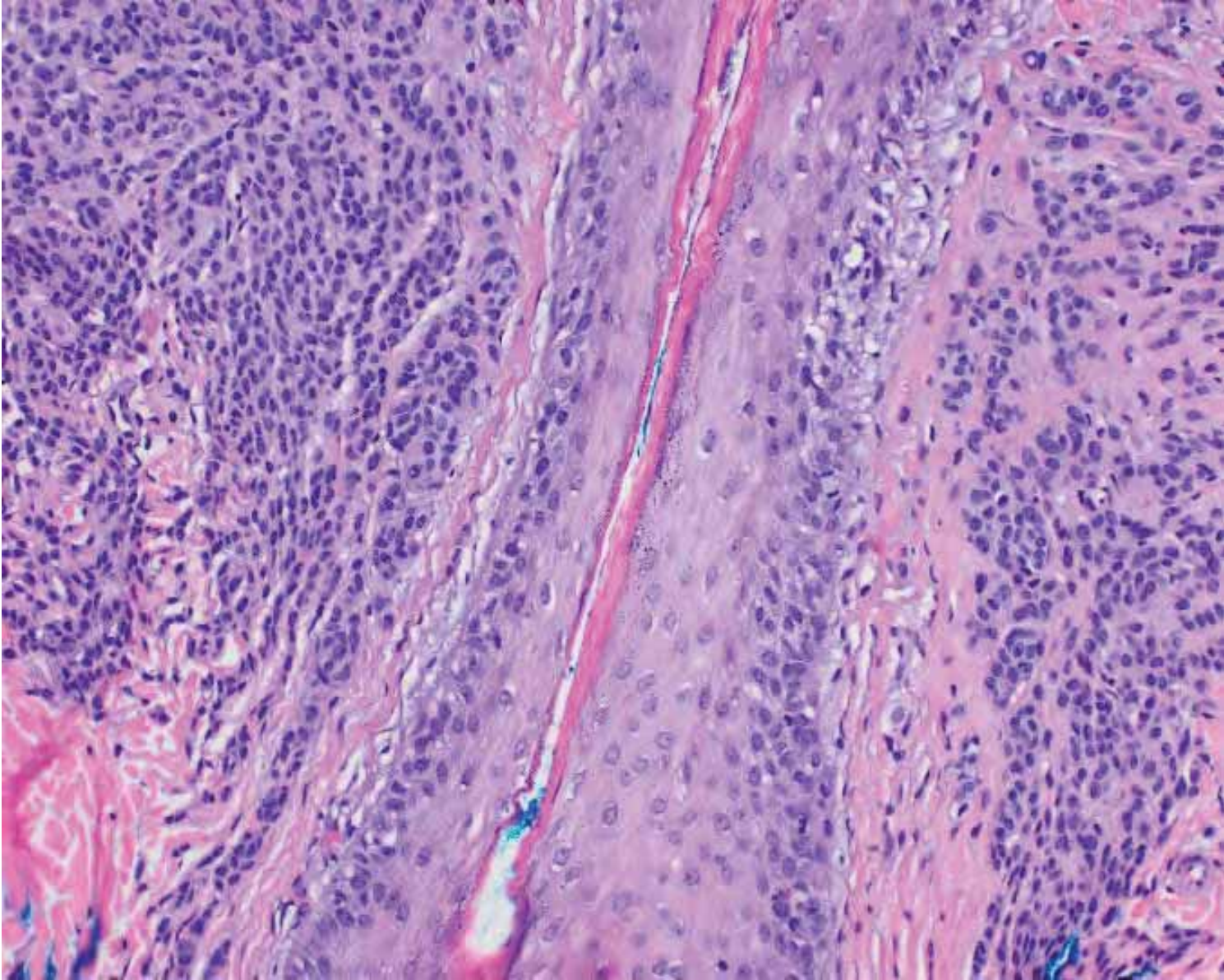


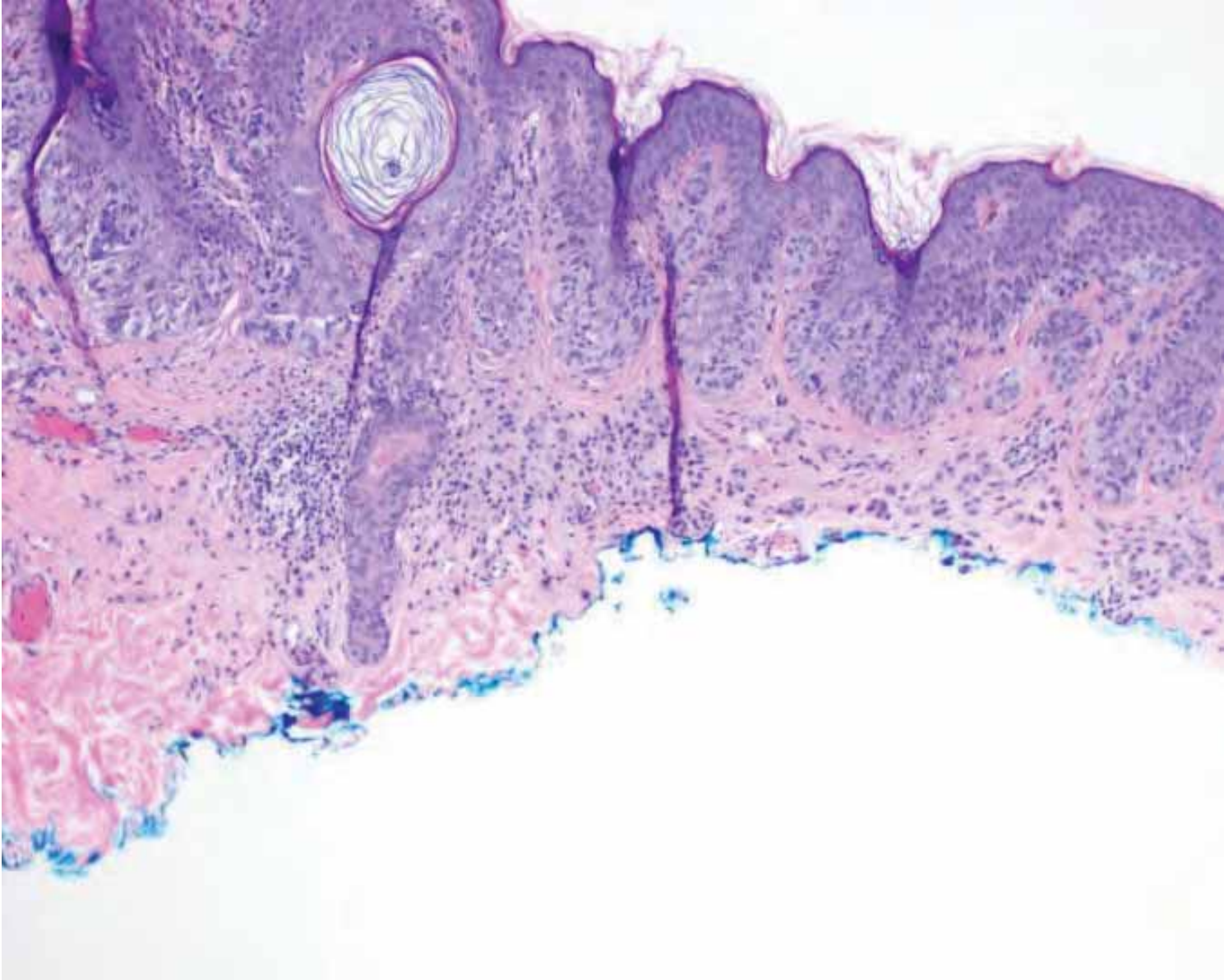


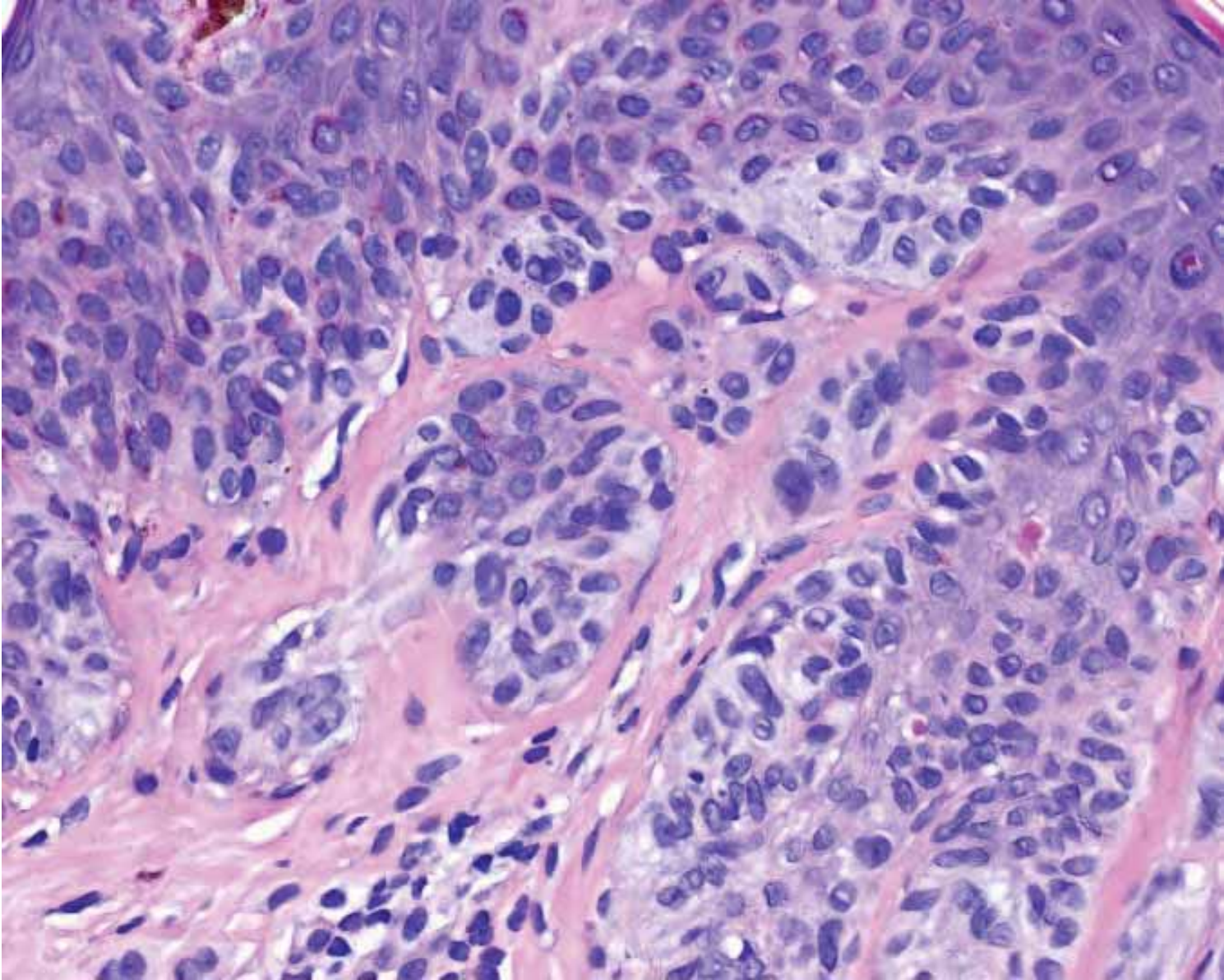


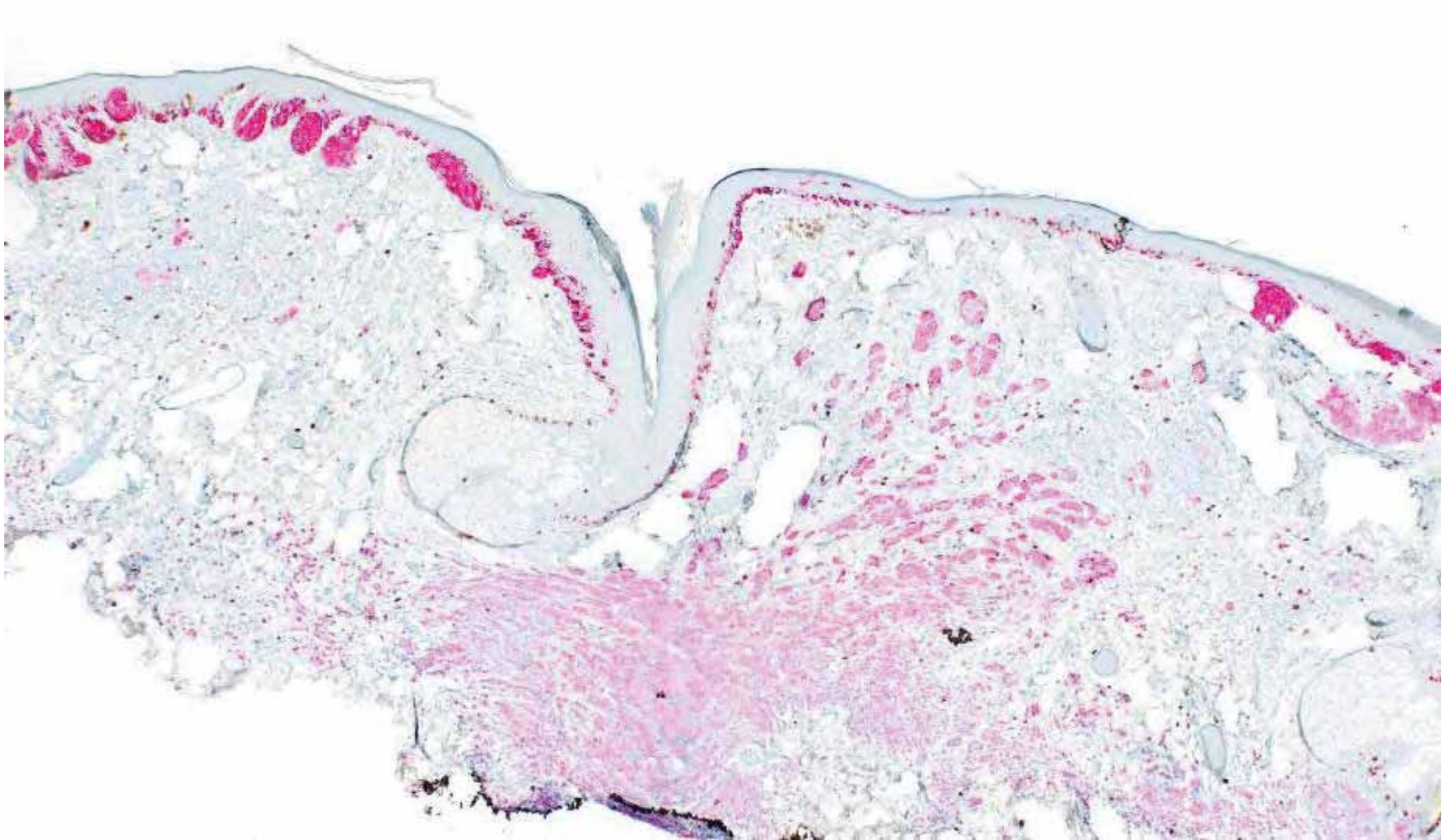


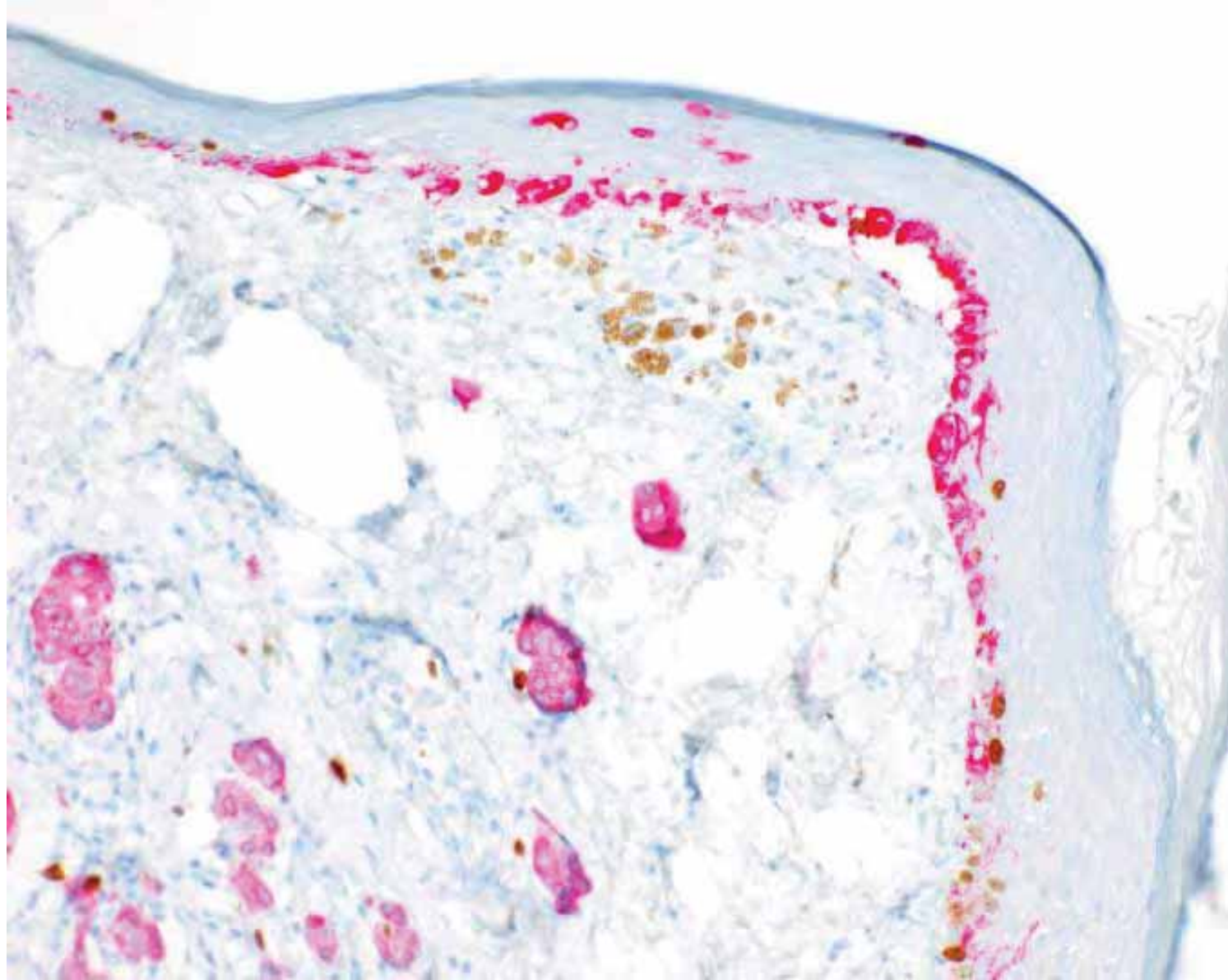


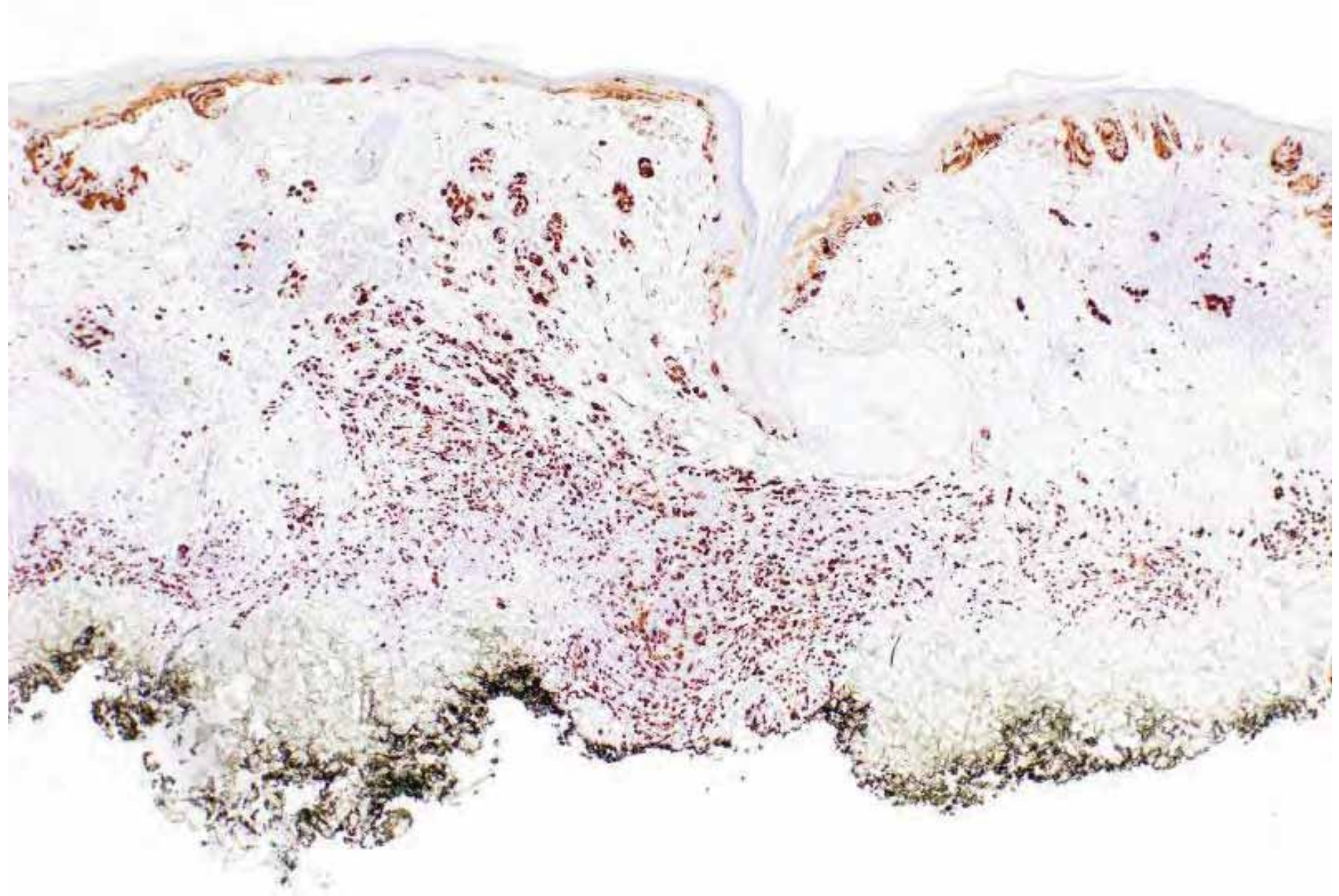


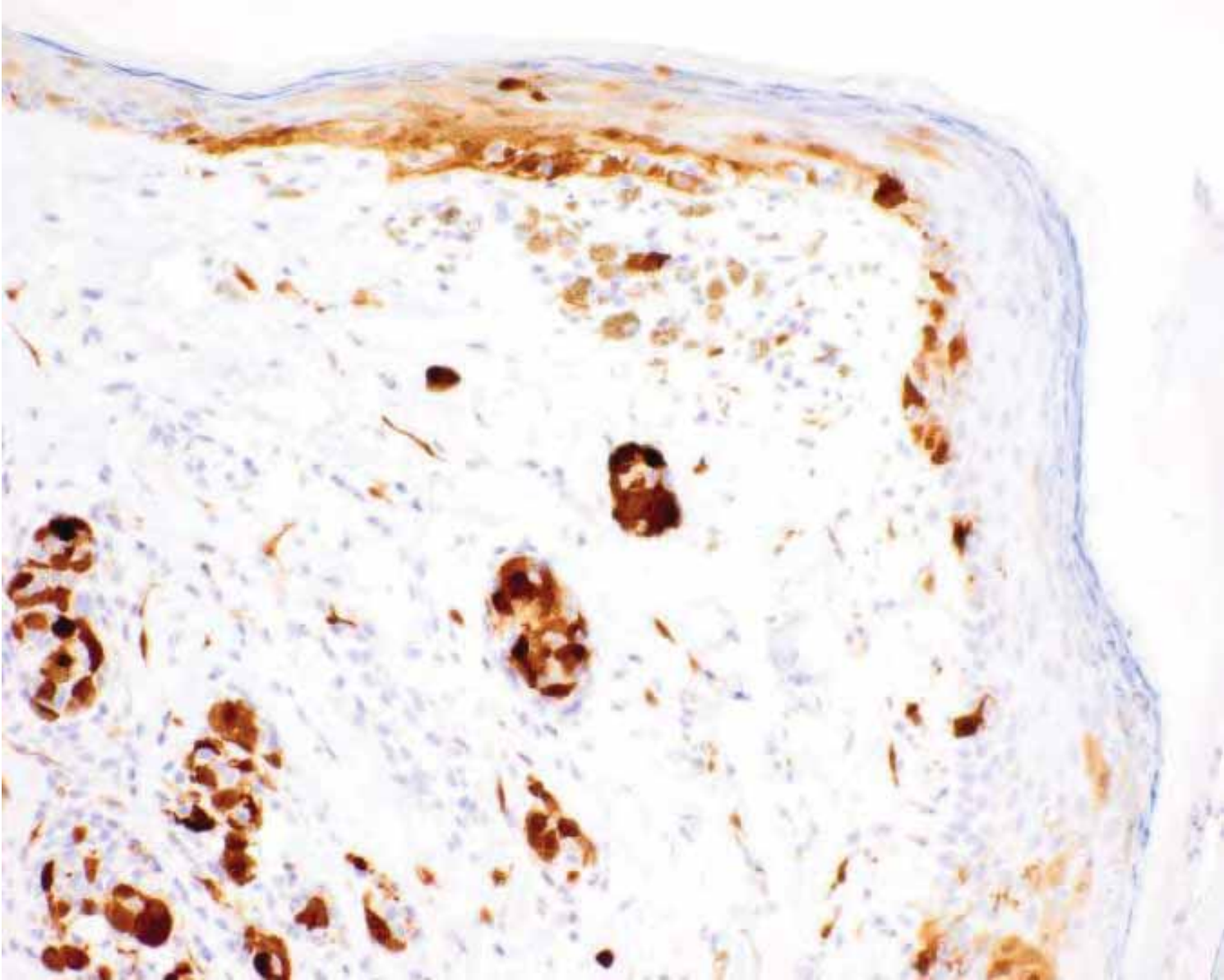






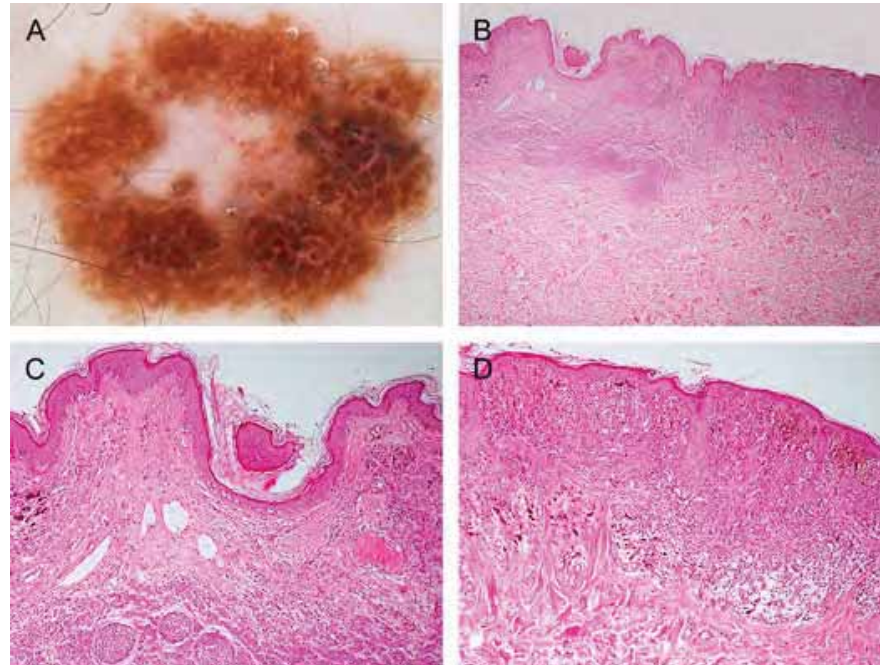






Nevoid melanoma with sclerosing  
features

Sclerosing nevus with pseudomelanomatous features and



*research article*

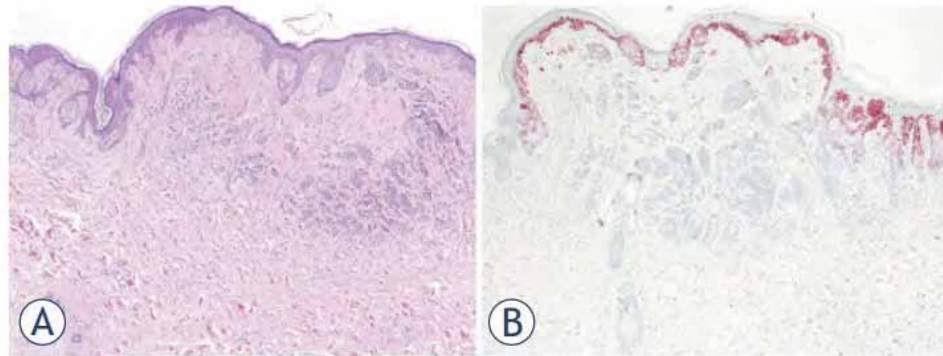
## **Sclectosing melanocytic lesions (sclectosing melanomas with nevoid features and sclectosing nevi with pseudomelanomatous features) - an analysis of 90 lesions**

Biljana Grcar-Kuzmanov<sup>1</sup>, Emanuela Bostjancic<sup>2</sup>, Juan Antonio Contreras Bandres<sup>1</sup>,  
Joze Pizem<sup>2</sup>

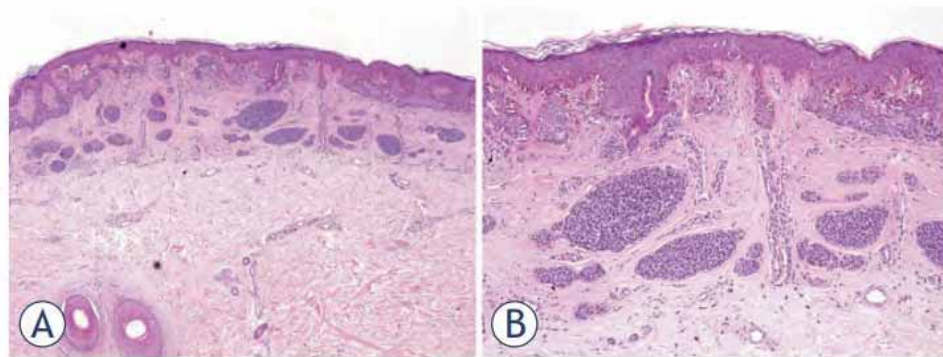
<sup>1</sup> Department of Pathology, Institute of Oncology, 1000 Ljubljana, Slovenia

<sup>2</sup> Institute of Pathology, Faculty of Medicine, University of Ljubljana, 1000 Ljubljana, Slovenia

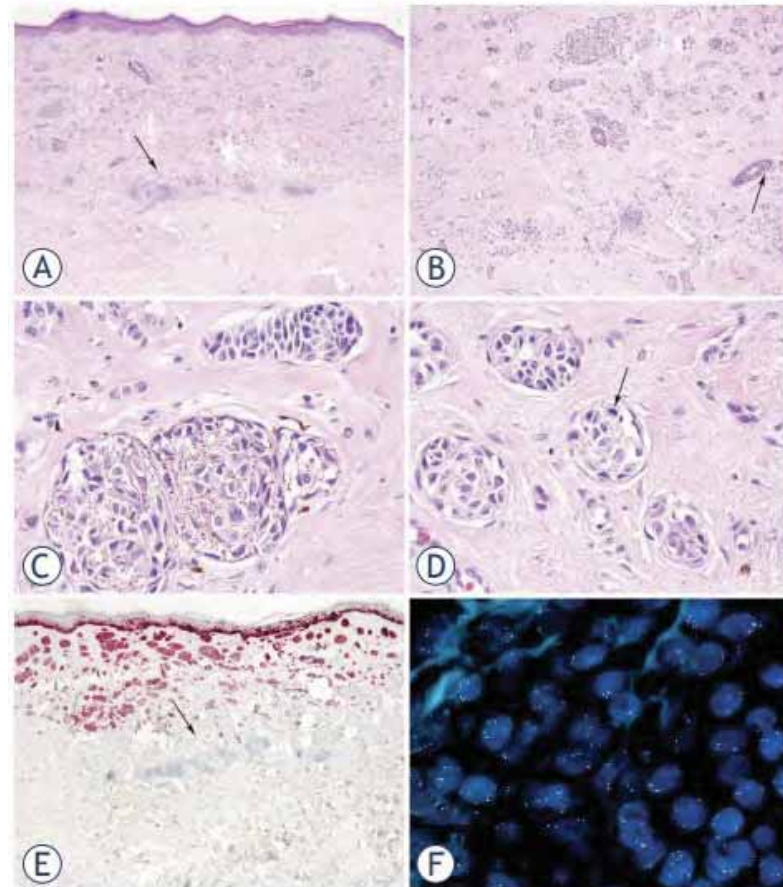
Radiol Oncol 2018; 52(2): 220-228



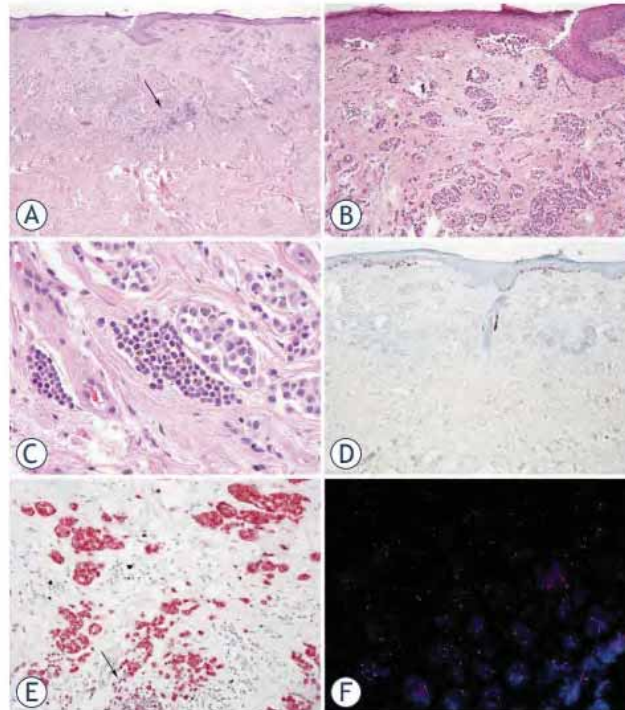
**FIGURE 1.** Sclerosing melanocytic nevus from the abdomen of a 22-year-old woman, with negative FISH assay. **(A)** There is a trizonal pattern, maturation and an atypical intraepidermal component above the sclerosis, which does not extend beyond the sclerosis. **(B)** HMB-45 stain shows maturation in the dermal component.



**FIGURE 2.** Sclerosing melanocytic nevus from the abdomen of a 53-year-old man, with negative the FISH assay. **(A), (B)** There is lamellar-type sclerosis involving the entire dermal component.



**FIGURE 3.** Sclerosing melanoma from the abdomen of a 67-year-old man. **(A)** There are remnants of a nevus below the melanoma (arrow) and a trizonal pattern. **(B)** Some melanocytes are in the epithelium of an eccrine duct (arrow). **(C)** Melanocytes within sclerosis are atypical, with prominent nucleoli. **(D)** There is a mitotic figure (arrow). **(E)** HMB-45 staining is irregular diffuse in the sclerotic dermal component (melanoma) but negative in the nevus below (arrow). There is prominent pagetoid spread in the epidermis. **(F)** The FISH assay was positive, showing loss of MYB (gold) relative to CEP6 (aqua) in 57% of tumor cell nuclei.



**FIGURE 4.** Sclerosing melanoma from the back of a 70-year-old female. **(A)** There are remnants of a nevus below sclerosis (arrow). **(B)** Melanocytes in the sclerosis do not show maturation and **(C)** are larger with irregular nuclei and prominent nucleoli compared to melanocytes in the adjacent nevus (left). **(D)** HMB-45 stain shows pagetoid spread in the epidermis, but is completely negative in the dermis. **(E)** Ki67 (brown)/melan A (red) shows no proliferative activity in the melanocytes in the deepest aspect of the sclerotic component; note less intense melan A positivity in the nevus below the melanoma (arrow). **(F)** The FISH assay was positive, showing gain in RREB1 (red) in 30% of tumor cell nuclei.

The four-probe FISH assay was positive in 14 of 25 (56%) of the lesions diagnosed morphologically as melanomas and in none of 16 nevi, providing additional evidence that sclerosing melanocytic lesions include both nevi and melanomas. Although the four-probe FISH assay has been reported to have a sensitivity of about 85% for diagnosing unequivocal melanomas, its sensitivity is much lower (about 50%) in ambiguous melanocytic lesions and in some melanoma types, including desmoplastic melanoma.<sup>20,21,26</sup> Negative FISH results do not therefore rule out a melanoma. Nevertheless, although the sensitivity of the FISH assay for sclerosing melanomas may be lower than for unequivocal ordinary melanomas, it is likely that some of our lesions had been morphologically overdiagnosed as melanomas. Although the FISH assay has been

## Nevoid melanoma: A study of 43 cases with emphasis on growth pattern

Munir H. Idriss, MD,<sup>a</sup> Lubna Rizwan, MBBS, MCPS, FCPS,<sup>a</sup> Anthony Sferuzza, PhD,<sup>b</sup> Elen Wasserman, DO,<sup>a</sup>  
Viktoryia Kazlouskaya, MD,<sup>a</sup> and Dirk M. Elston, MD<sup>a</sup>  
*New York, New York, and San Juan Capistrano, California*

**Background:** Nevoid melanoma may be confused both clinically and histologically with benign nevi.

**Objective:** The aim of this study was to characterize the histologic features of nevoid melanoma.

**Methods:** Forty-three cases of nevoid melanoma from our laboratory were evaluated.

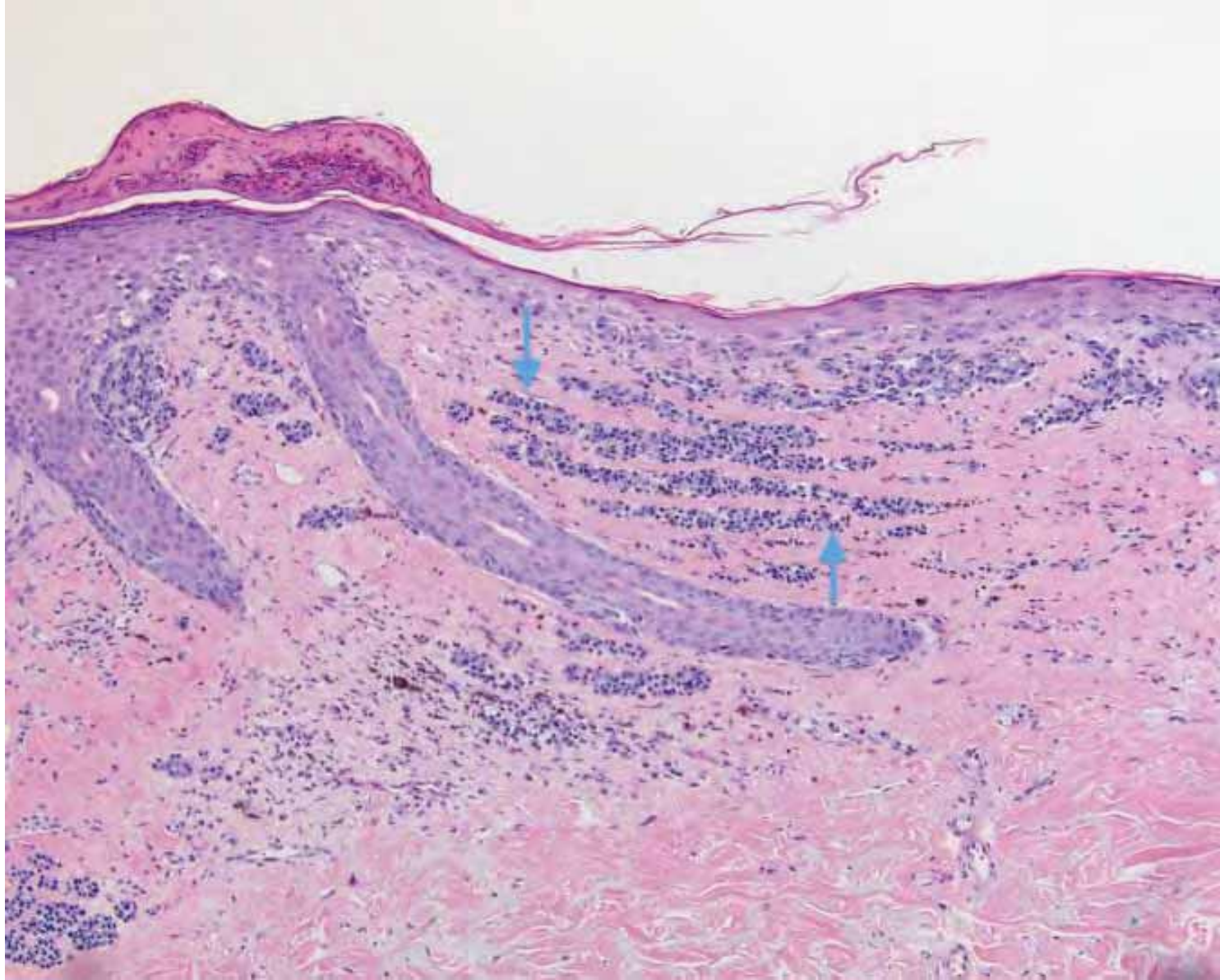**Results:** Our study cases included 33 men and 10 women with mean age of 62 years. The back was the most common site followed by the arm. A clinical diagnosis other than melanoma was made in about 40% of the cases. Two architectural patterns were identified: Plaque and polypoid. Sheetlike confluence of melanocytes expanding the papillary dermis was seen in 60% of the cases. Nests disposed in parallel arrays at the base of the tumor (parallel theque pattern) were present in roughly 81% of our series. Mitoses were evident in one-third of cases ranging from less than 1 to 4 per square millimeter. Genomic abnormalities characteristic of melanoma were detected in 7 of 8 tested cases.

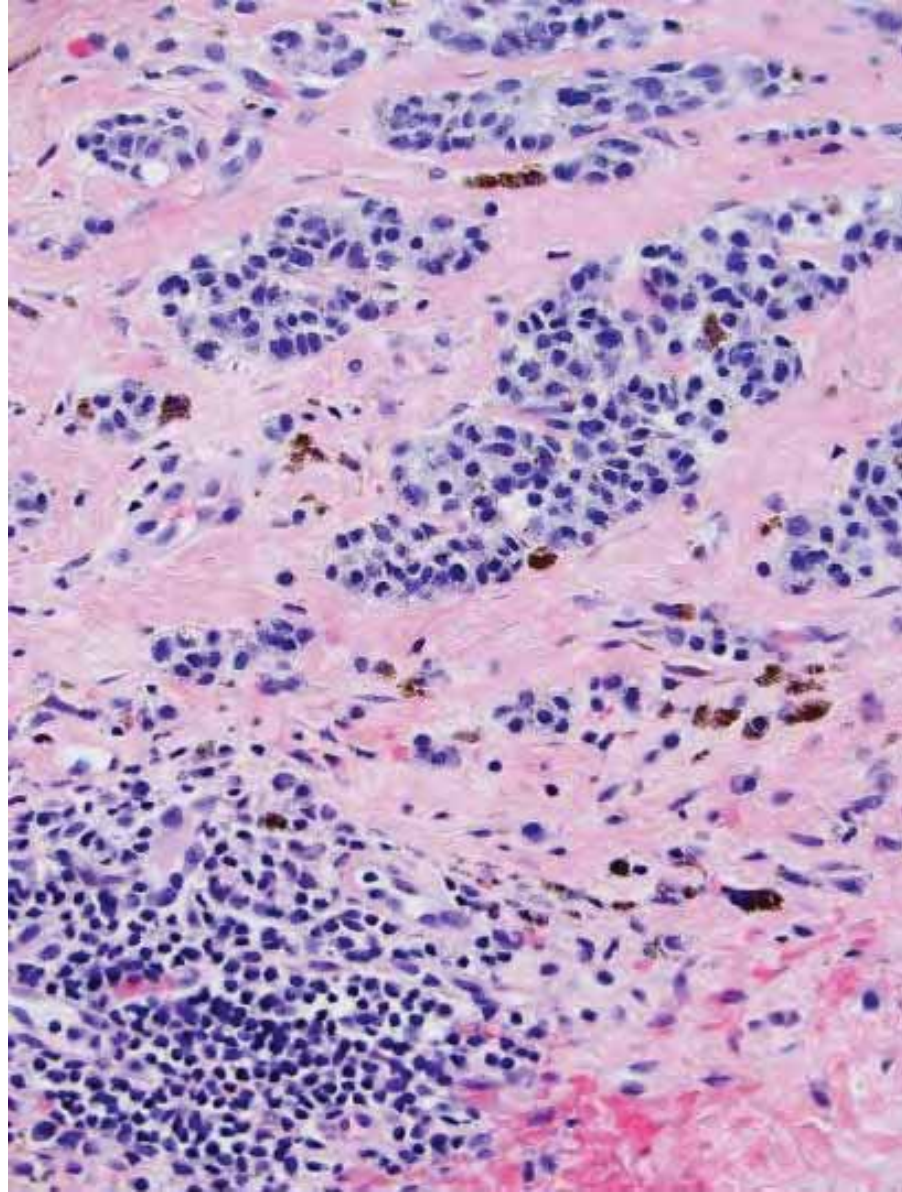
**Limitation:** This is a descriptive study. No follow-up information was available for 32 of the 43 patients. In the other 11, follow-up was limited to the re-excision specimens.

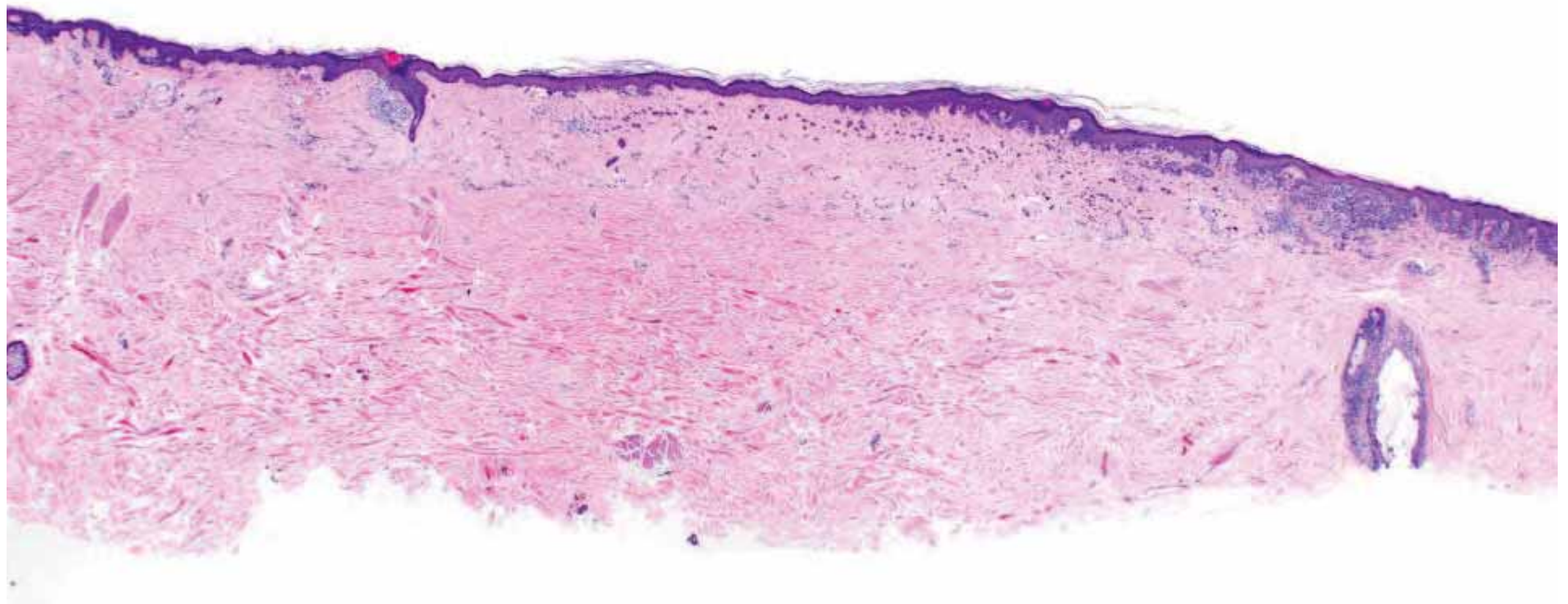
**Conclusion:** Characteristic growth patterns including confluence of dermal melanocytes with no intervening connective tissue and the parallel theque pattern can be helpful in suggesting a diagnosis of nevoid melanoma at scanning magnification. (J Am Acad Dermatol 2015;73:836-42.)

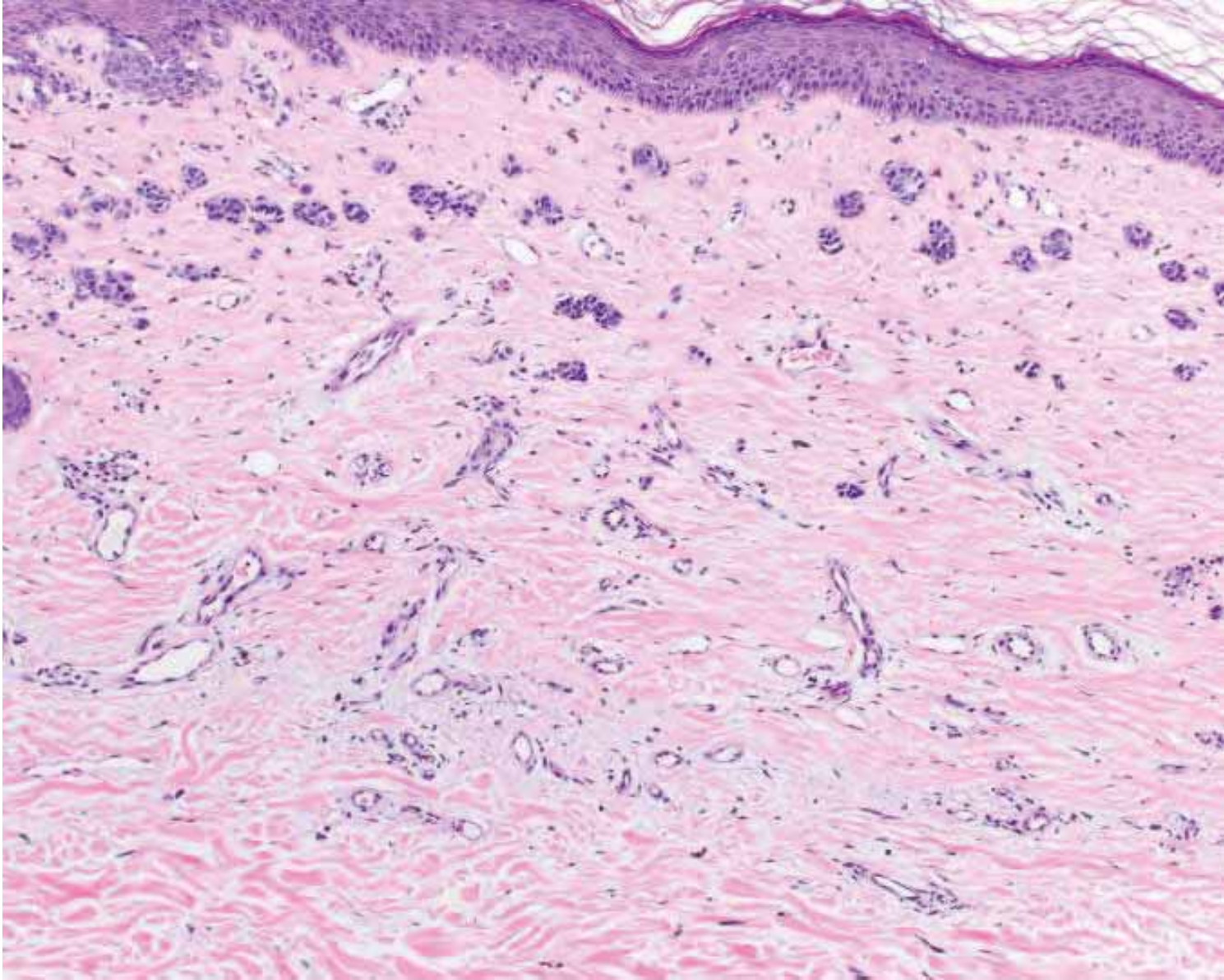
**Key words:** malignancy; melanoma; melanocytic; nevoid; parallel theque; skin; tumor.

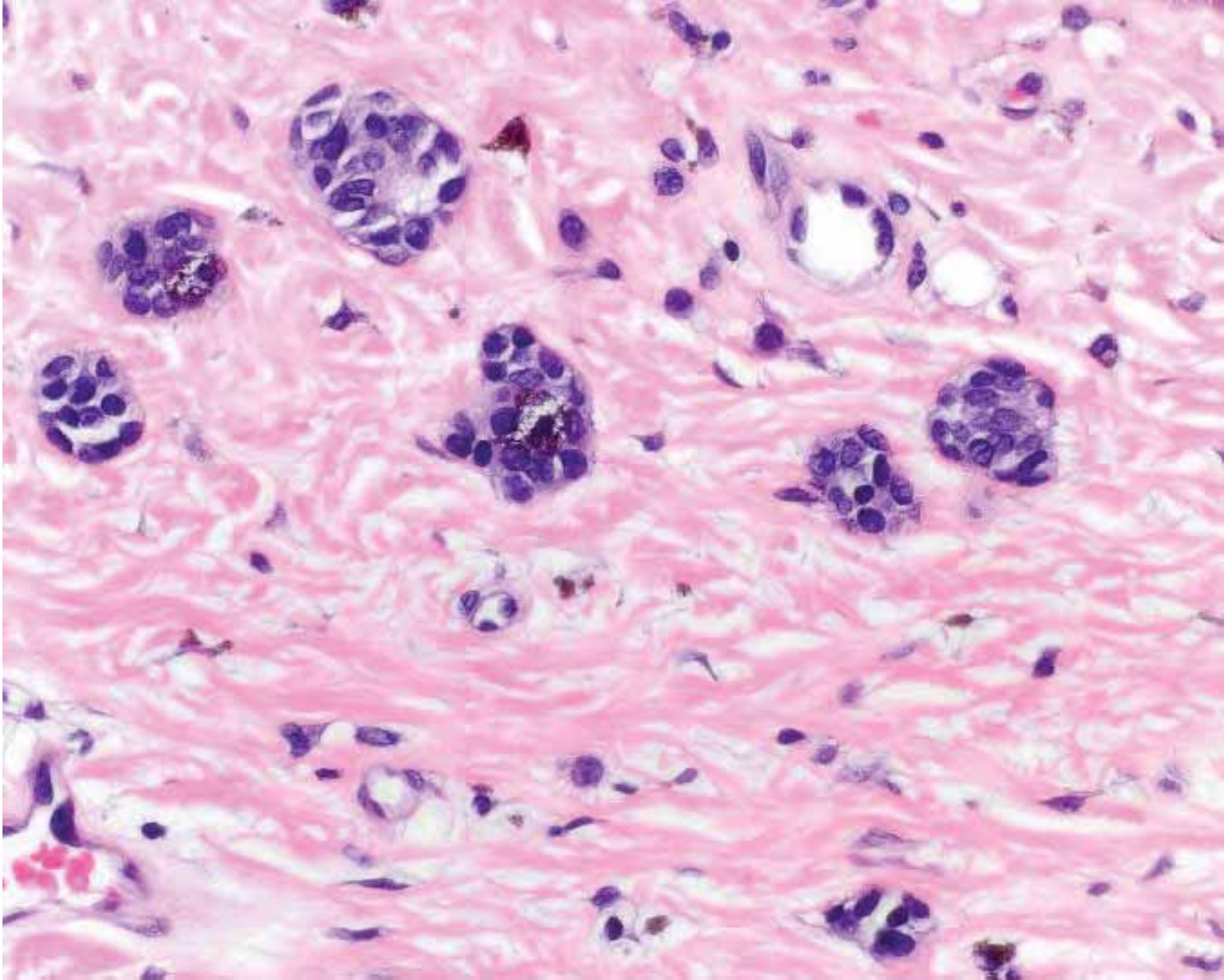
---

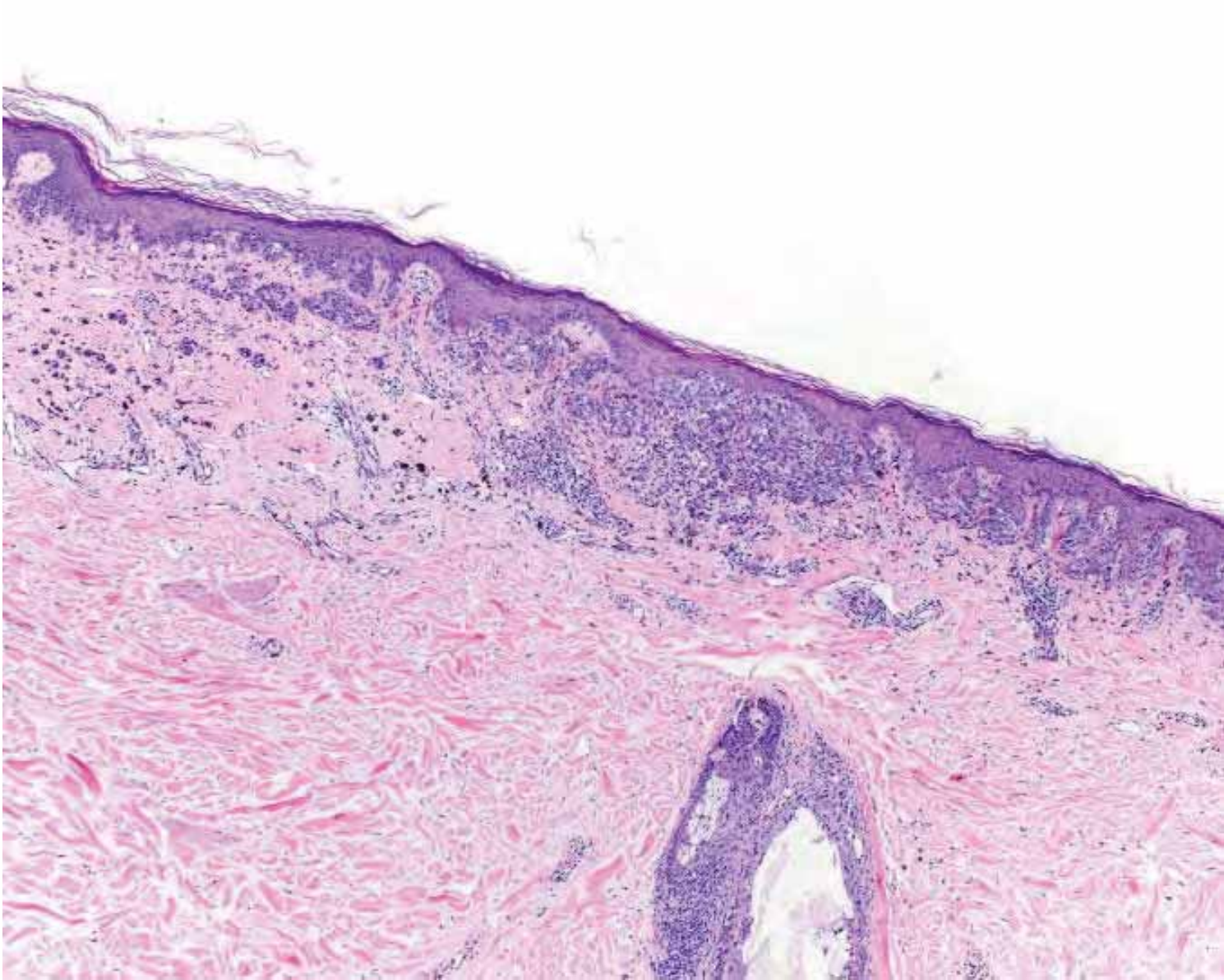


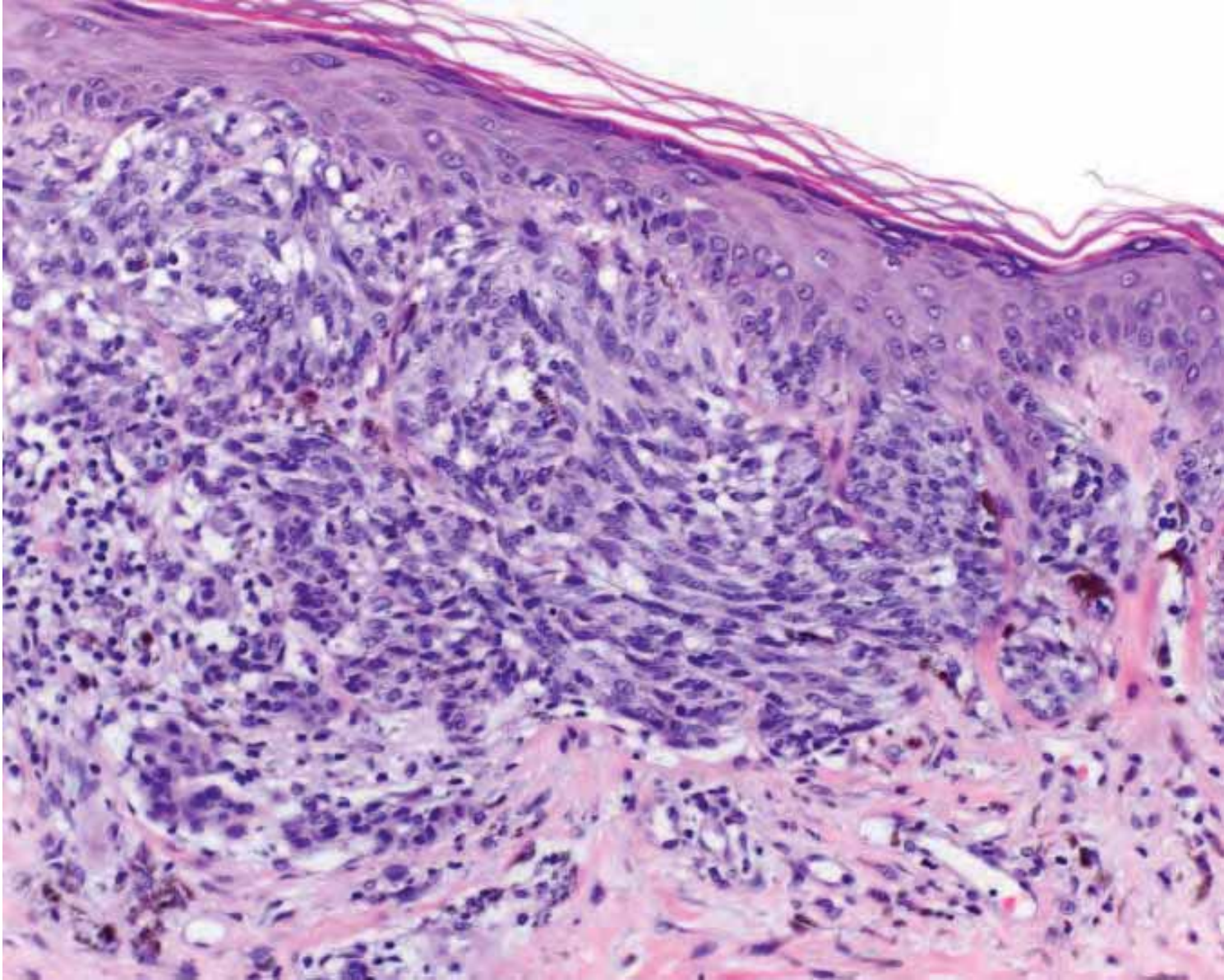


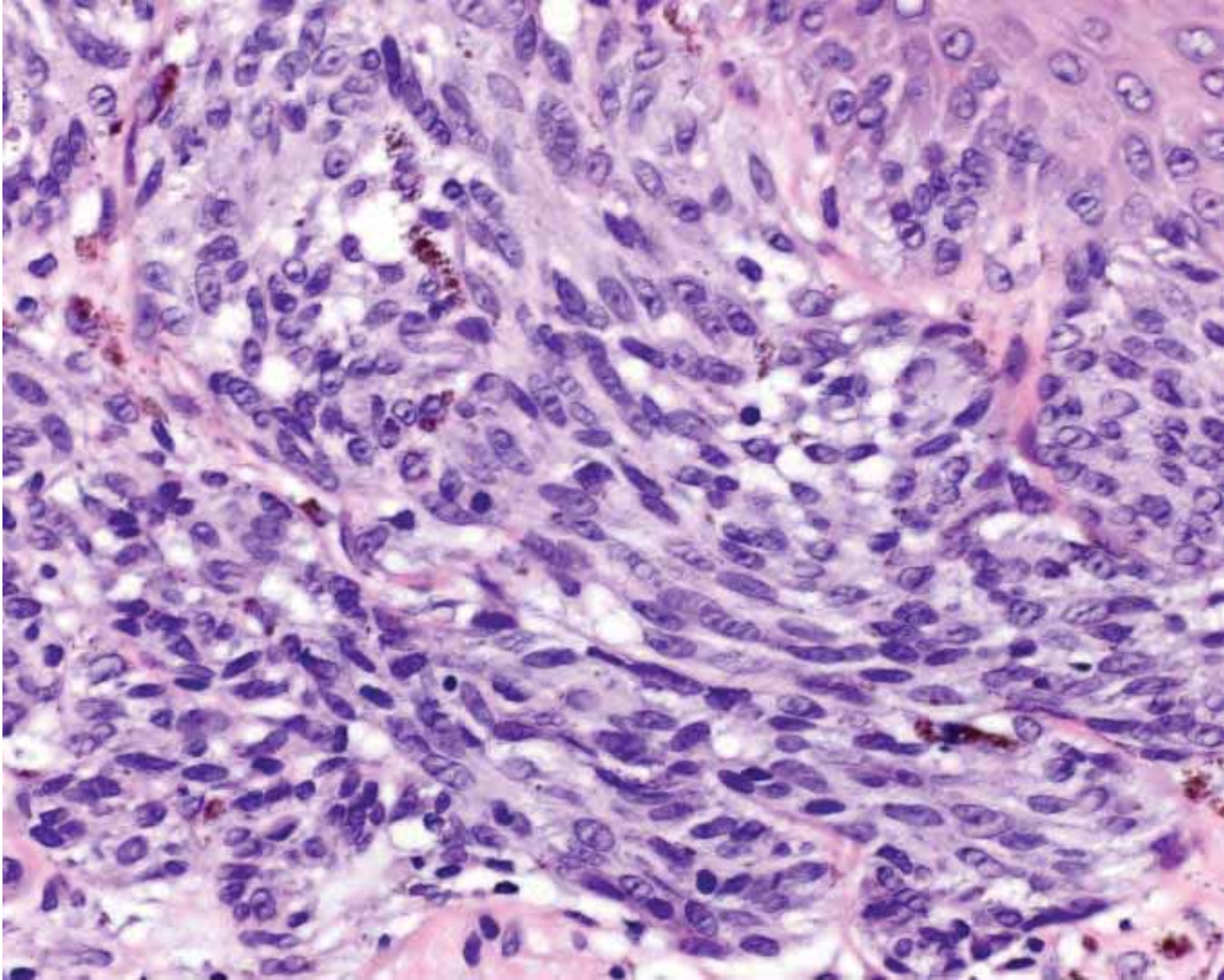


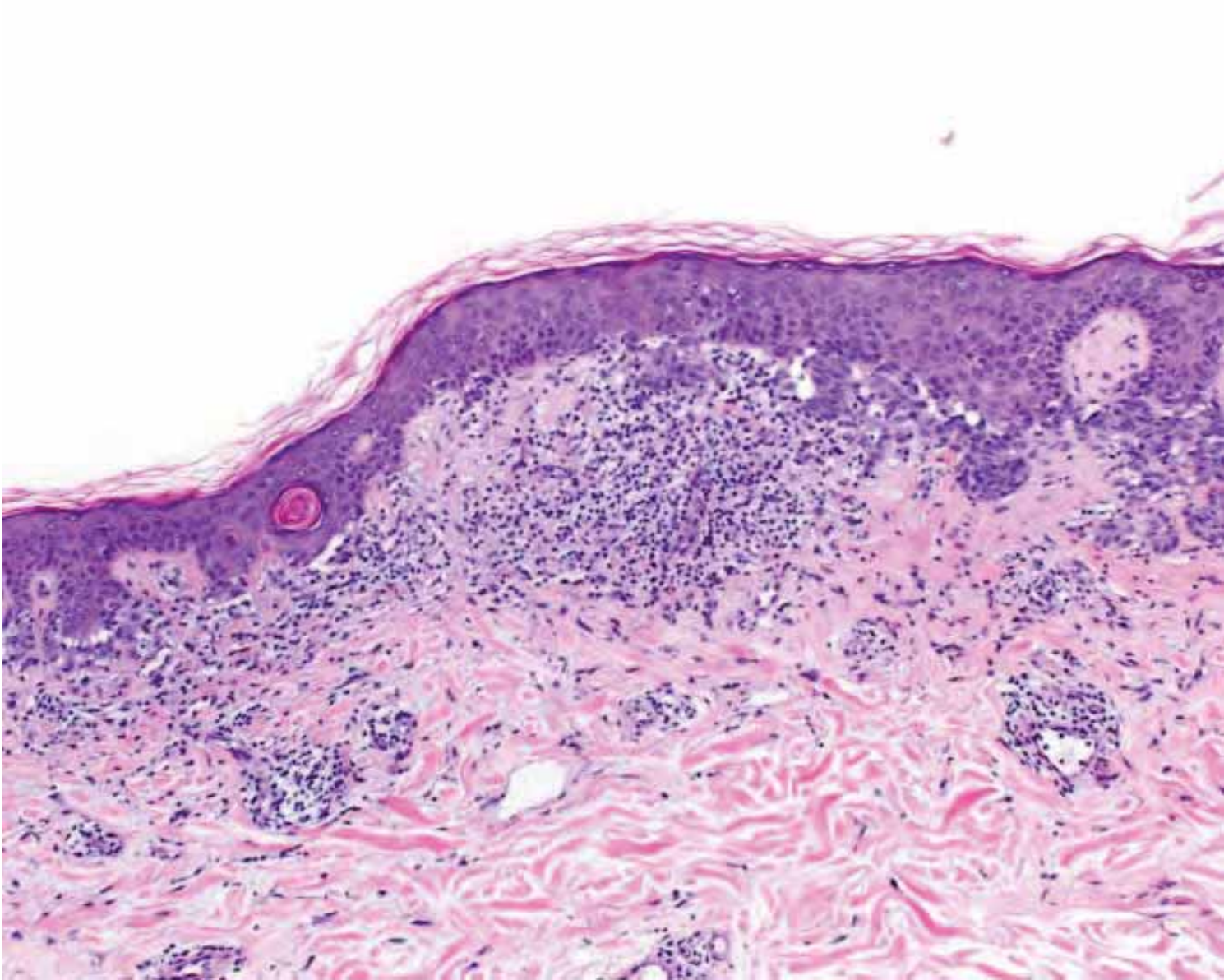


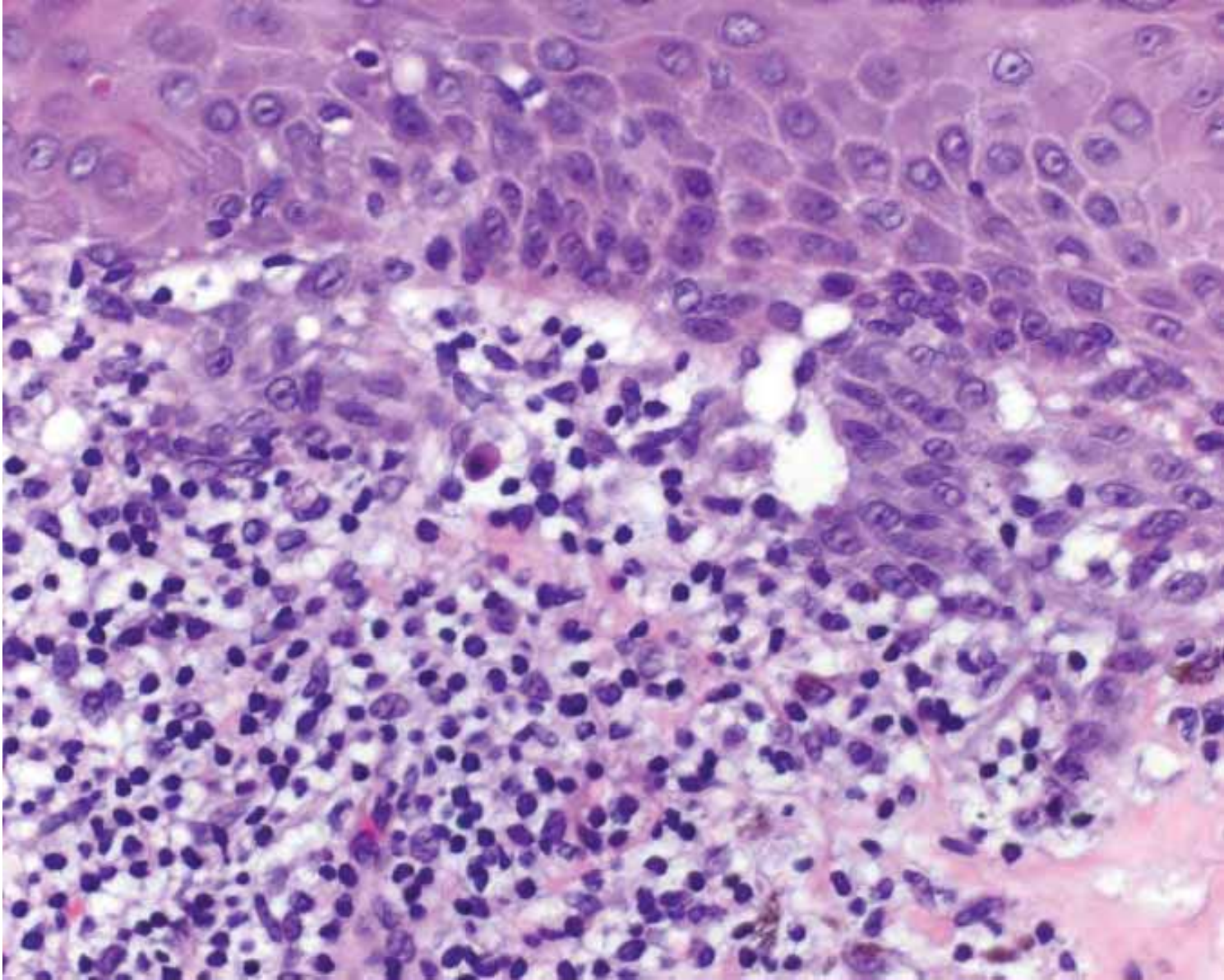


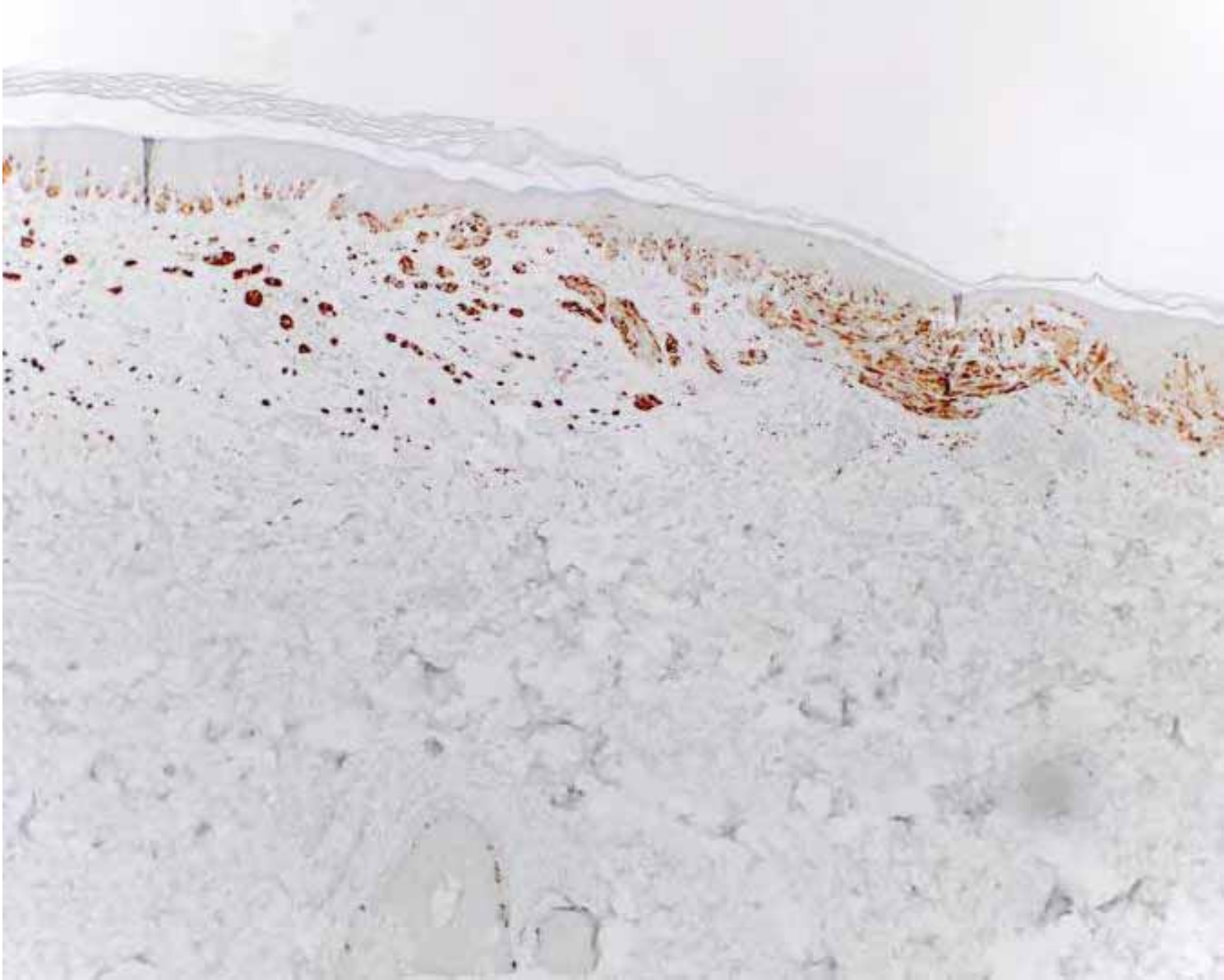


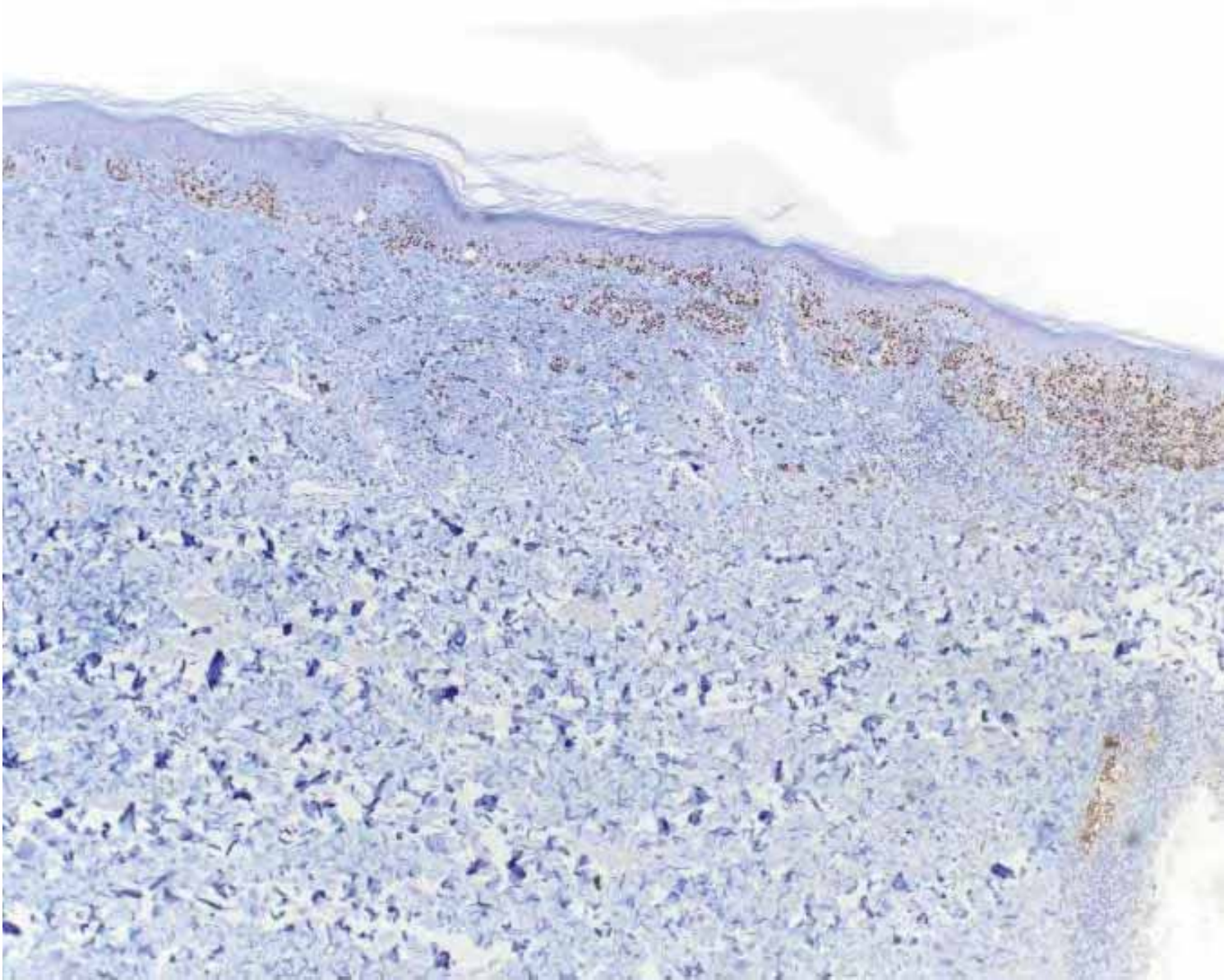


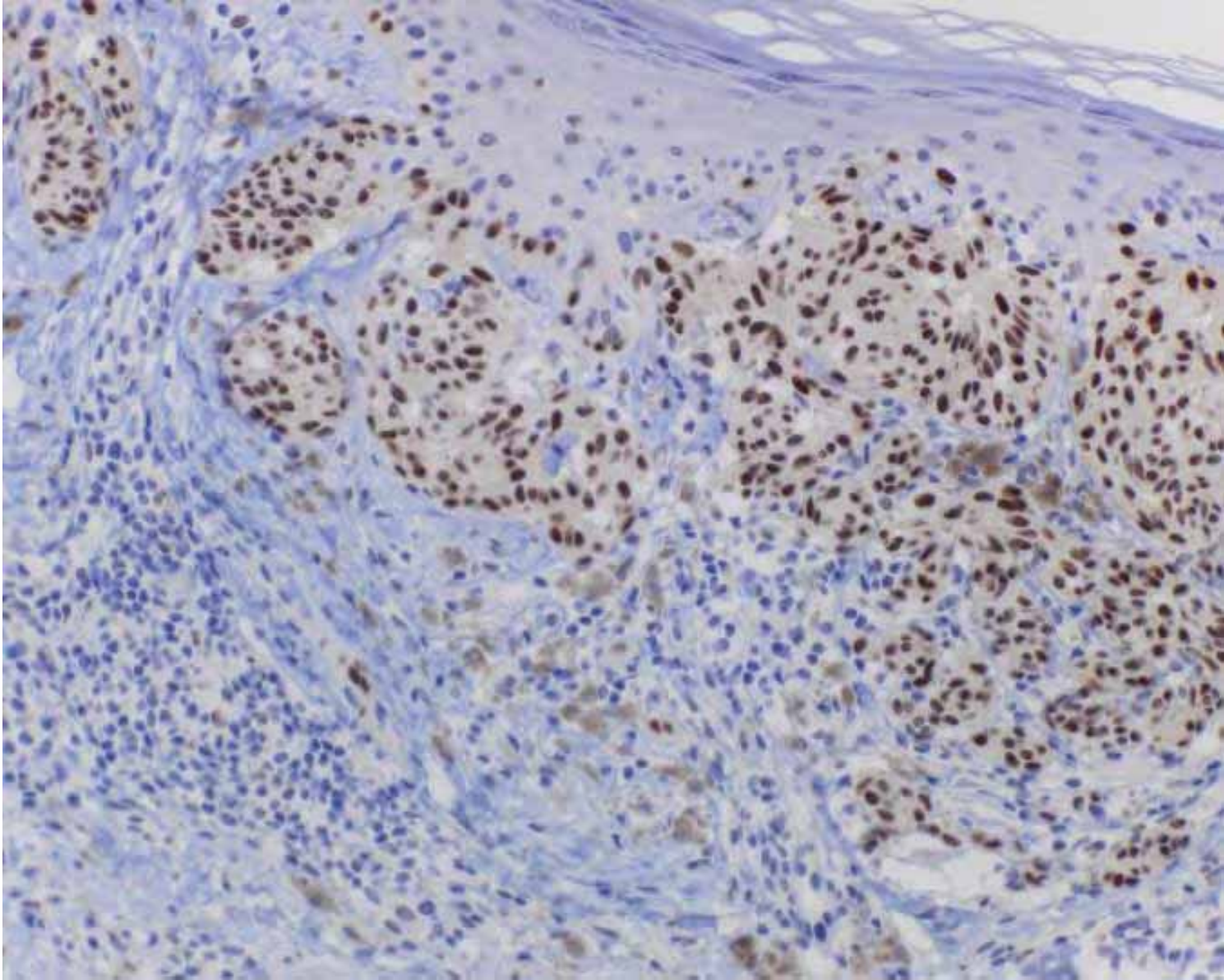








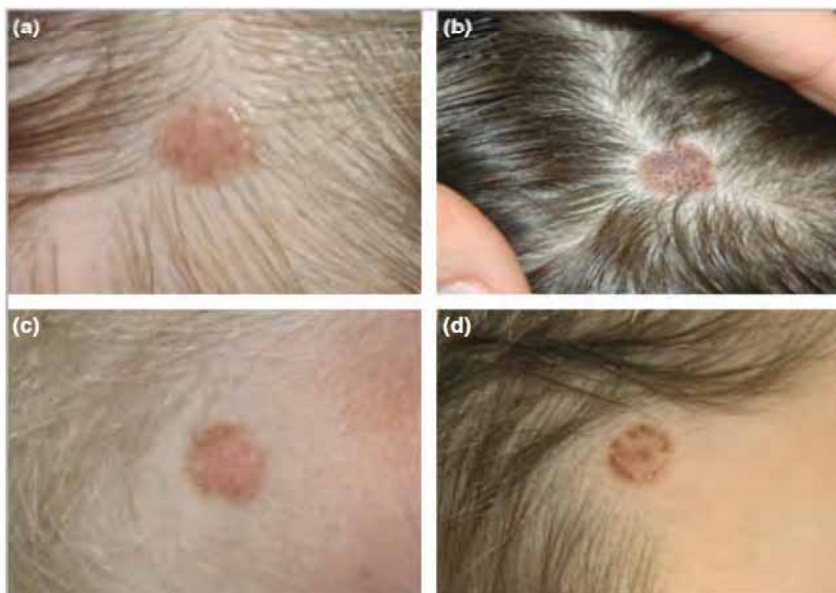




## Clinical and dermoscopic features of 88 scalp naevi in 39 children

W.J. Tcheung, J.S. Bellet, N.S. Prose, D.D. Cyr\* and K.C. Nelson

Department of Dermatology and \*Institute for Genome Sciences and Policy, Duke University Medical Center, Durham, NC 27710, U.S.A.



**Fig 3.** Common clinical patterns of scalp naevi. (a) Solid pink naevus, (b) solid brown naevus, (c) eclipse naevus with tan centre and darker outer ring, and (d) cockade naevus with darker centre, tan inner ring and darker outer ring.

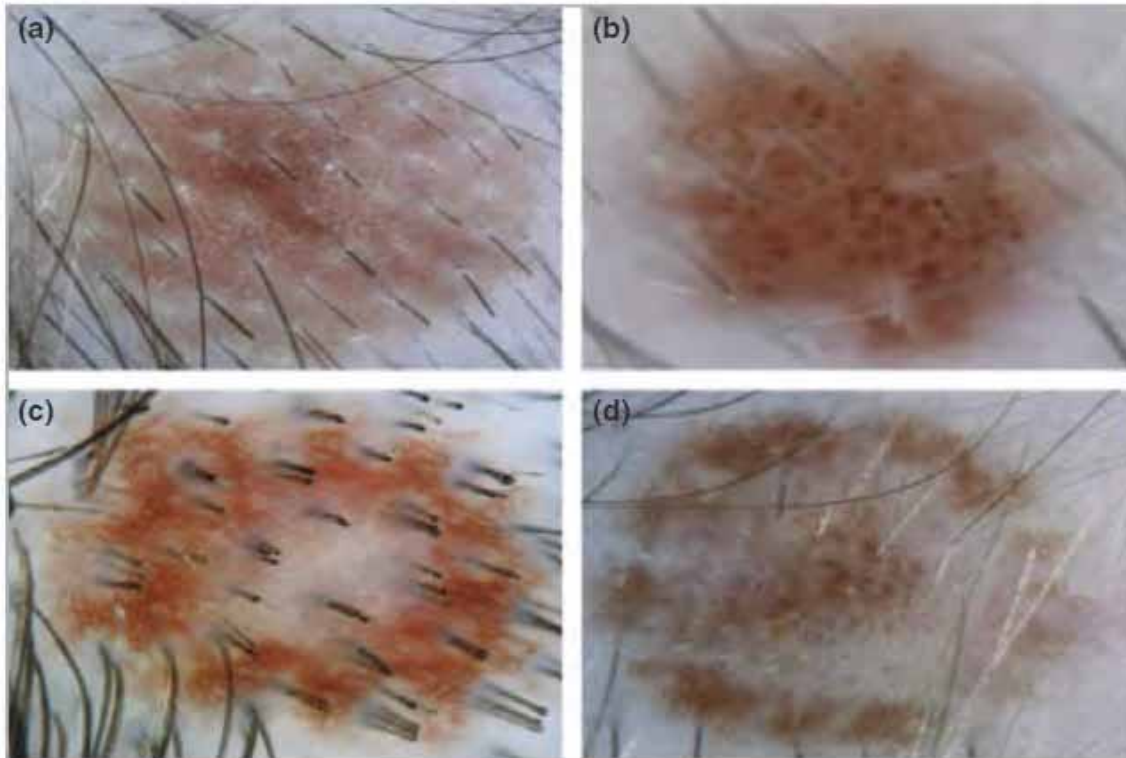


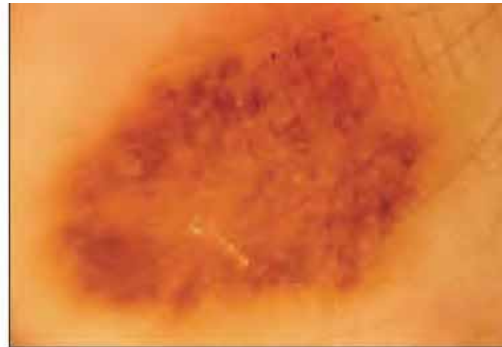
Fig 4. Common dermoscopic patterns of scalp naevi. (a) Solid pink naevus with a reticulated network, (b) solid brown naevus with a globular pattern, (c) eclipse naevus with a light brown homogeneous centre and a darker, reticulated outer ring, and (d) cockade naevus with a target-like appearance with a darker, globular centre, tan homogeneous inner ring and darker reticulated outer ring.

> Arch Dermatol. 2009 Nov;145(11):1334-6. doi: 10.1001/archdermatol.2009.282.

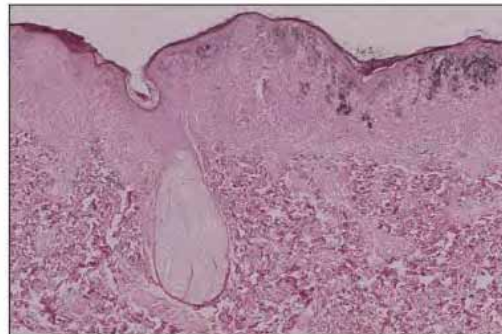
## No biopsy needed for eclipse and cockade nevi found on the scalps of children

María C Kessides, Katherine B Puttgen, Bernard A Cohen

PMID: 19917973 DOI: 10.1001/archdermatol.2009.282



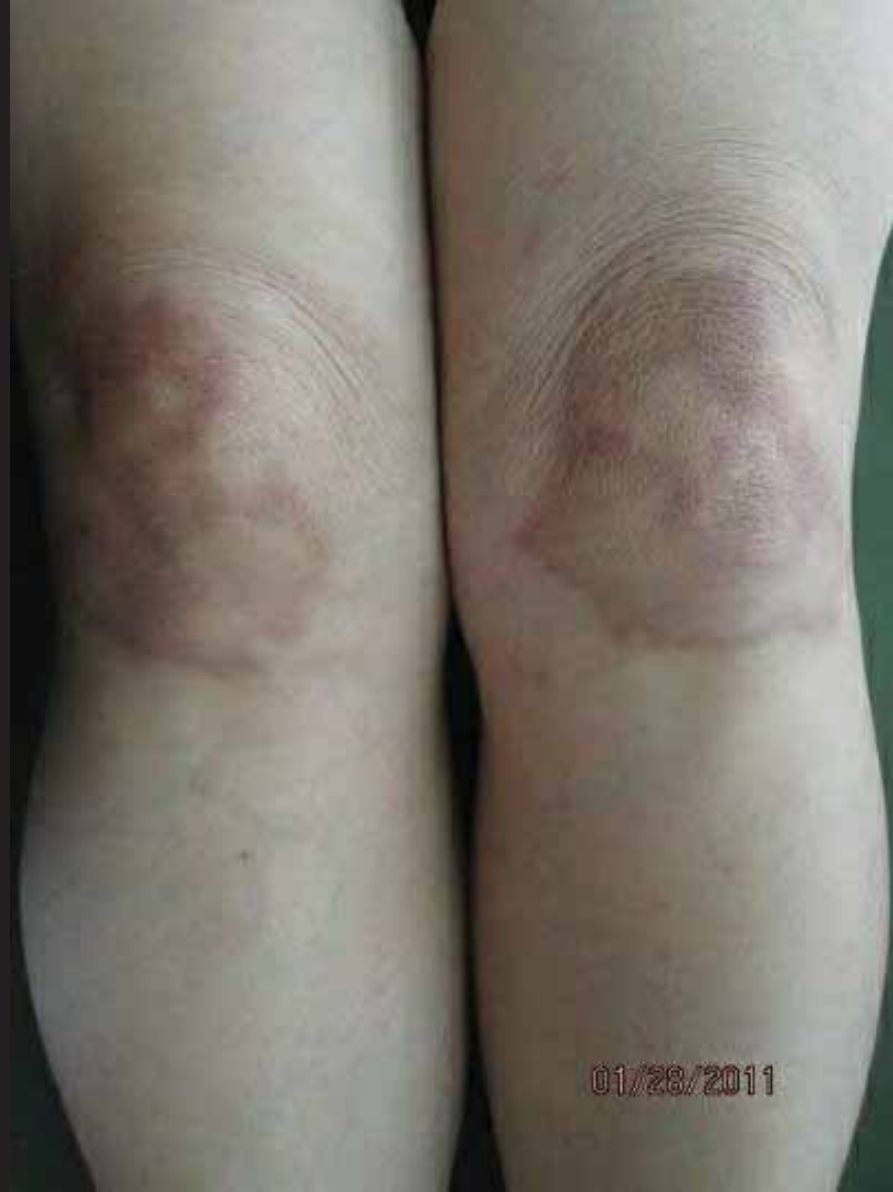**Figure 5.** Dermoscopic image of an eclipse nevus. The central portion does not have a pigmented network, whereas the brown rim exhibits a regular pigmented network. Each scale mark represents 0.5 mm.

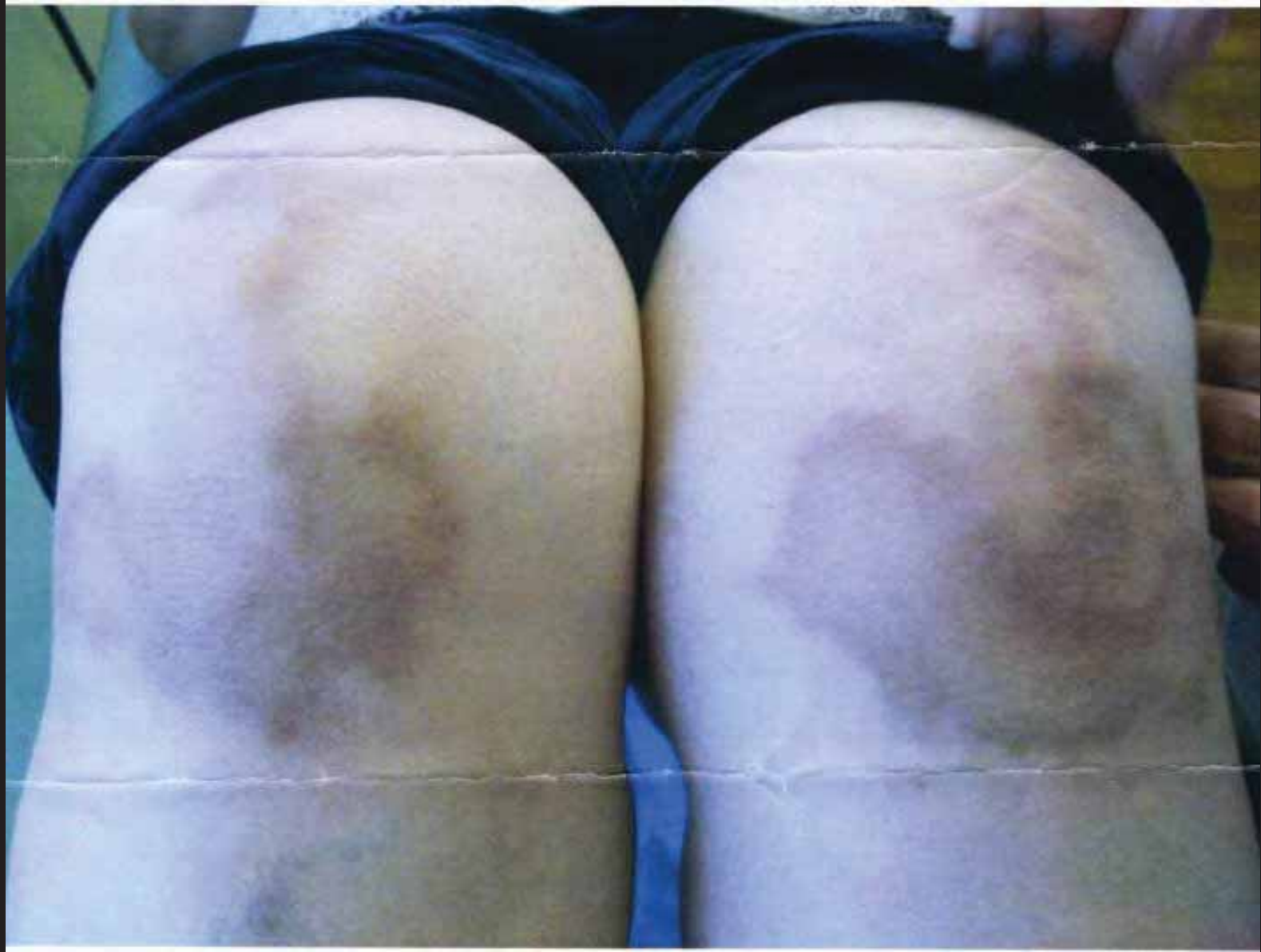

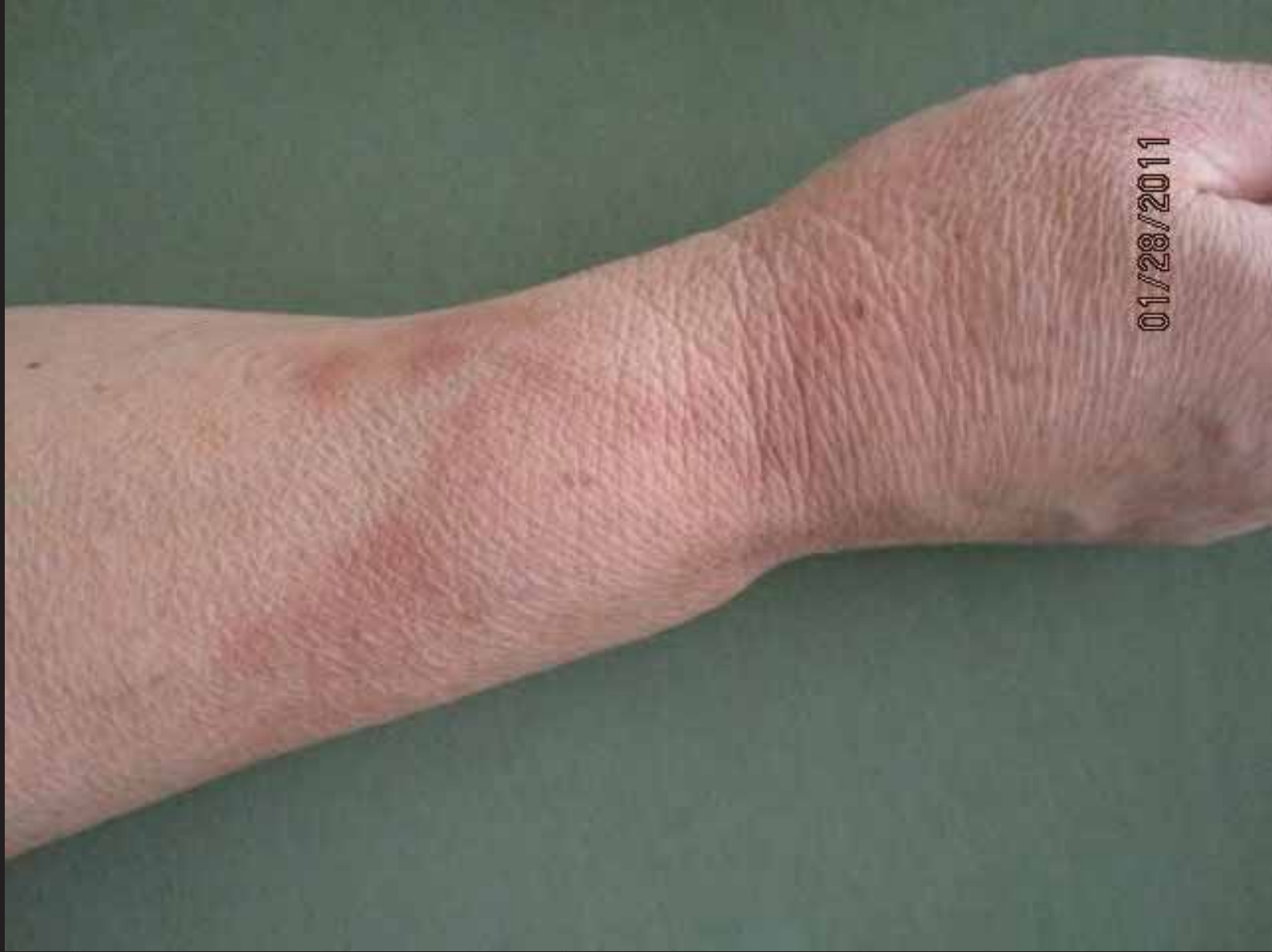**Figure 6.** Eclipse nevus specimen demonstrating melanin deposition on the junctional shoulder (hematoxylin-eosin, original magnification  $\times 10$ ).

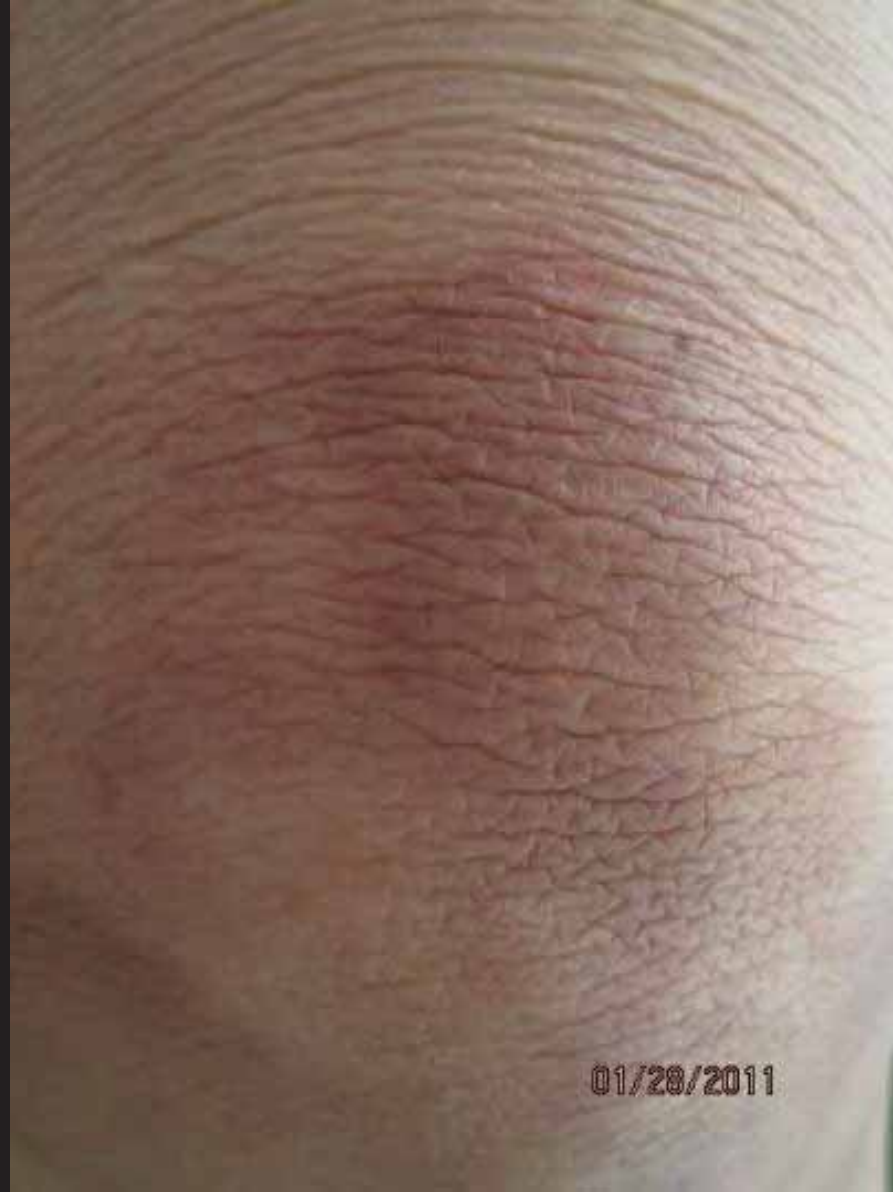# Contusiform multinucleate cell dermopathy

A new disease? An end-stage of  
several diseases?

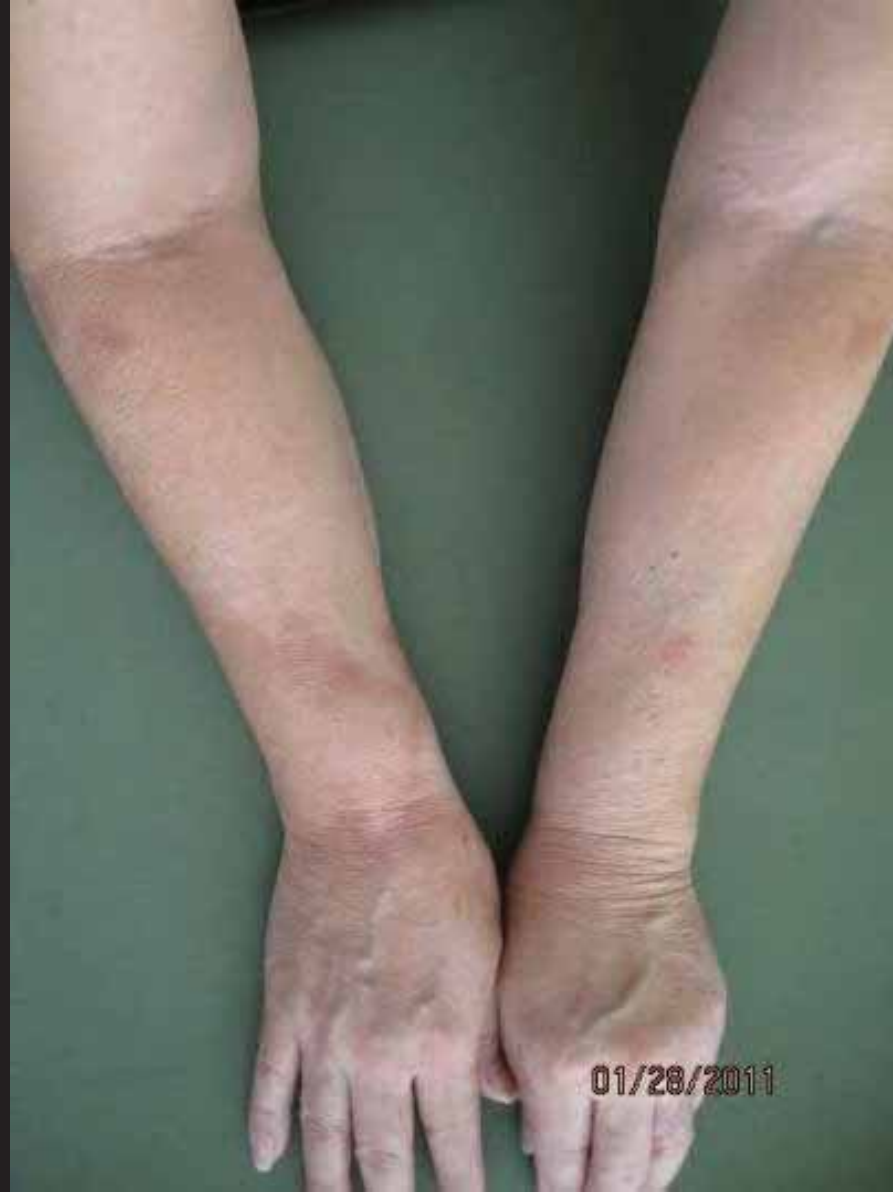


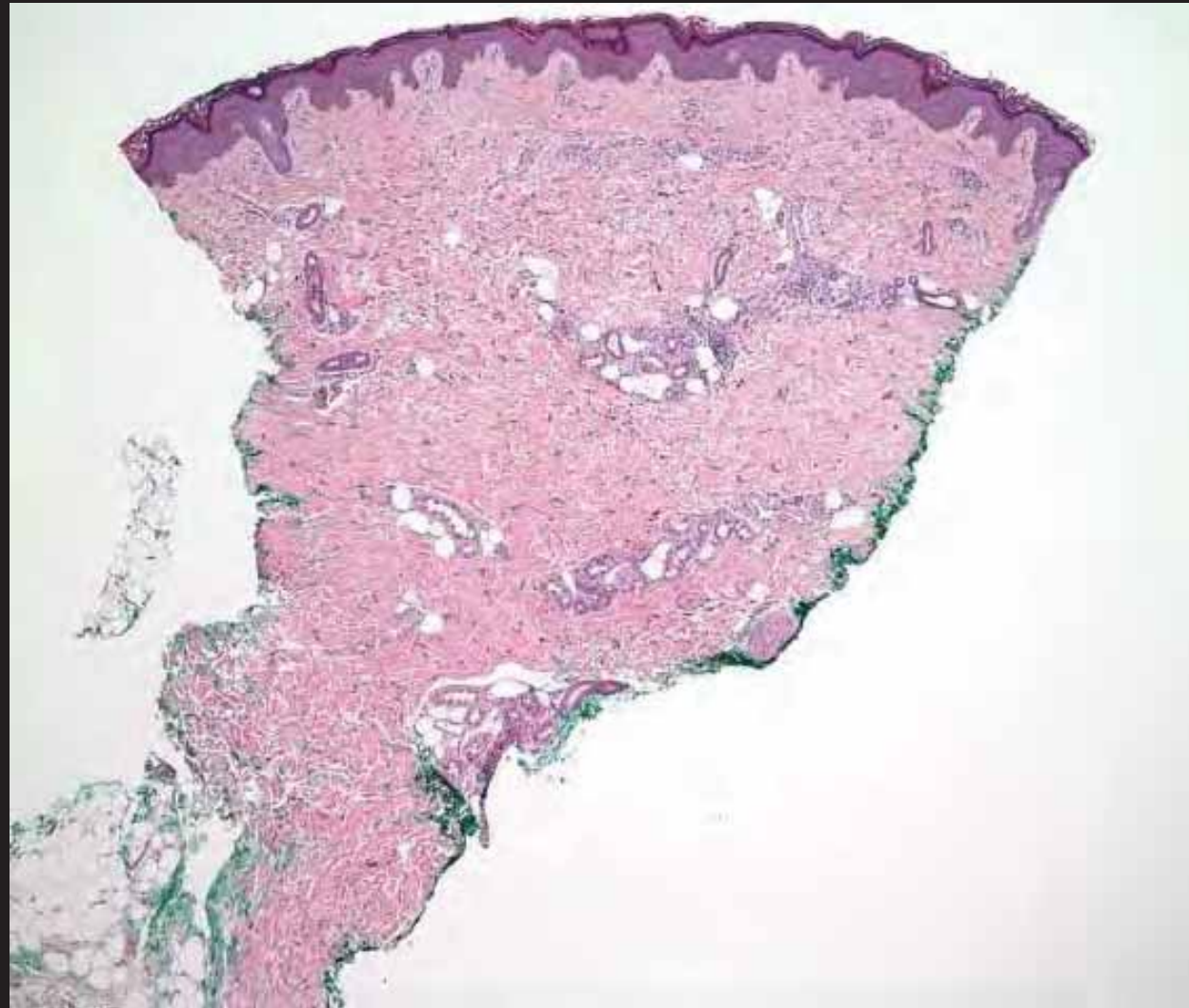
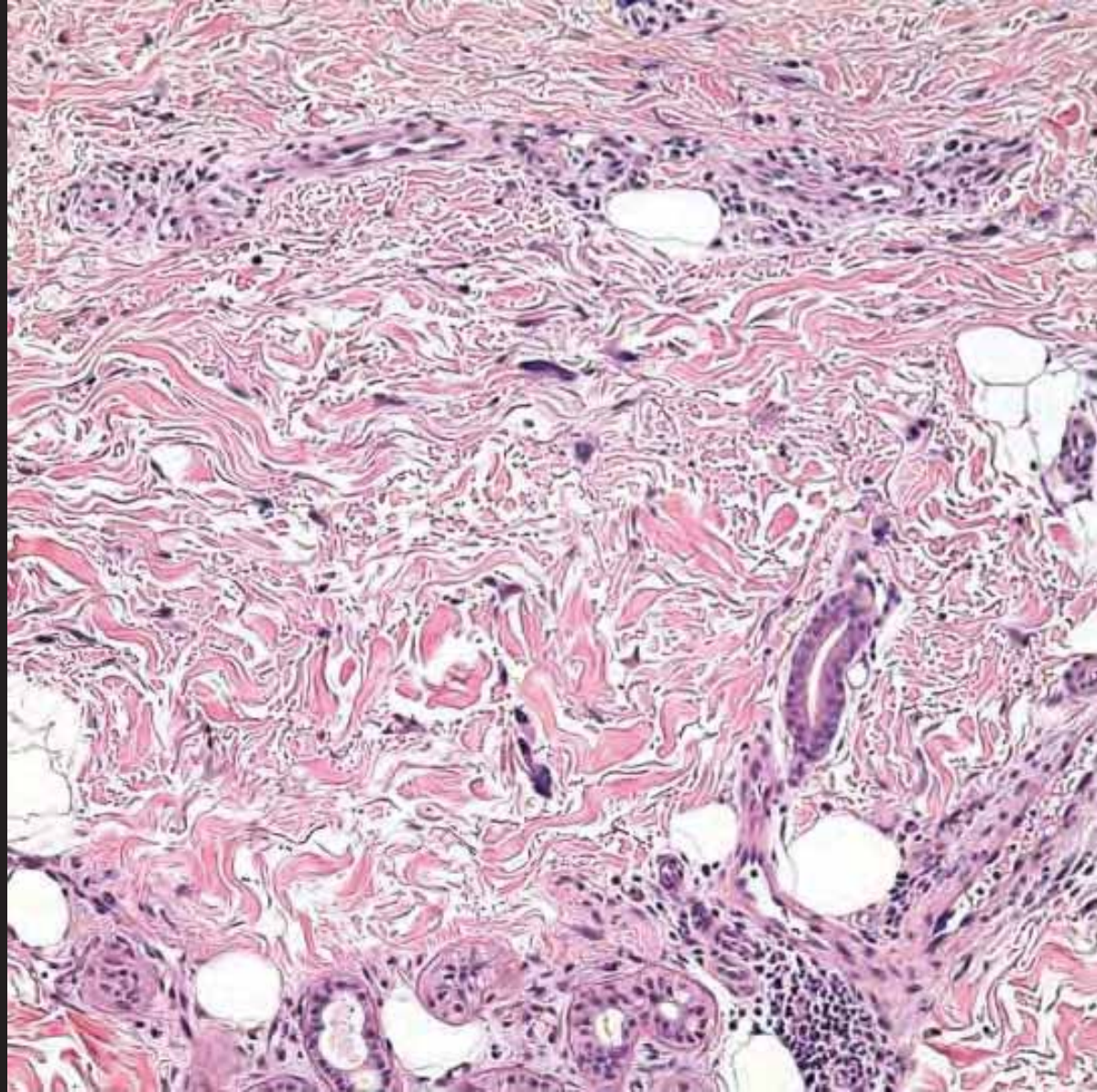


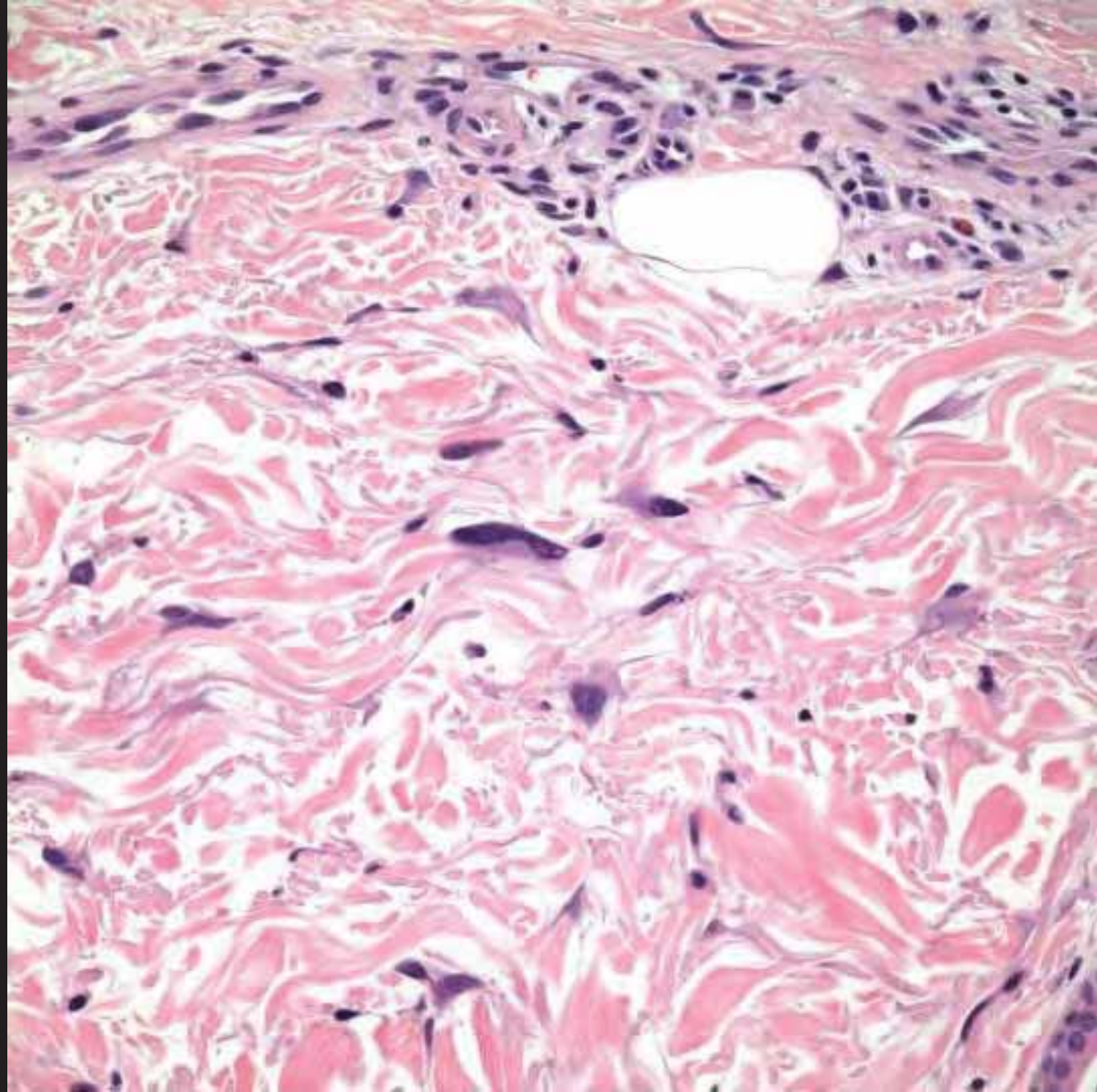


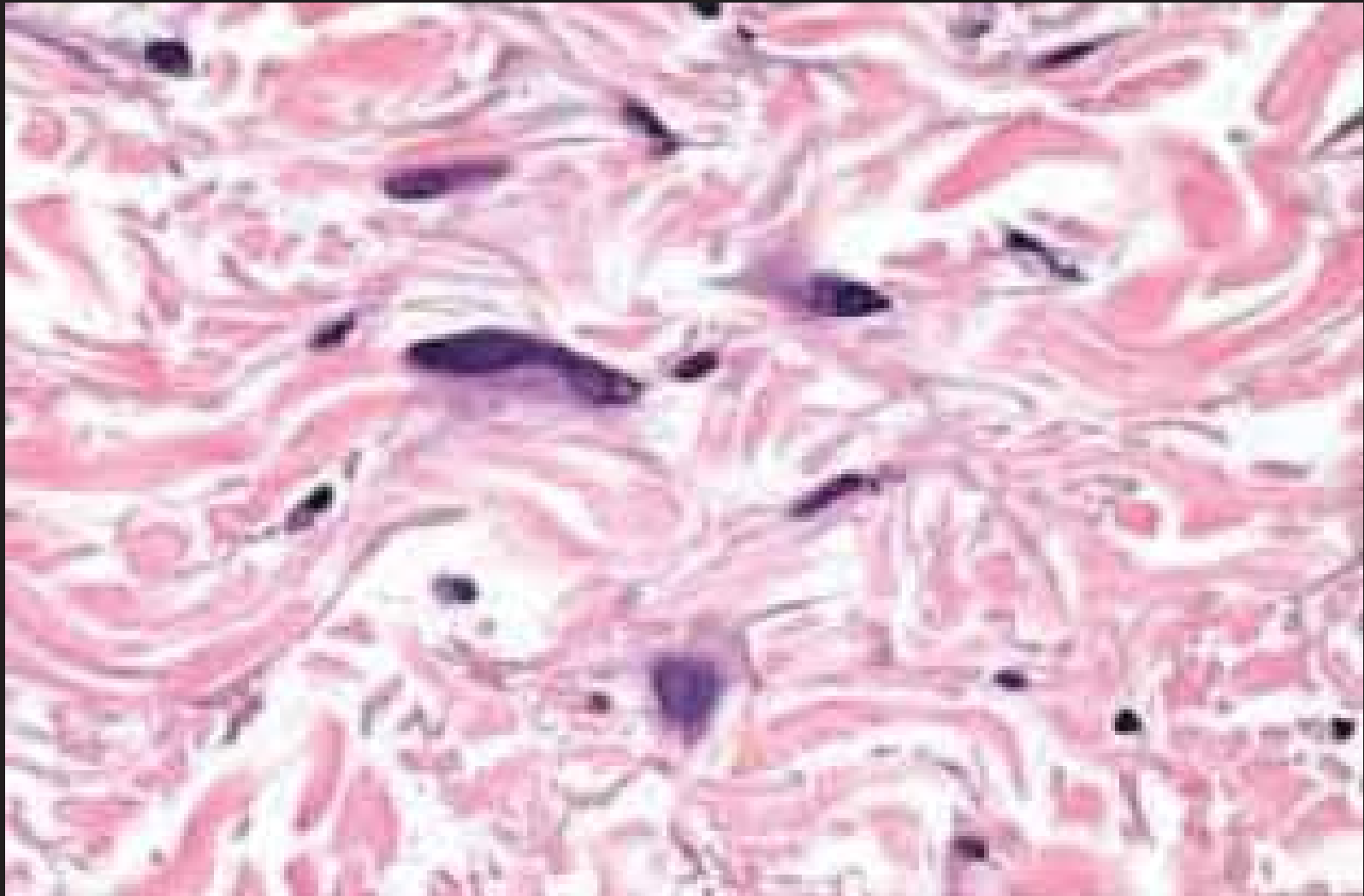
01/28/2011

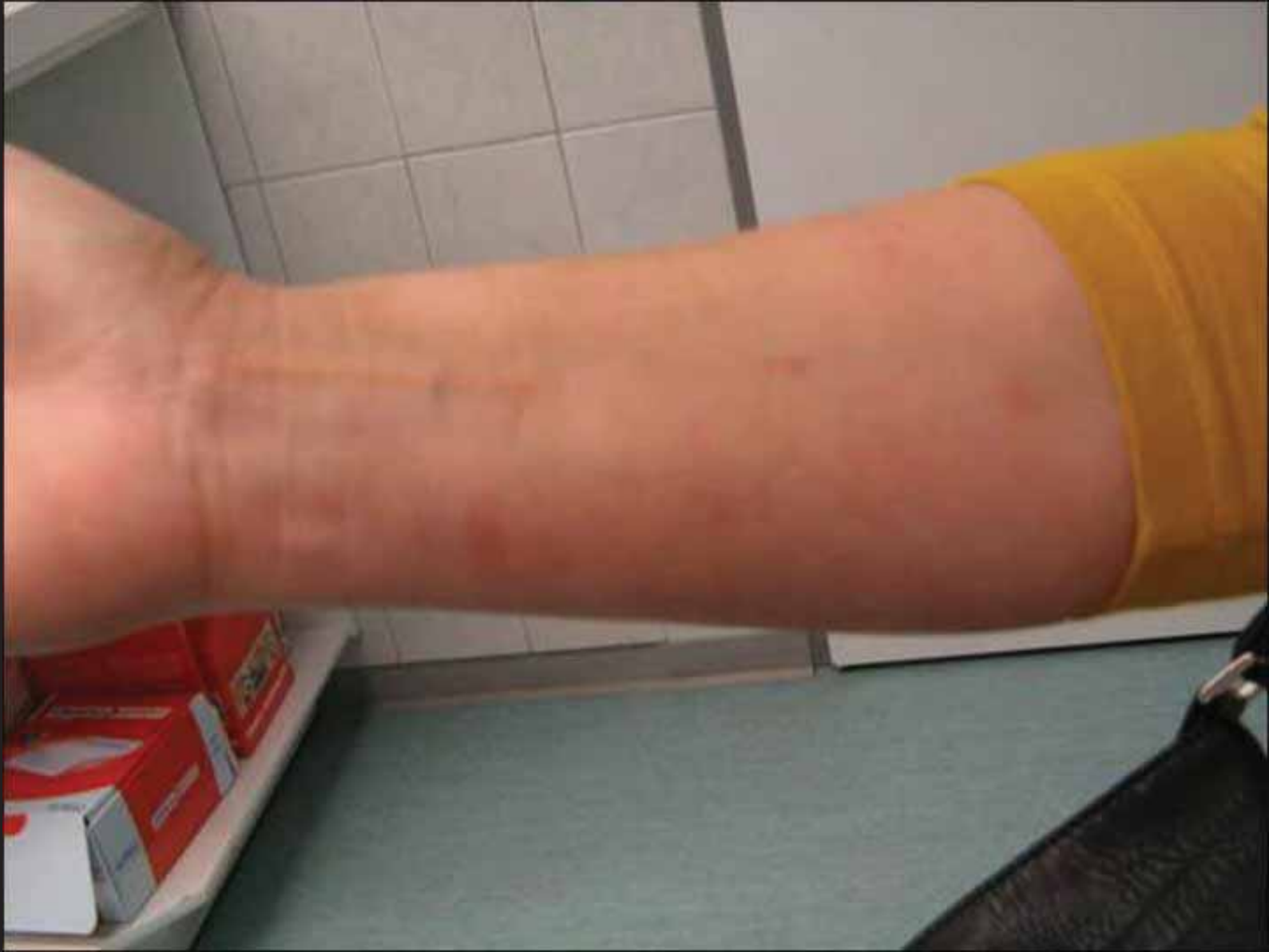


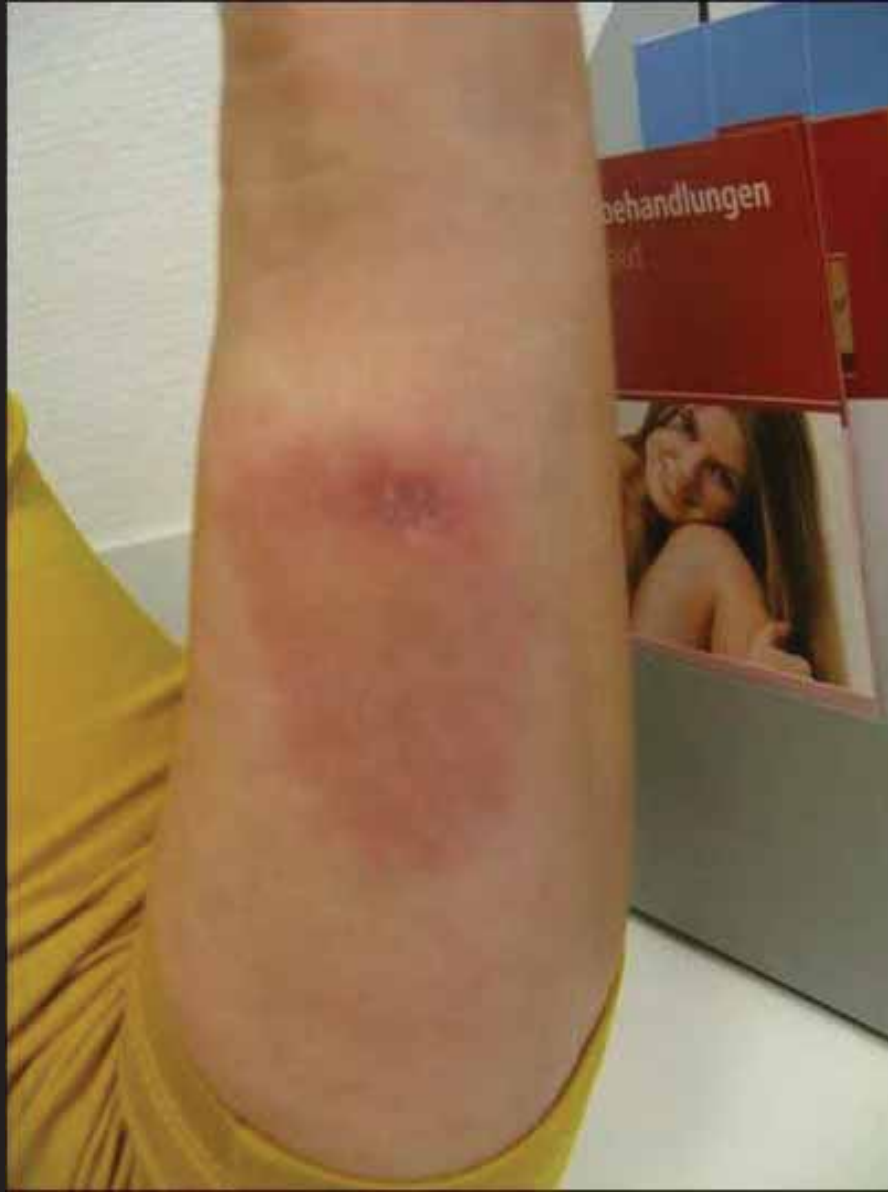
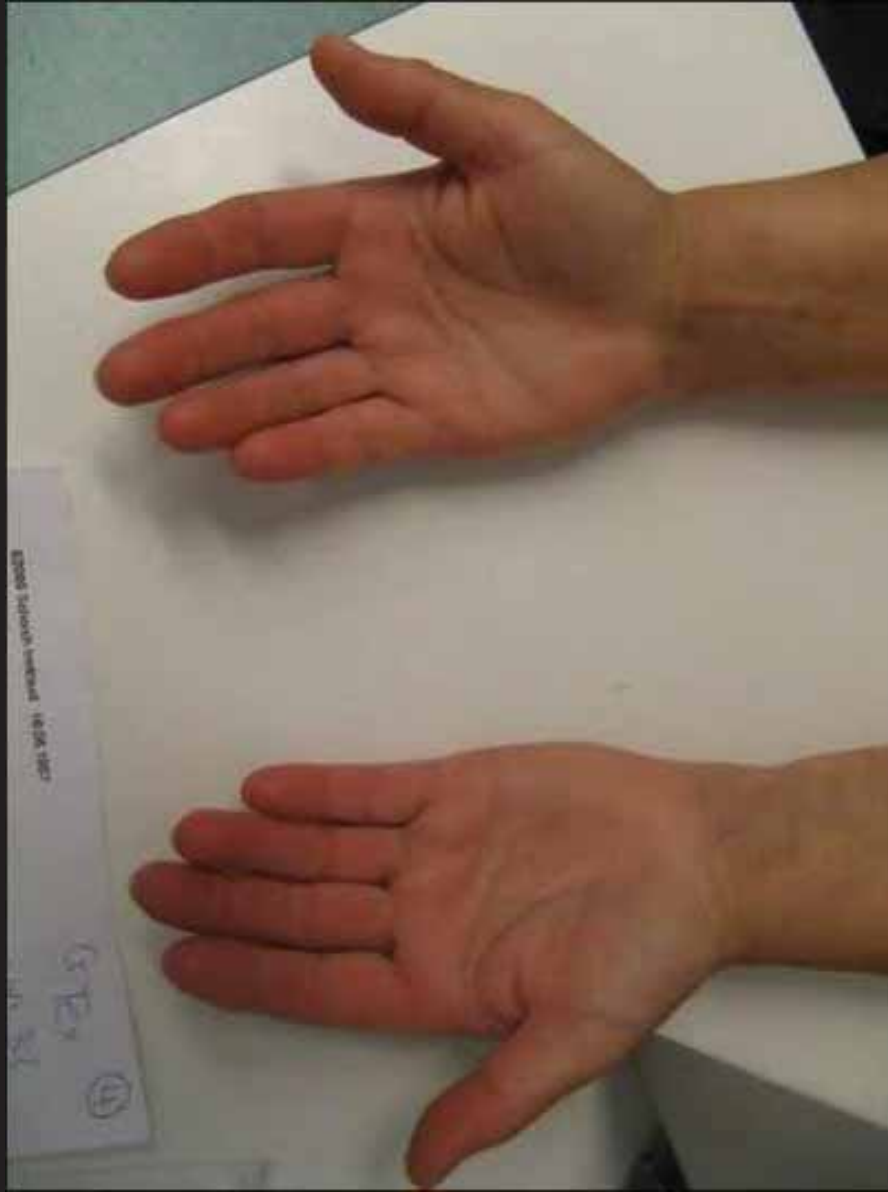




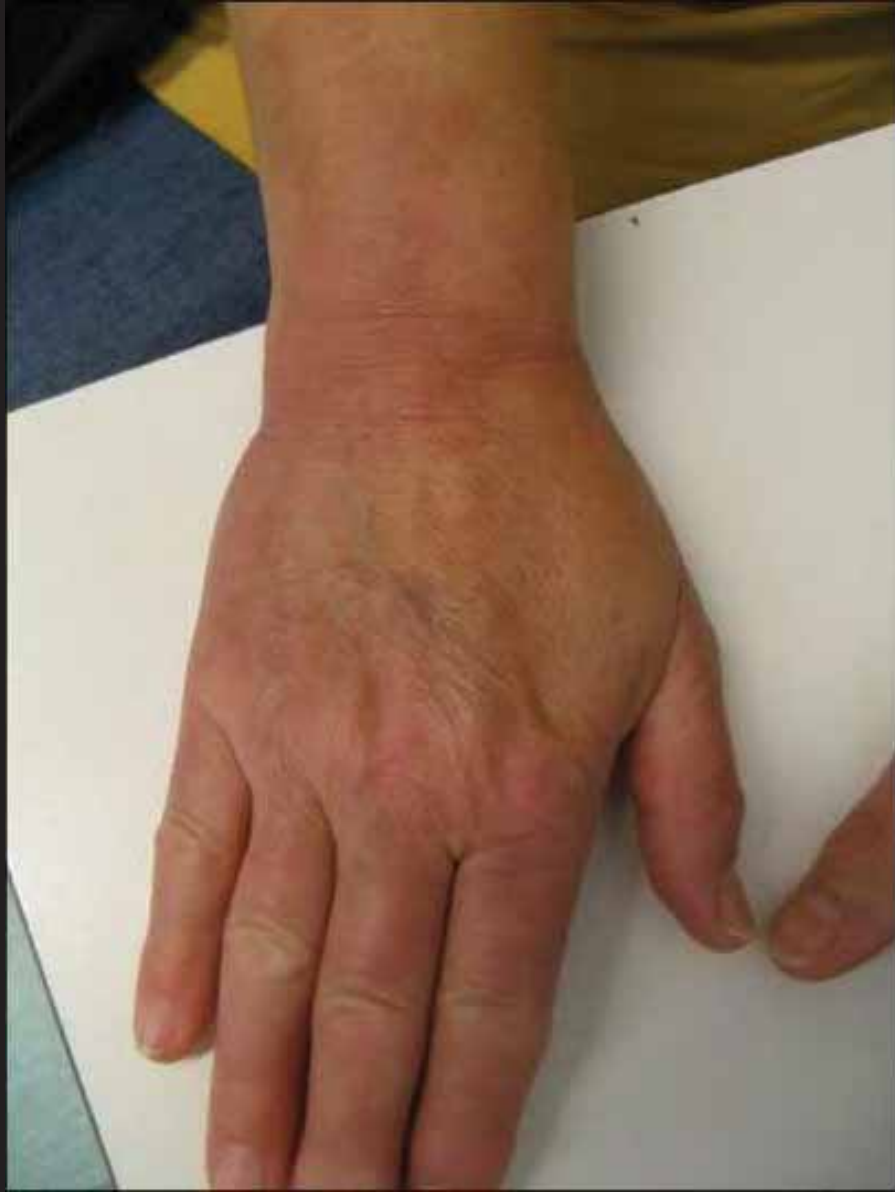


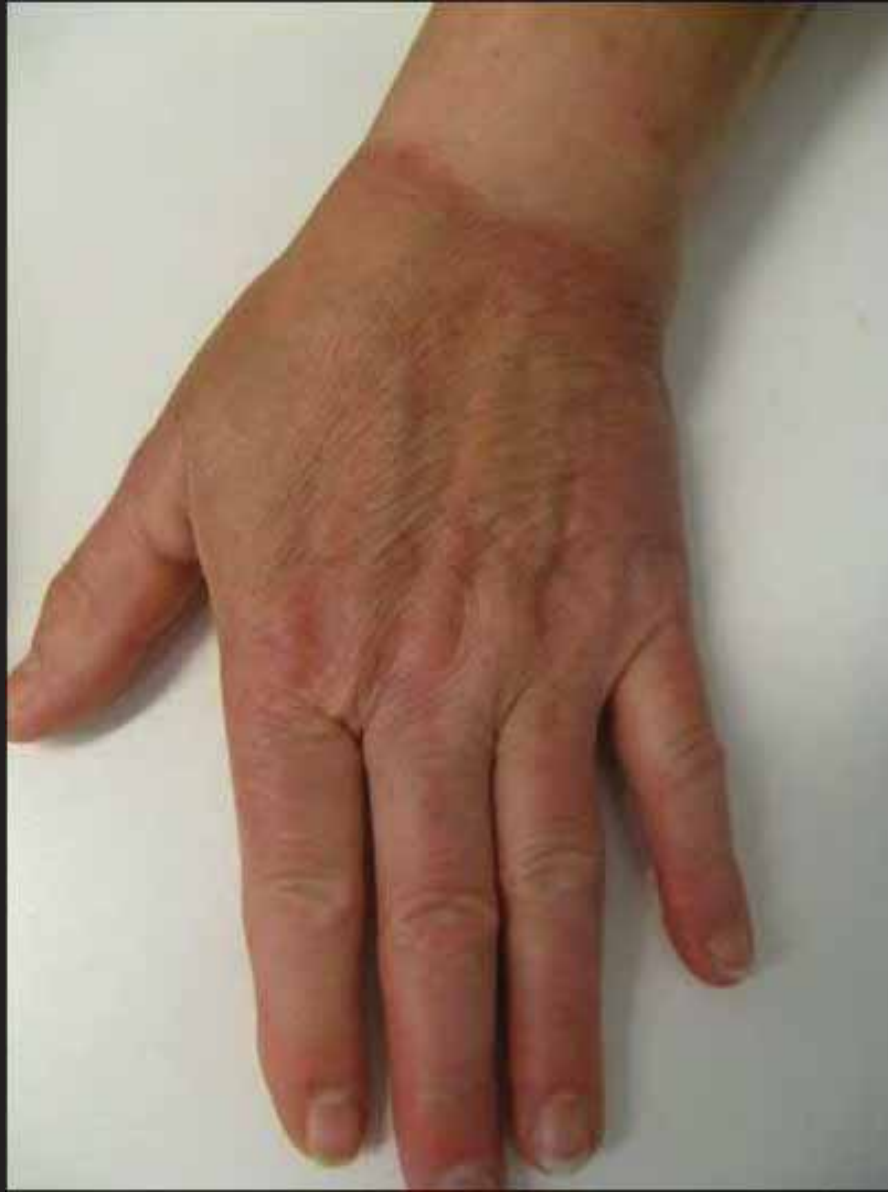


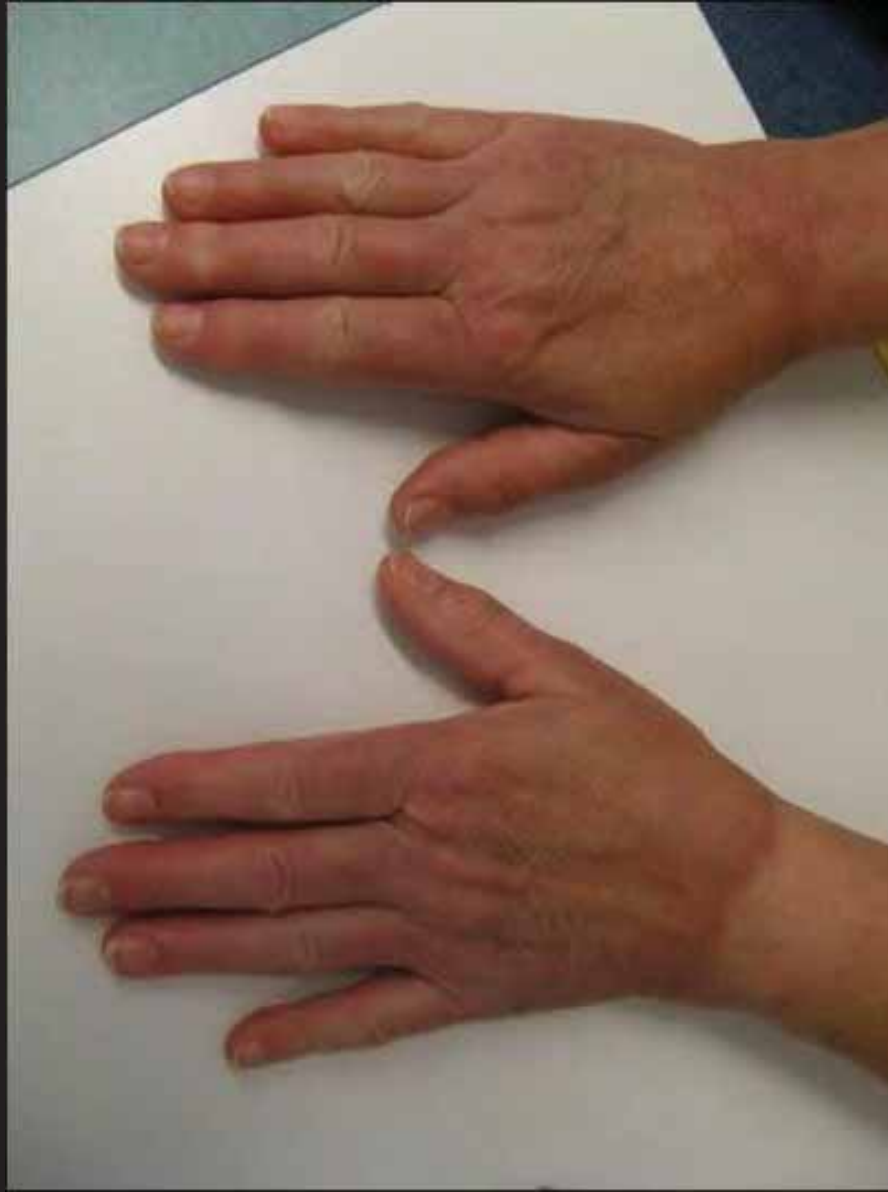

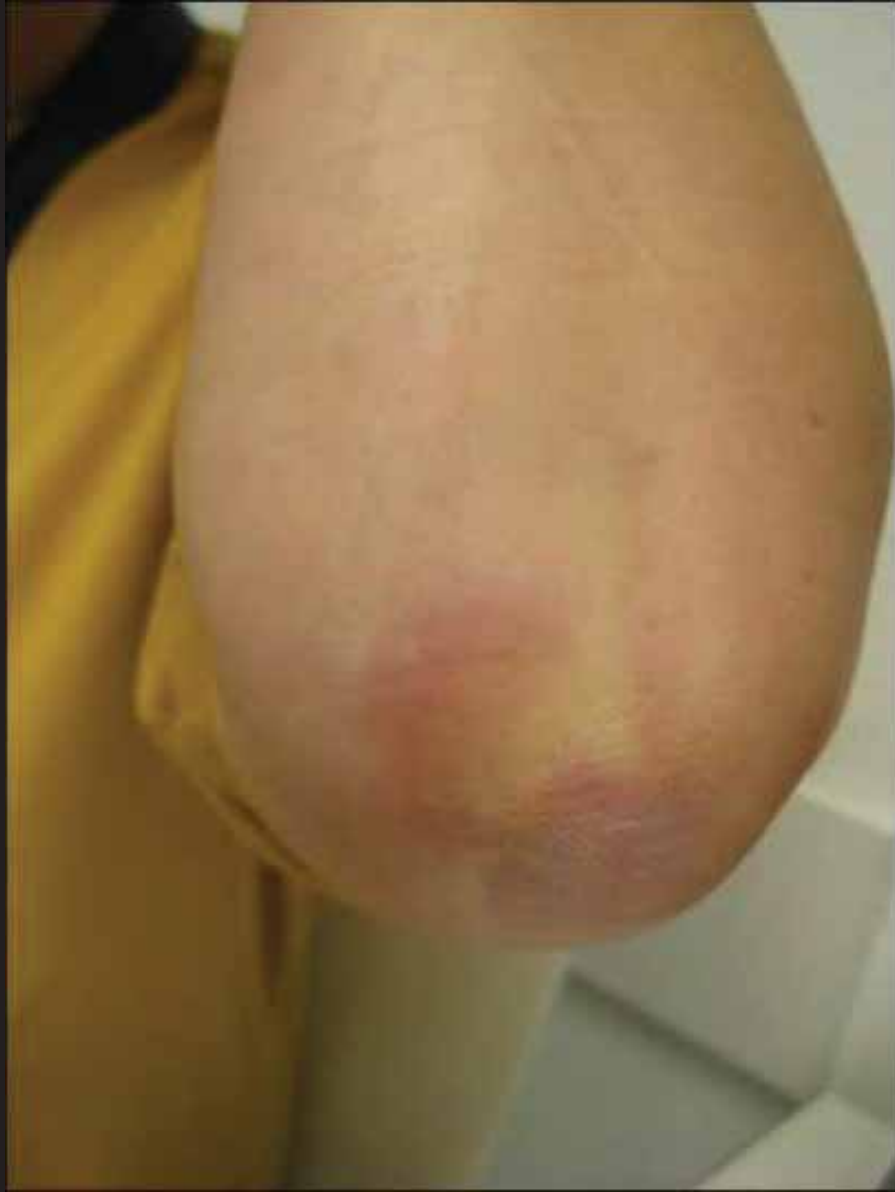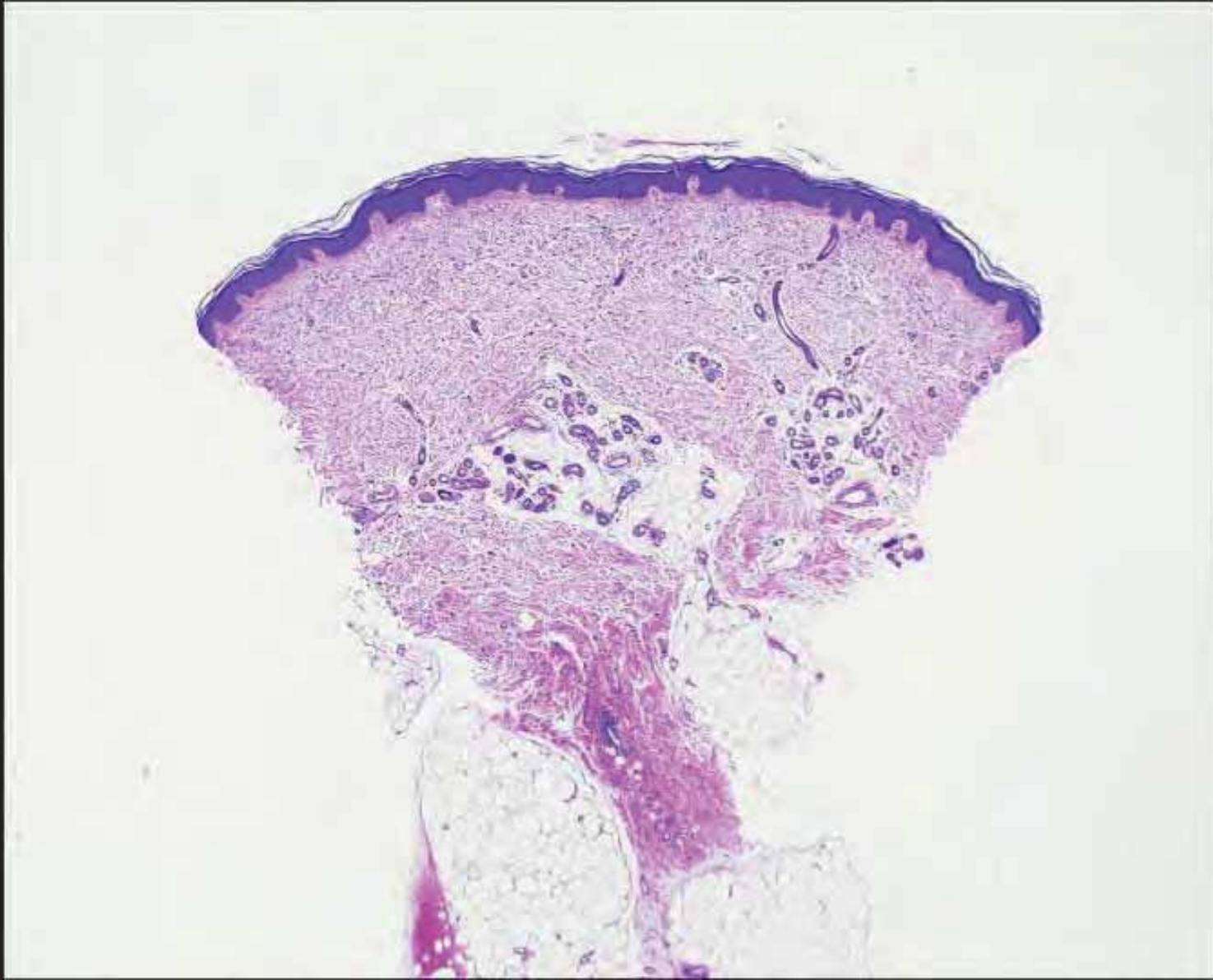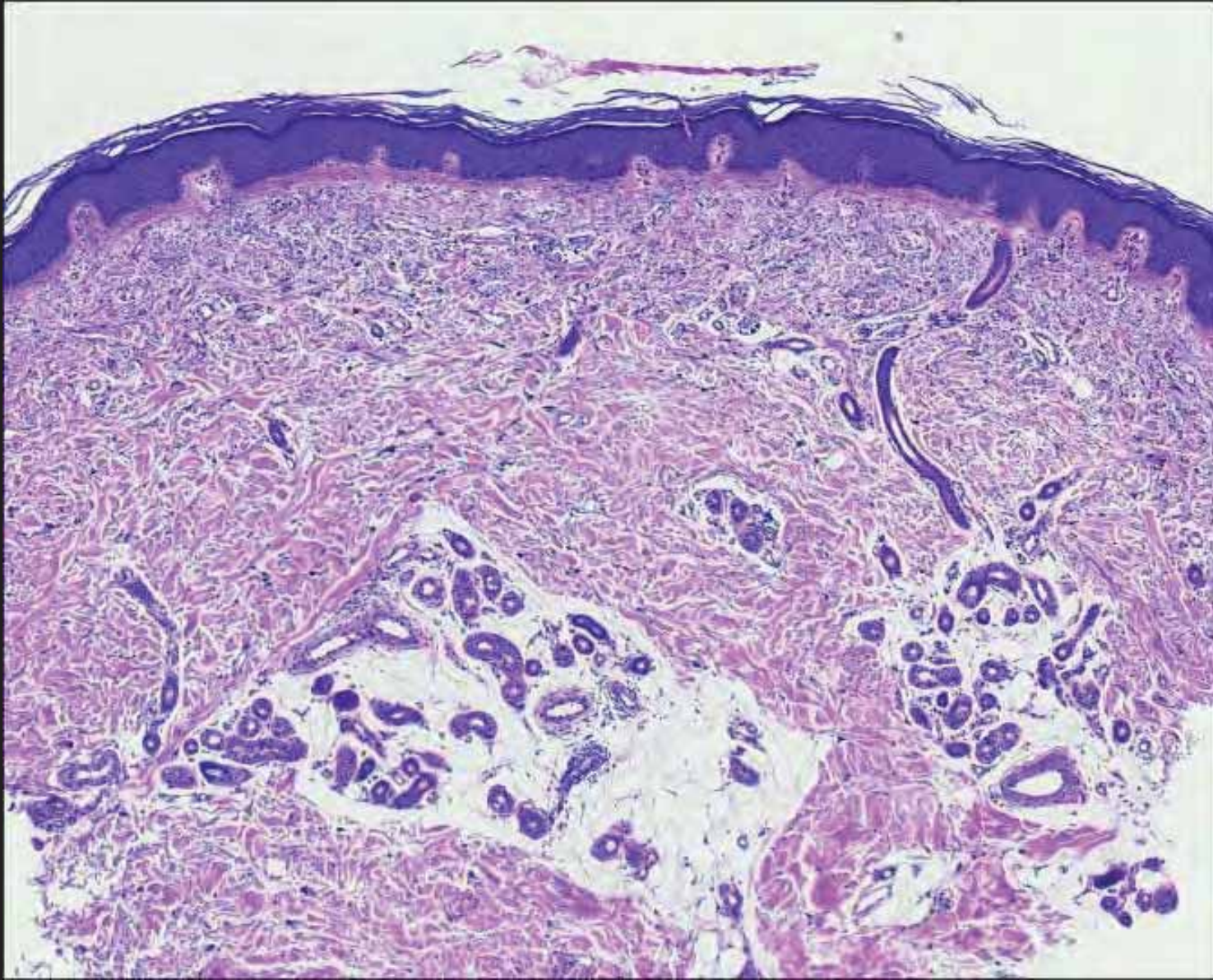


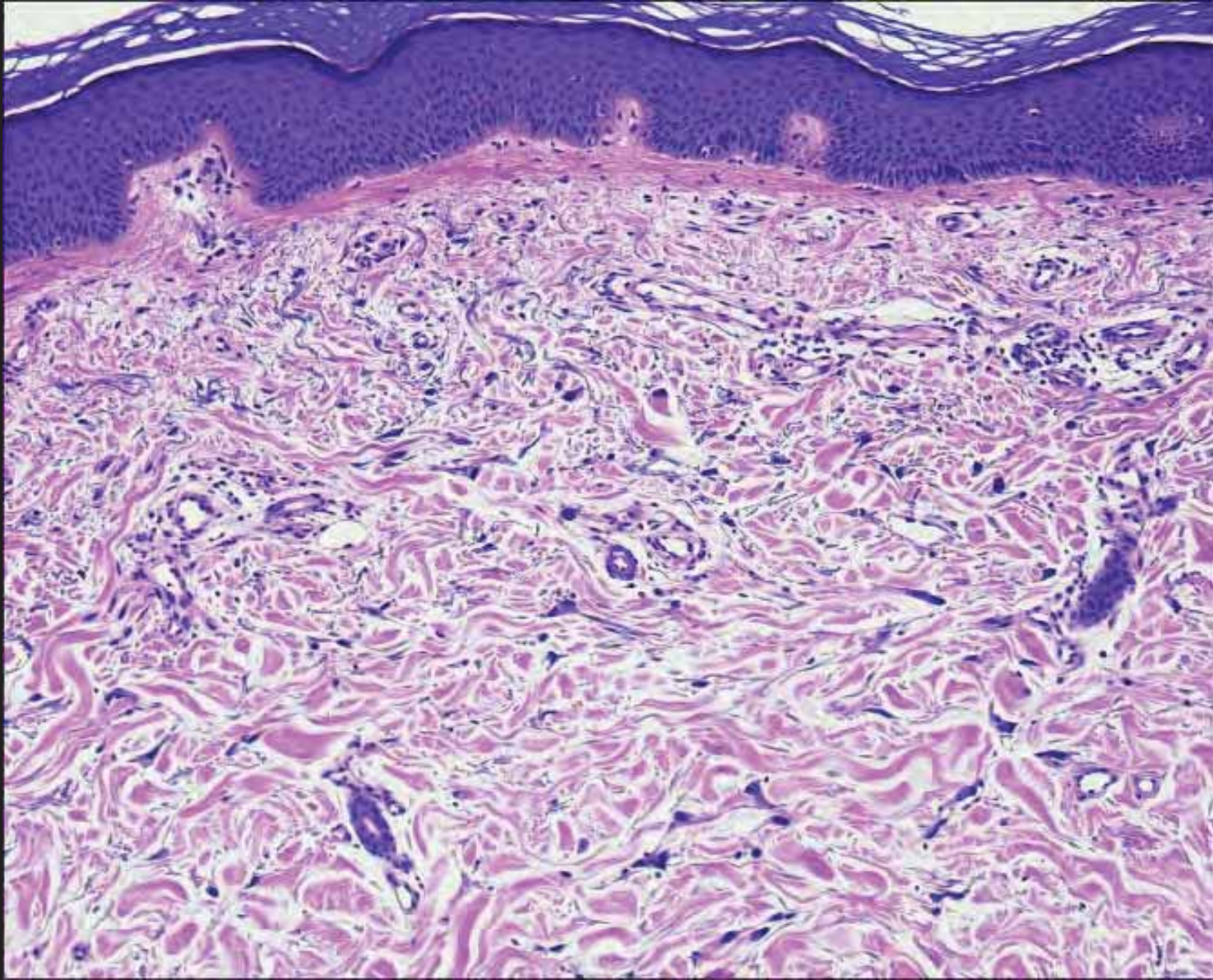


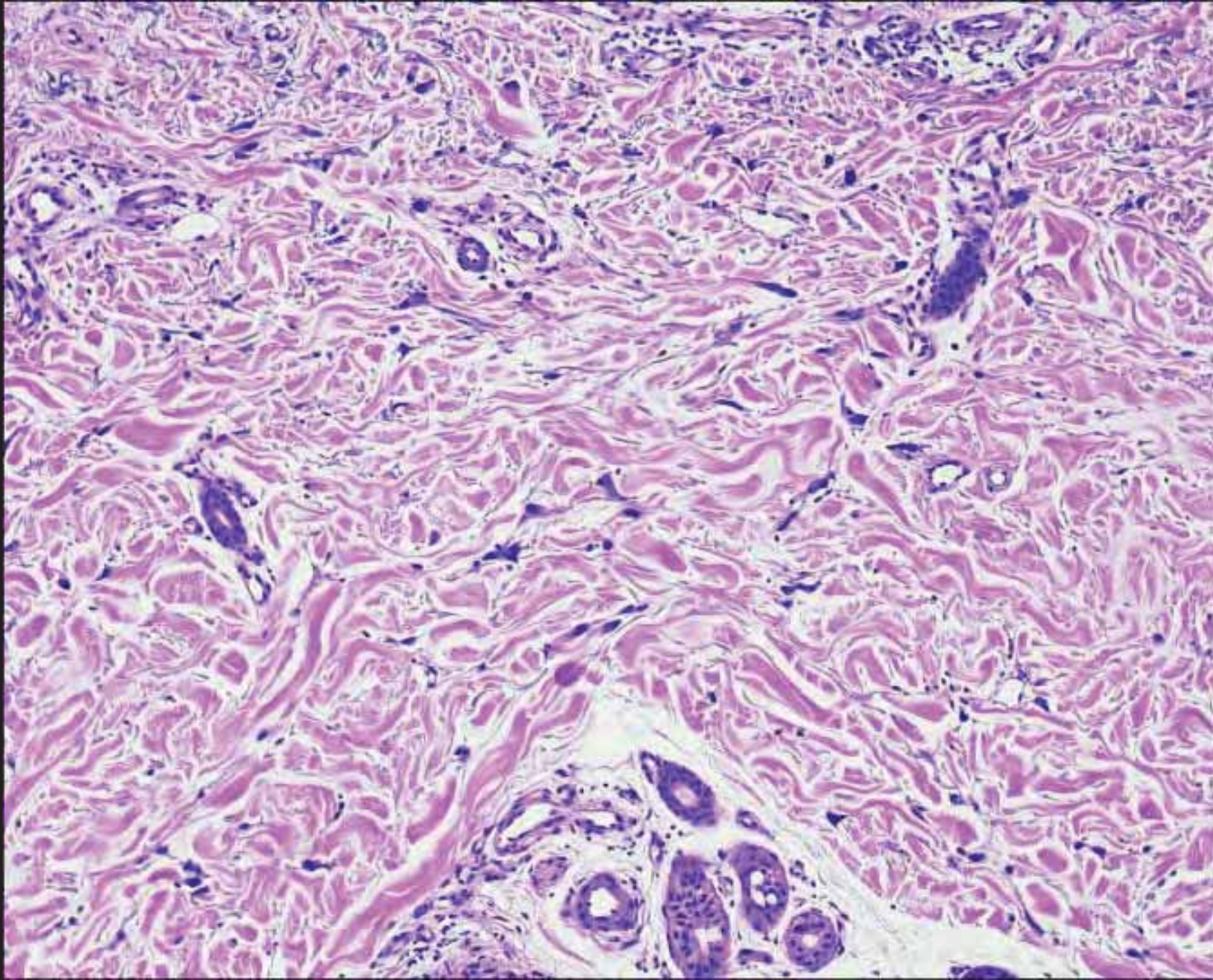


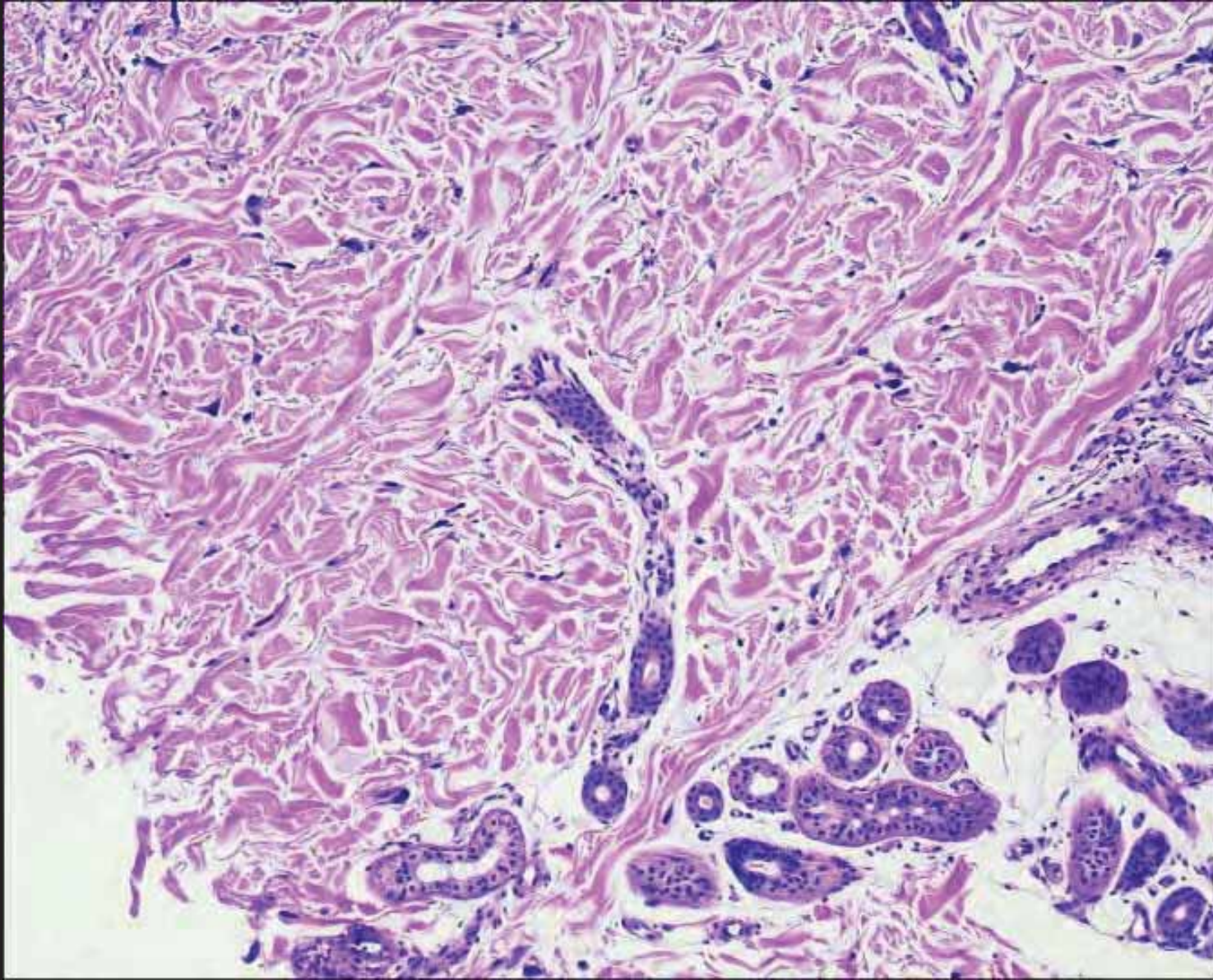


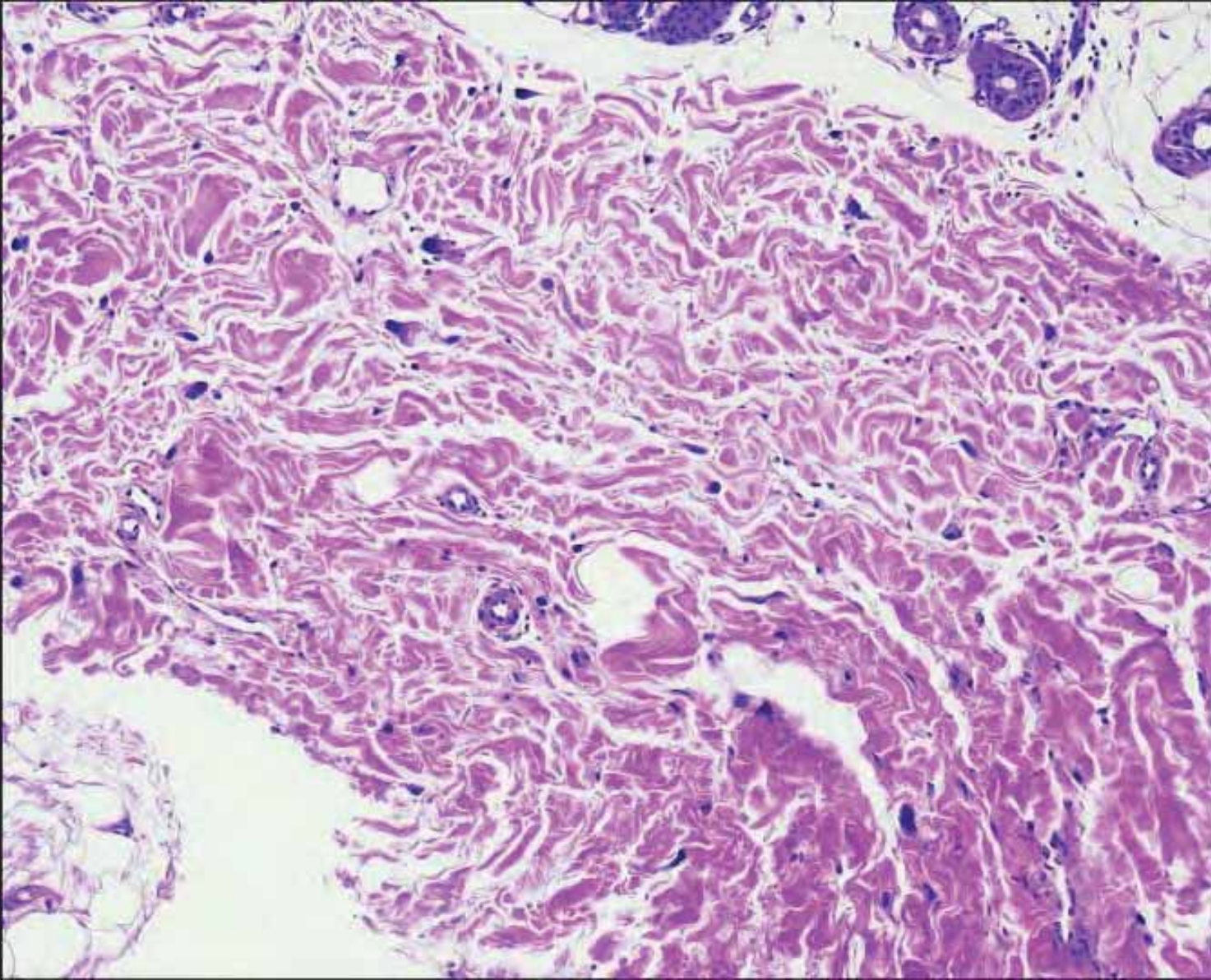


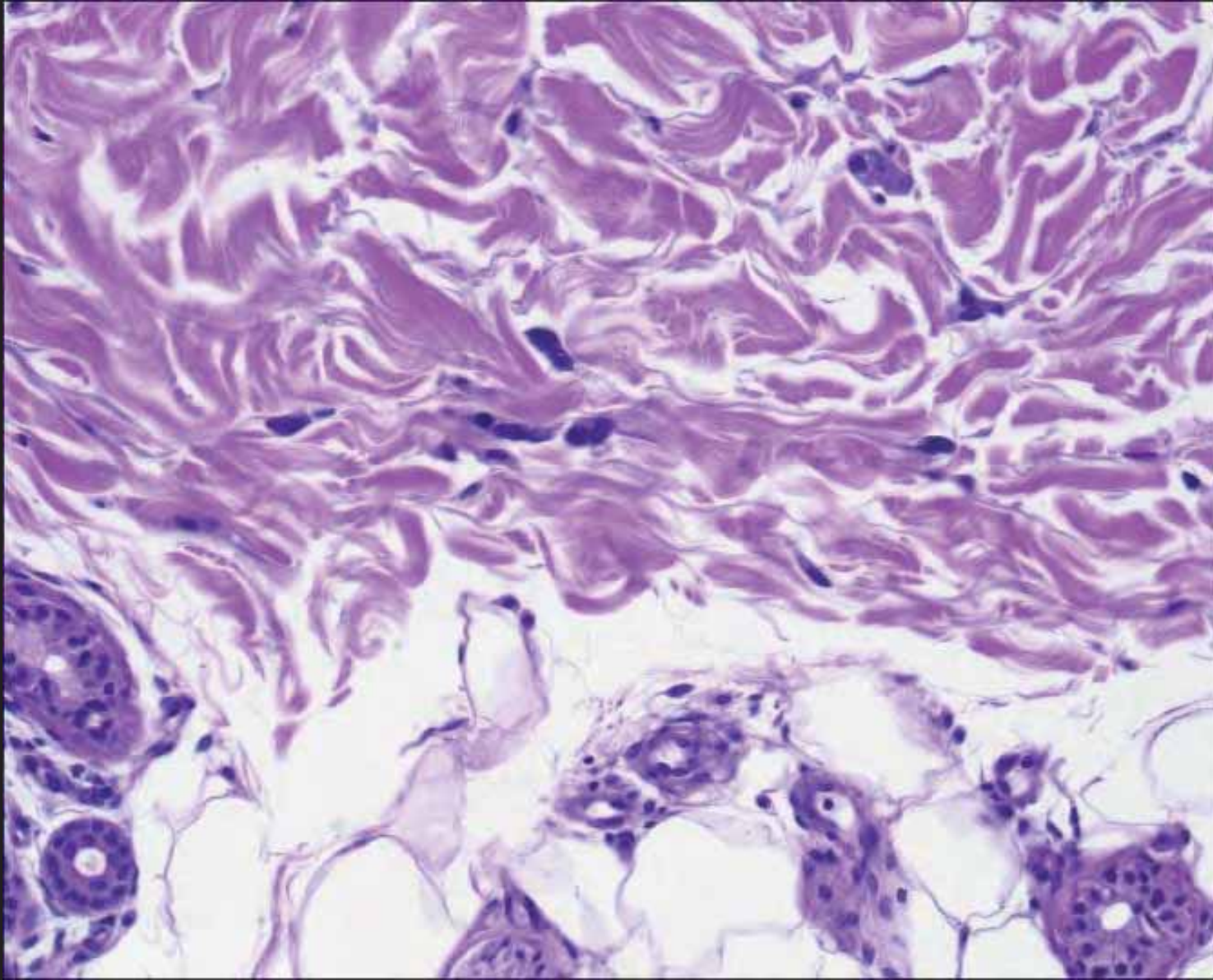


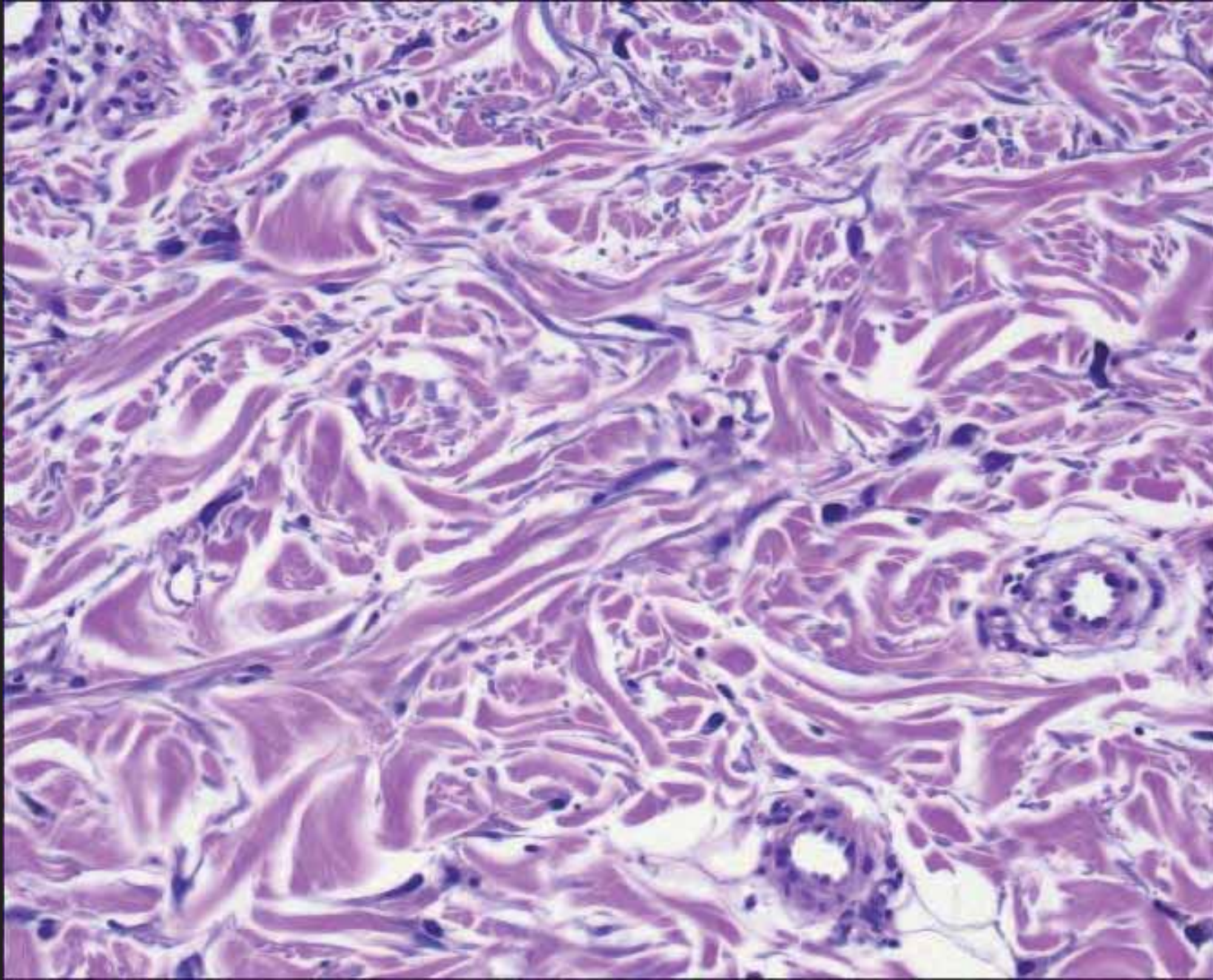


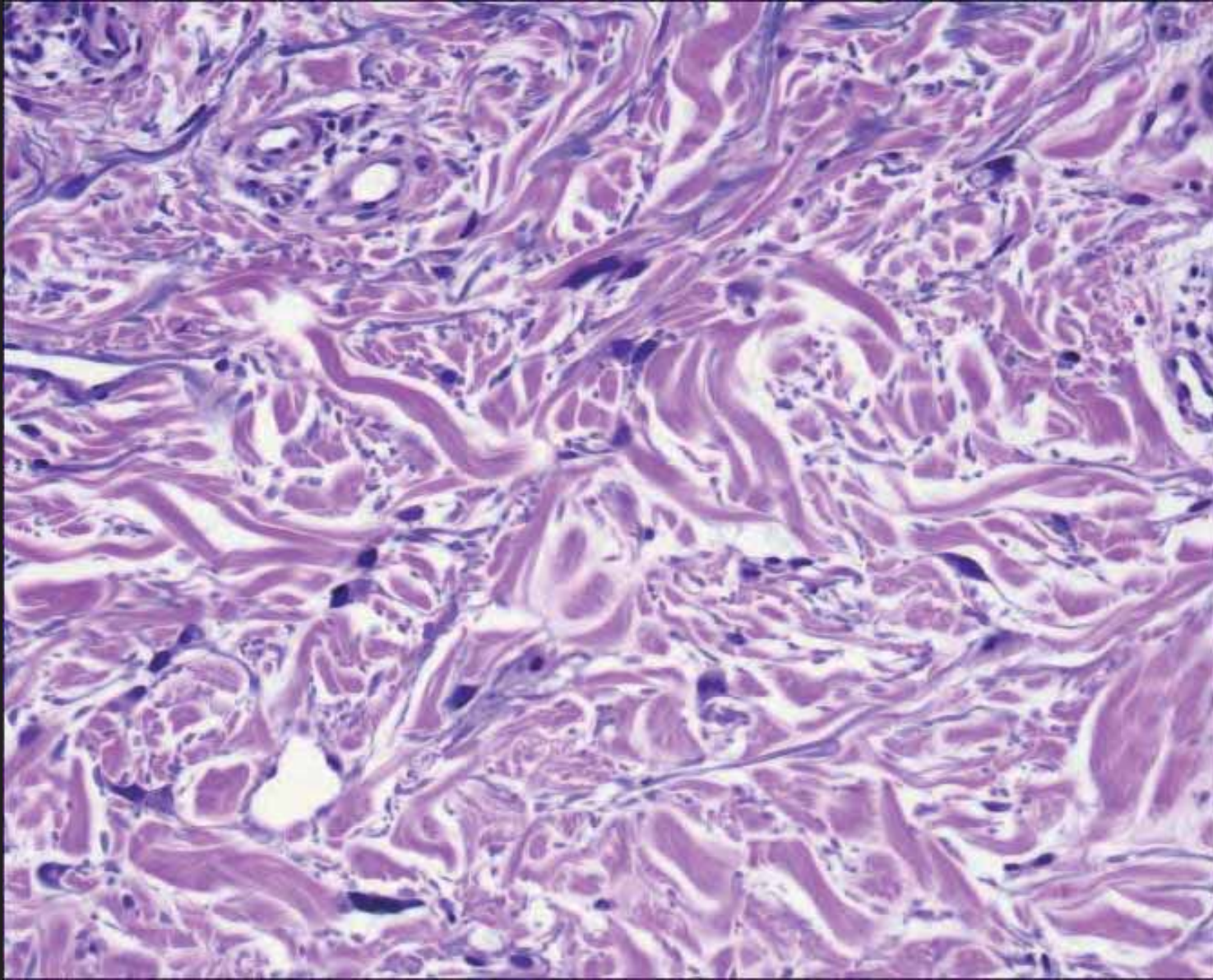


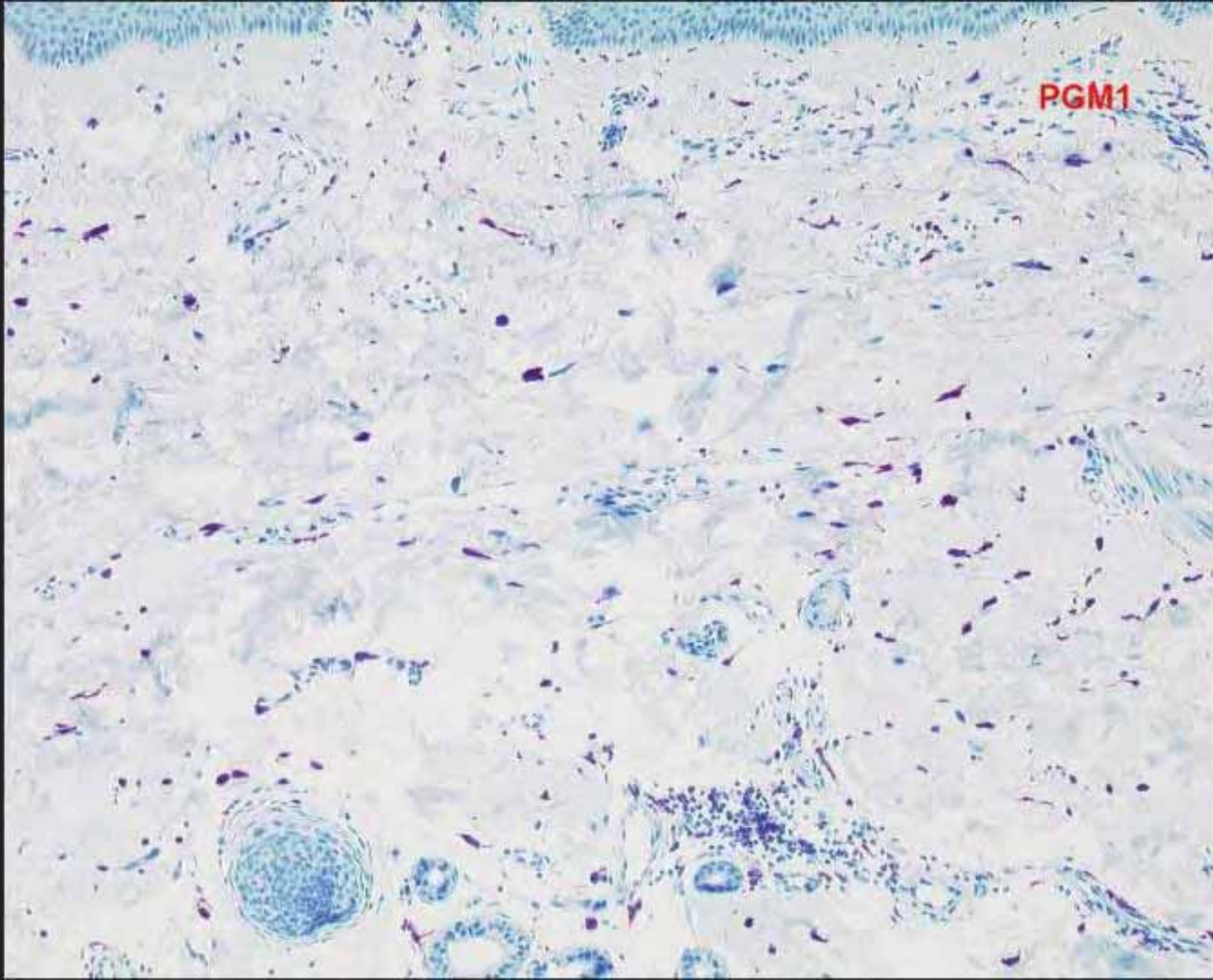


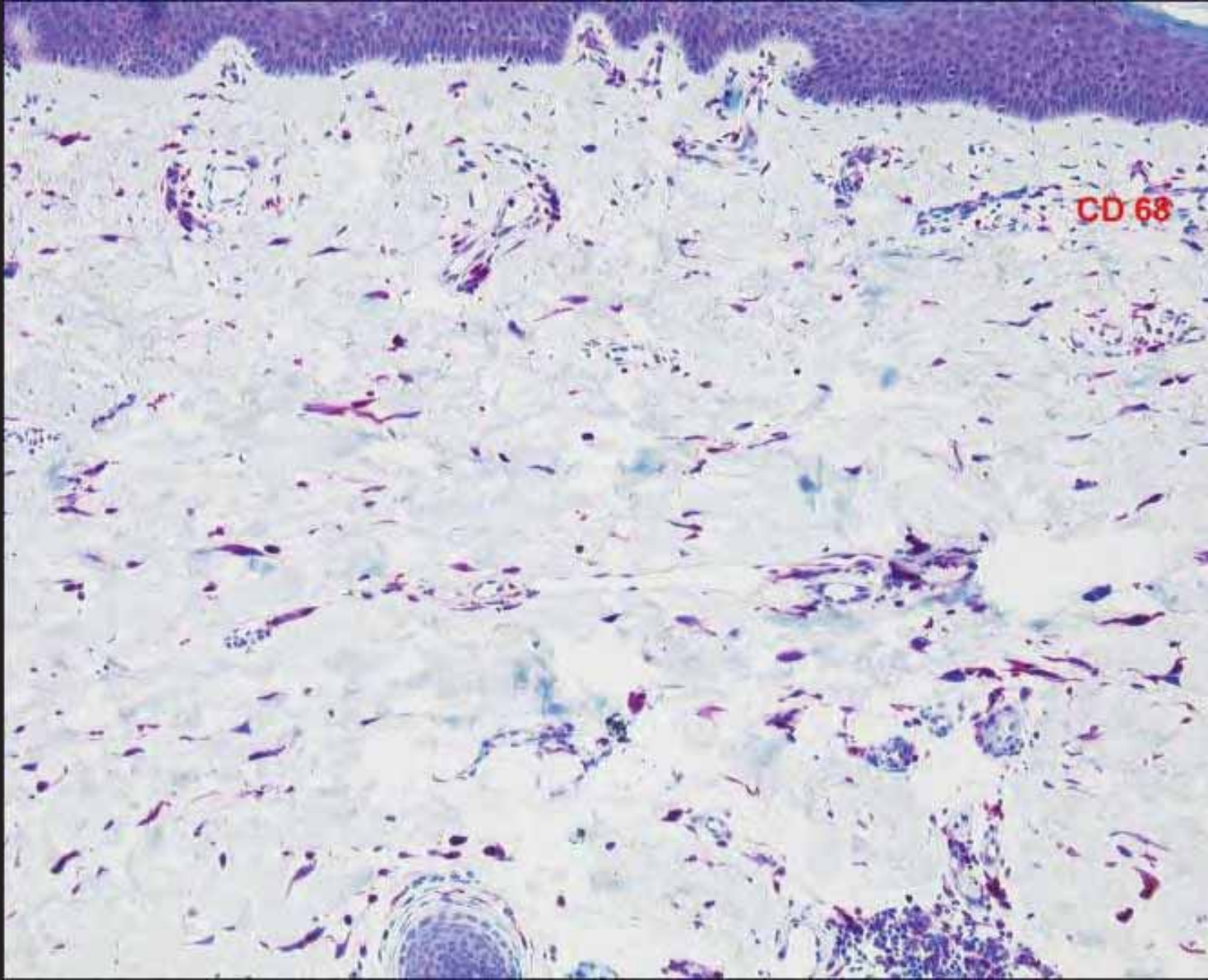


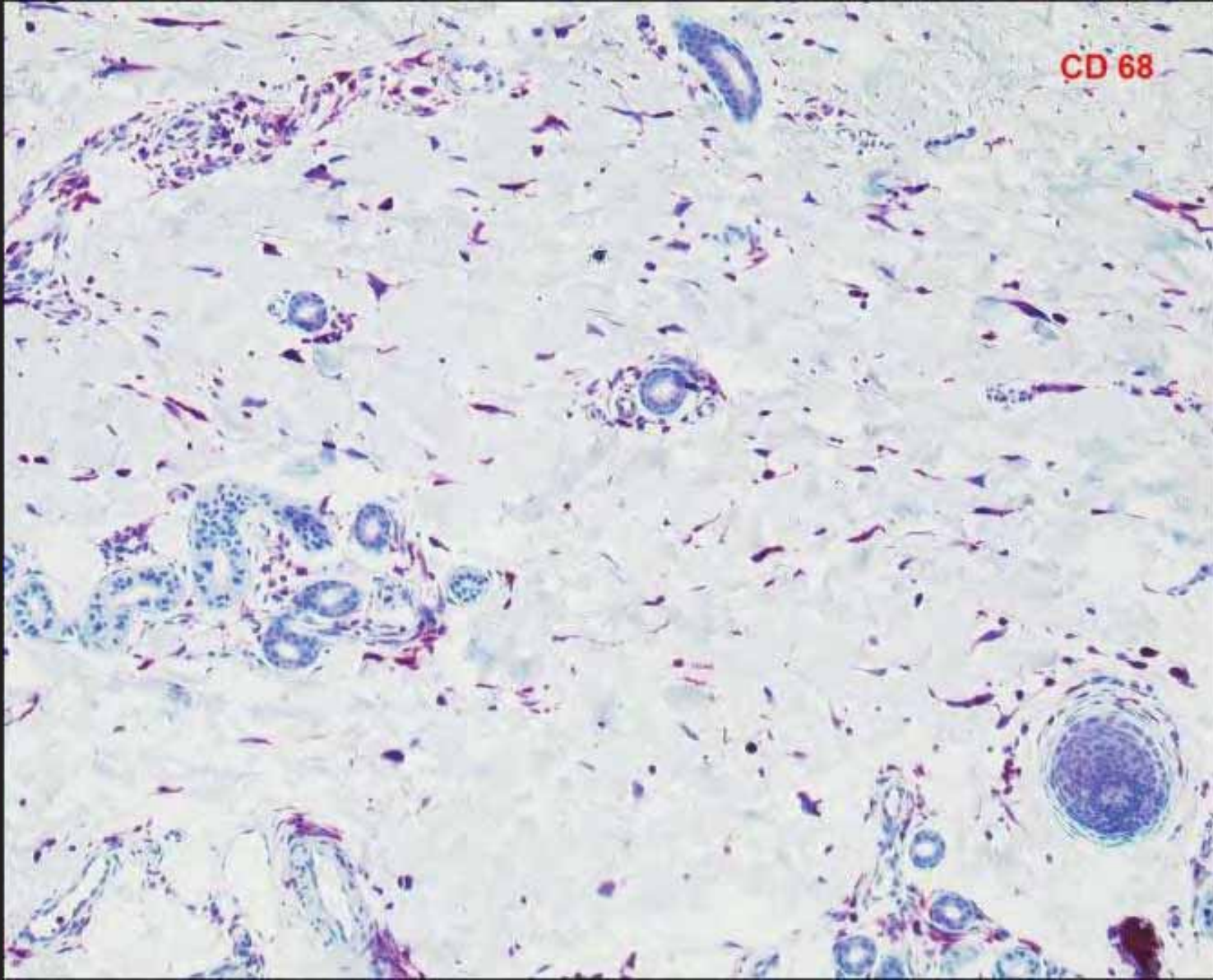












# Histiocytoid vasculitis

# The spectrum of cutaneous granulomatous vasculitis: histopathologic report of eight cases with clinical correlation

Cutaneous granulomatous vasculitis is an uncommon histopathologic finding that has been associated with lymphoproliferative disorders, systemic vasculitis, autoimmune inflammatory diseases, and infection. To define further the concept of cutaneous granulomatous vasculitis and to emphasize its clinical importance, we reviewed biopsy material from 8 patients seen from 1985 through 1992. All biopsies showed evidence of blood vessel damage with fibrinoid change or hemorrhage (or both) and granulomatous inflammation in and around vessel walls. Special stains for microorganisms were negative in all cases. Associated medical disorders included neuropathy (2 patients), sarcoid-like disease (2), systemic vasculitis (1), lymphoma and suspected lymphoma (1 each), and associated herpes simplex virus (1). T-cell gene-rearrangement studies were negative in a patient with suspected lymphoma. Granulomatous cutaneous vasculitis is most commonly associated with lymphoma and systemic vasculitis. In selected cases, infection should be considered as an underlying cause.

**Lawrence E. Gibson<sup>1</sup>,  
Rokea A. el-Azhary<sup>2</sup>,  
Thomas F. Smith<sup>3</sup> and  
Ashraf M. Reda<sup>4</sup>**

<sup>1</sup>Department of Dermatology and <sup>2</sup>Division of Clinical Microbiology, Mayo Clinic and Mayo Foundation, Rochester, Minnesota, and  
<sup>3</sup>Department of Dermatology, Mayo Clinic Jacksonville, Florida, USA. <sup>4</sup>Visiting Clinician at the Department of Dermatology.

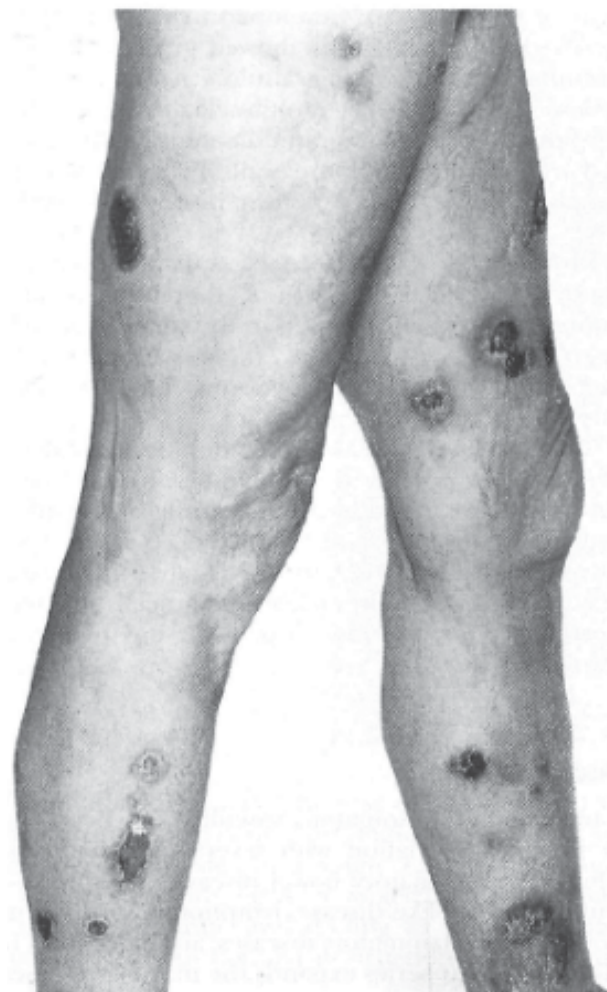

Fig. 1. (Patient 1). Multiple ulcerative plaques of lower extremities in patient with lymphoma.

than 20 yr, 1 patient has had recurring facial and nasal papules suggestive of sarcoidosis. Two patients had peripheral neuropathies of the lower extremities, and 1 had chronic recurrent pain located in the right scalp. Because of the nature and location of the pain, PCR was performed from a skin biopsy sample and a 92-base pair DNA amplification specific for HSV was detected.

#### Histopathology

Routine histopathology showed granulomatous vasculitis in all cases. Destructive changes of blood vessels were usually in the superficial and mid der-

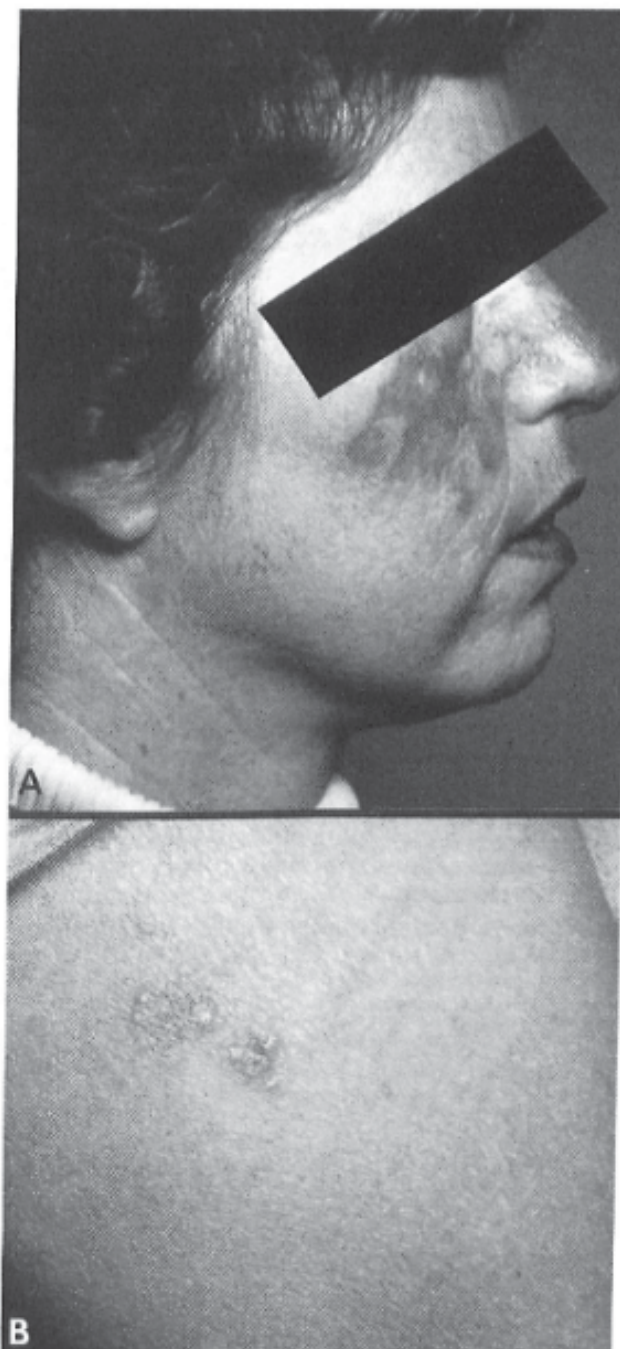


Fig. 2. (Patient 7). A, Sarcoid process of nose and cheeks of more than 20 years' duration. B, Papular lesions of arm of several months' duration.

rated necrotizing vasculitis with granuloma but

## Cutaneous granulomatous vasculitis

*Fig. 3.* (Patient 3).  
Granulomatous  
inflammation with blood  
vessel destruction in mid  
dermis in patient with  
systemic vasculitis  
(H&E,  $\times 160$ ).

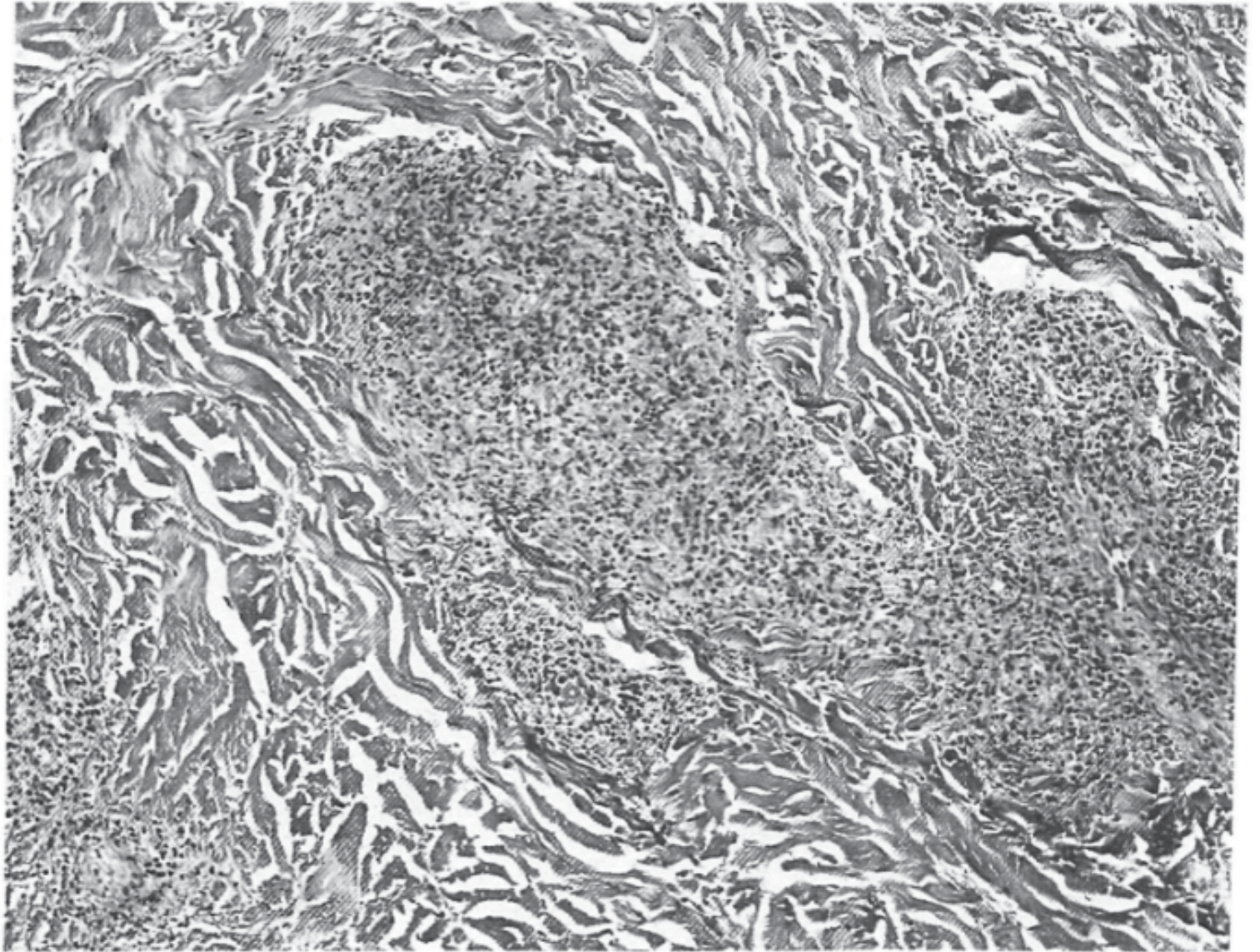
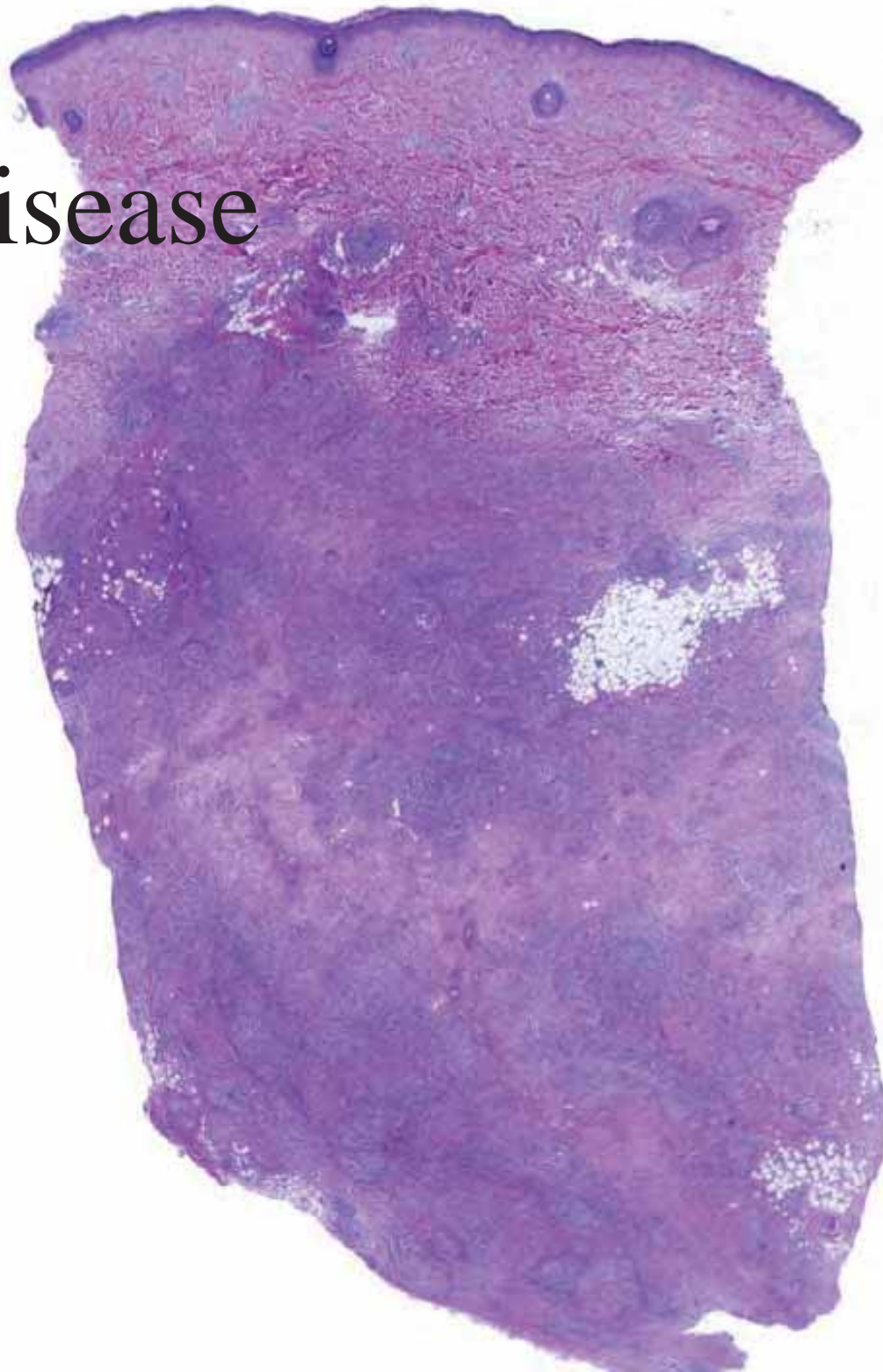

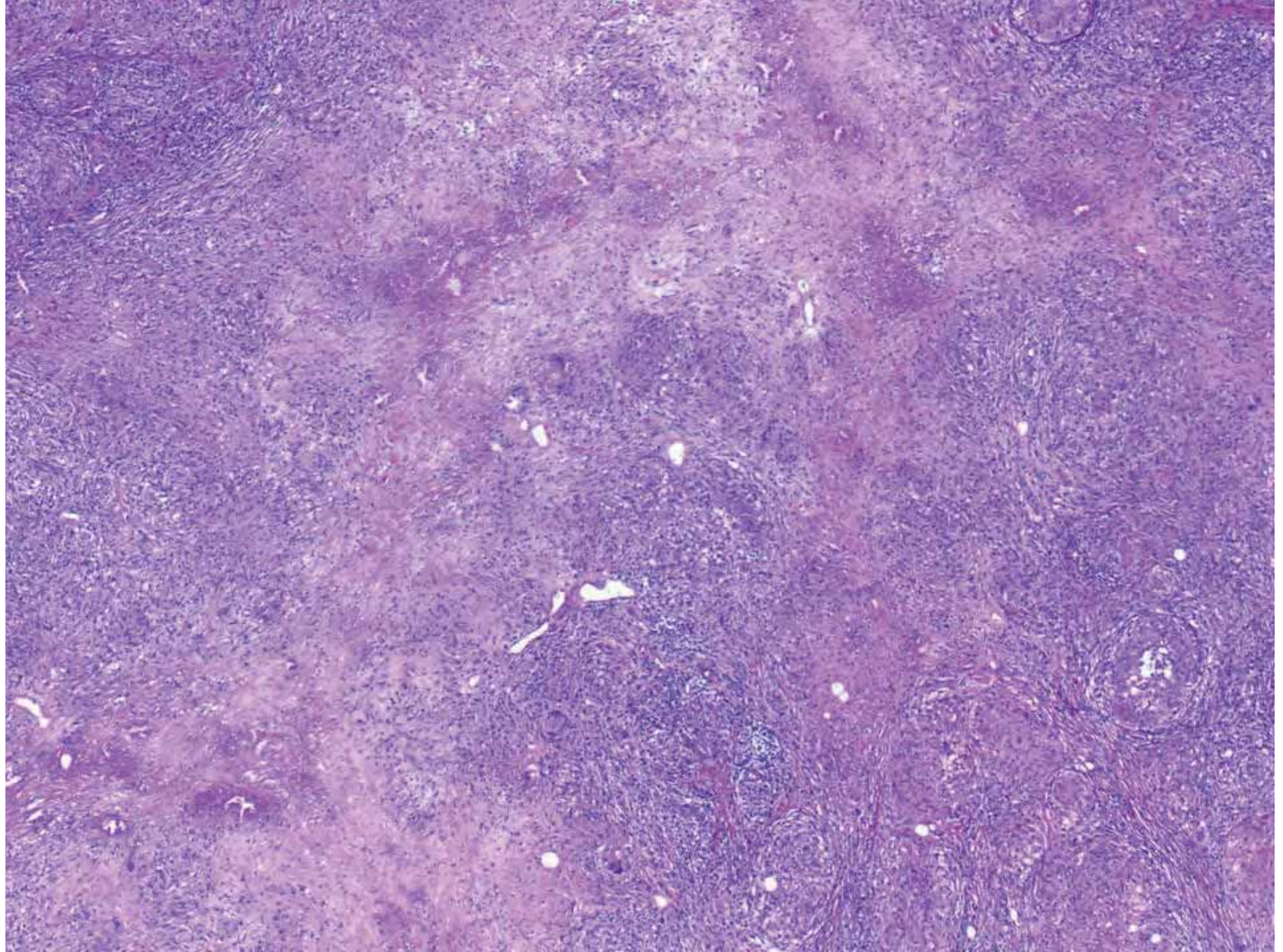
Table 4. Disorders associated with cutaneous granulomatous vasculitis in 34 patients

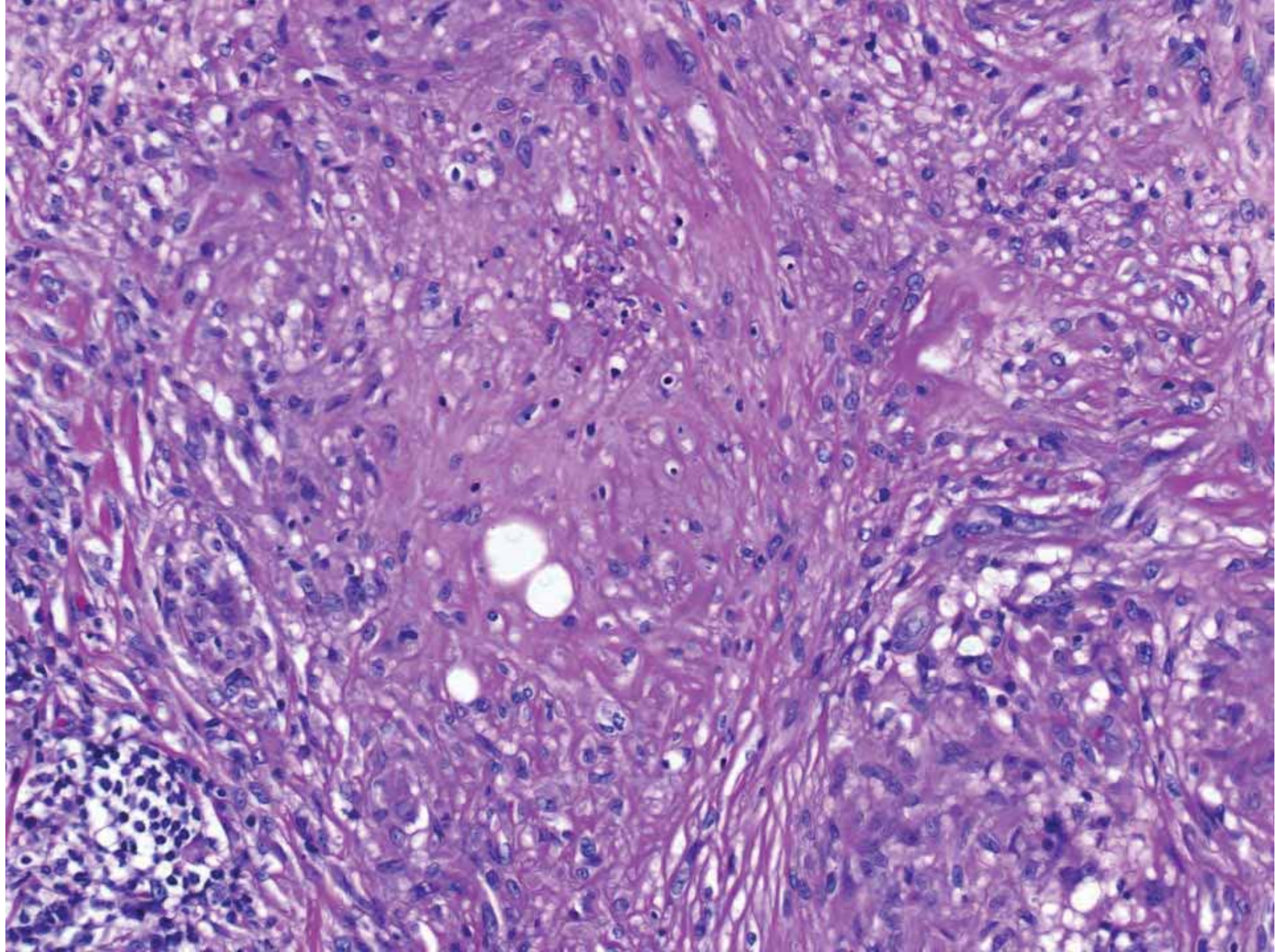
Associated disorder	No. patients
Lymphoproliferative diseases	11
Systemic vasculitis	5
Sarcoid-like disease	5
Arthritis	5
Gastrointestinal disease	4
Neuropathy alone	3
Painful scalp papules*	1

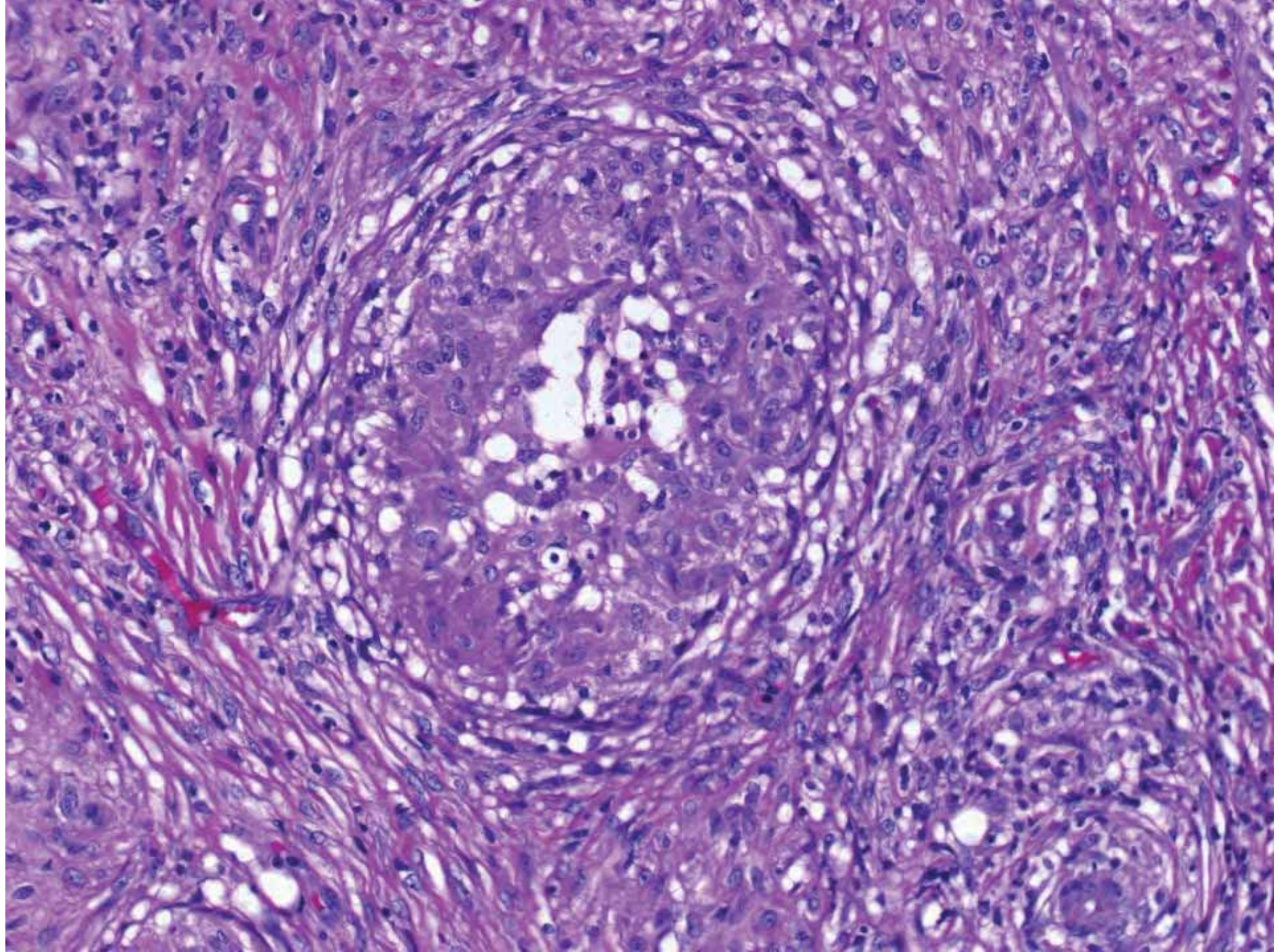
\* Herpes simplex virus DNA demonstrated by polymerase chain reaction.

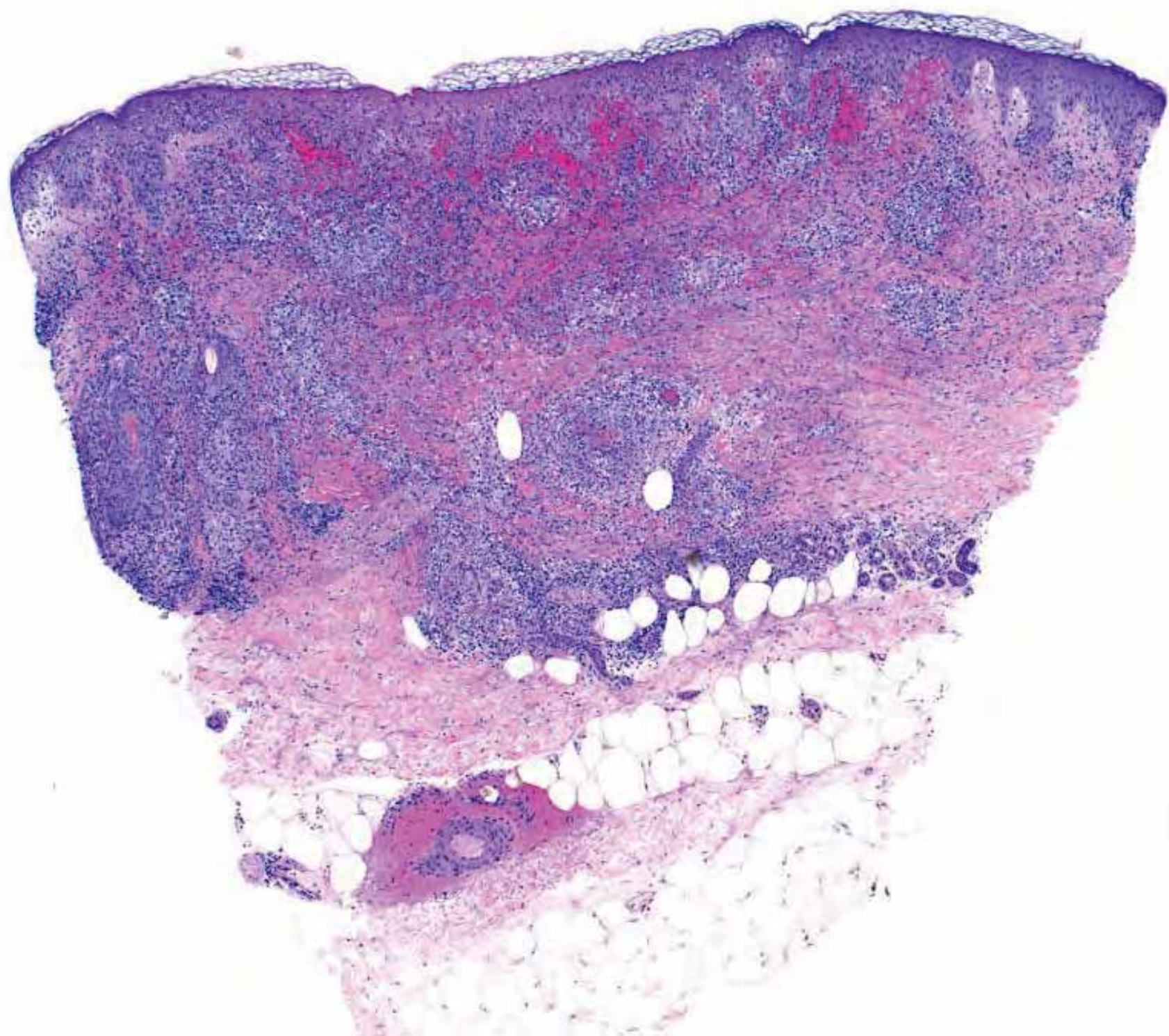
# Crohn's disease

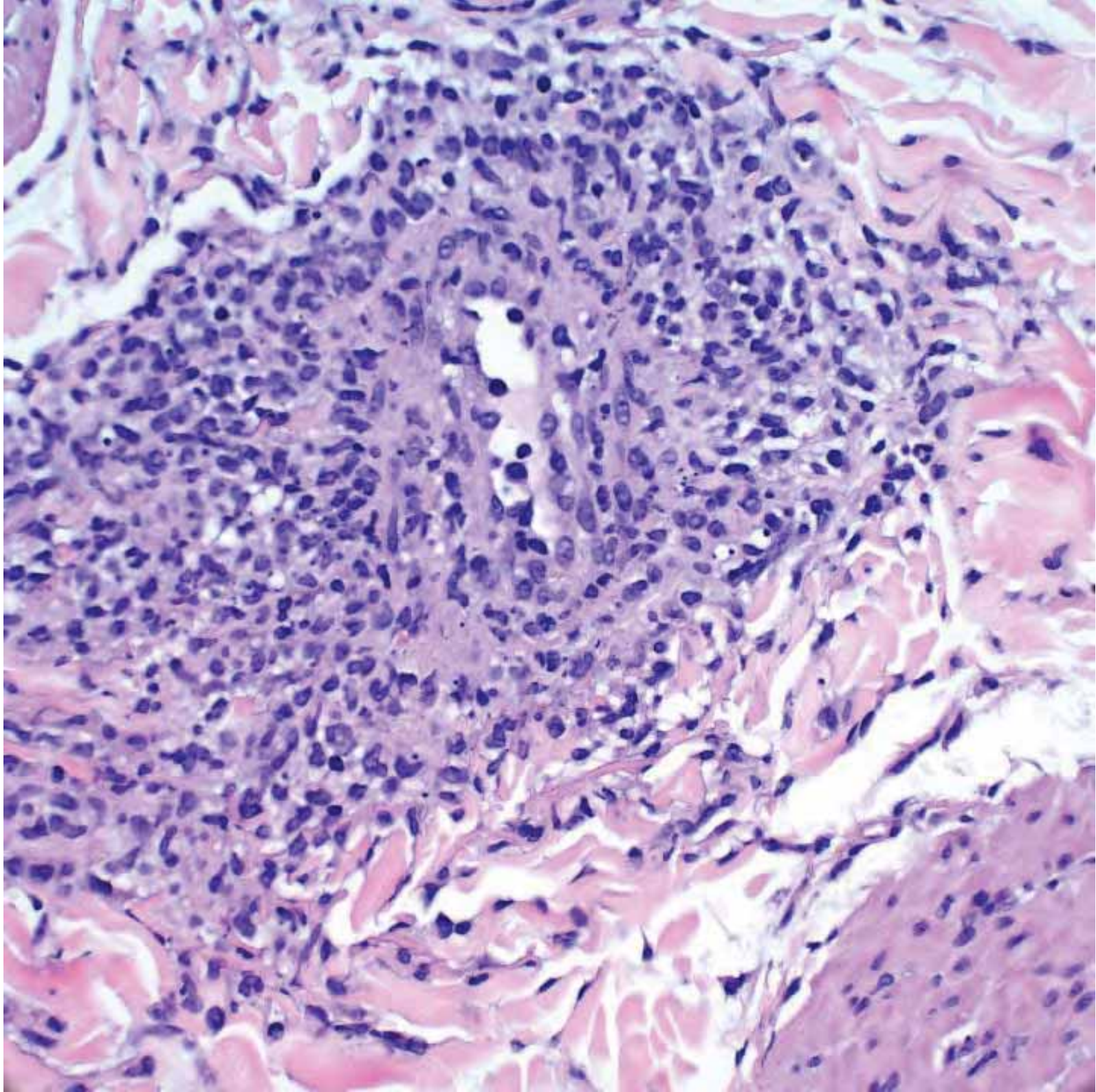




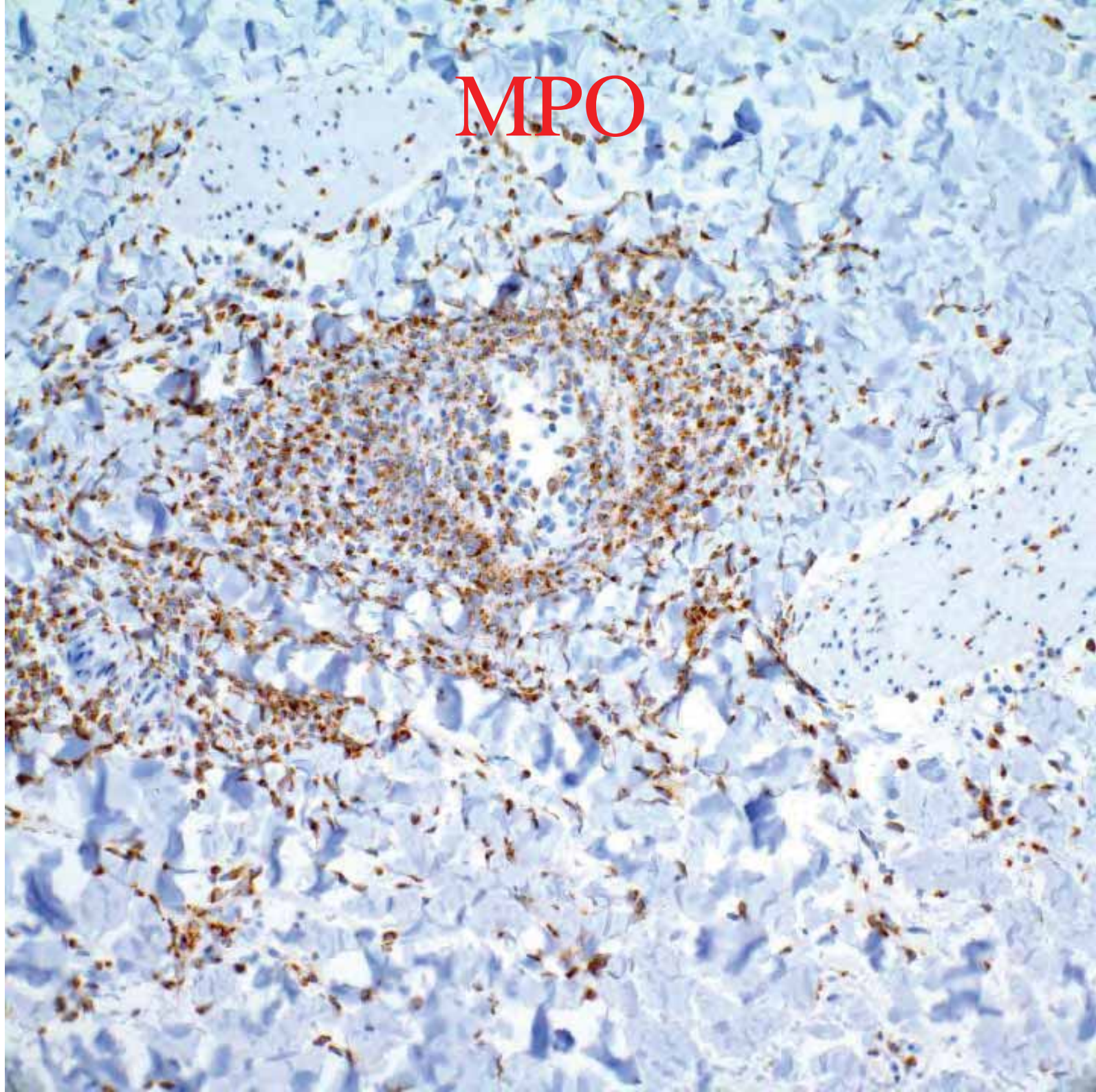


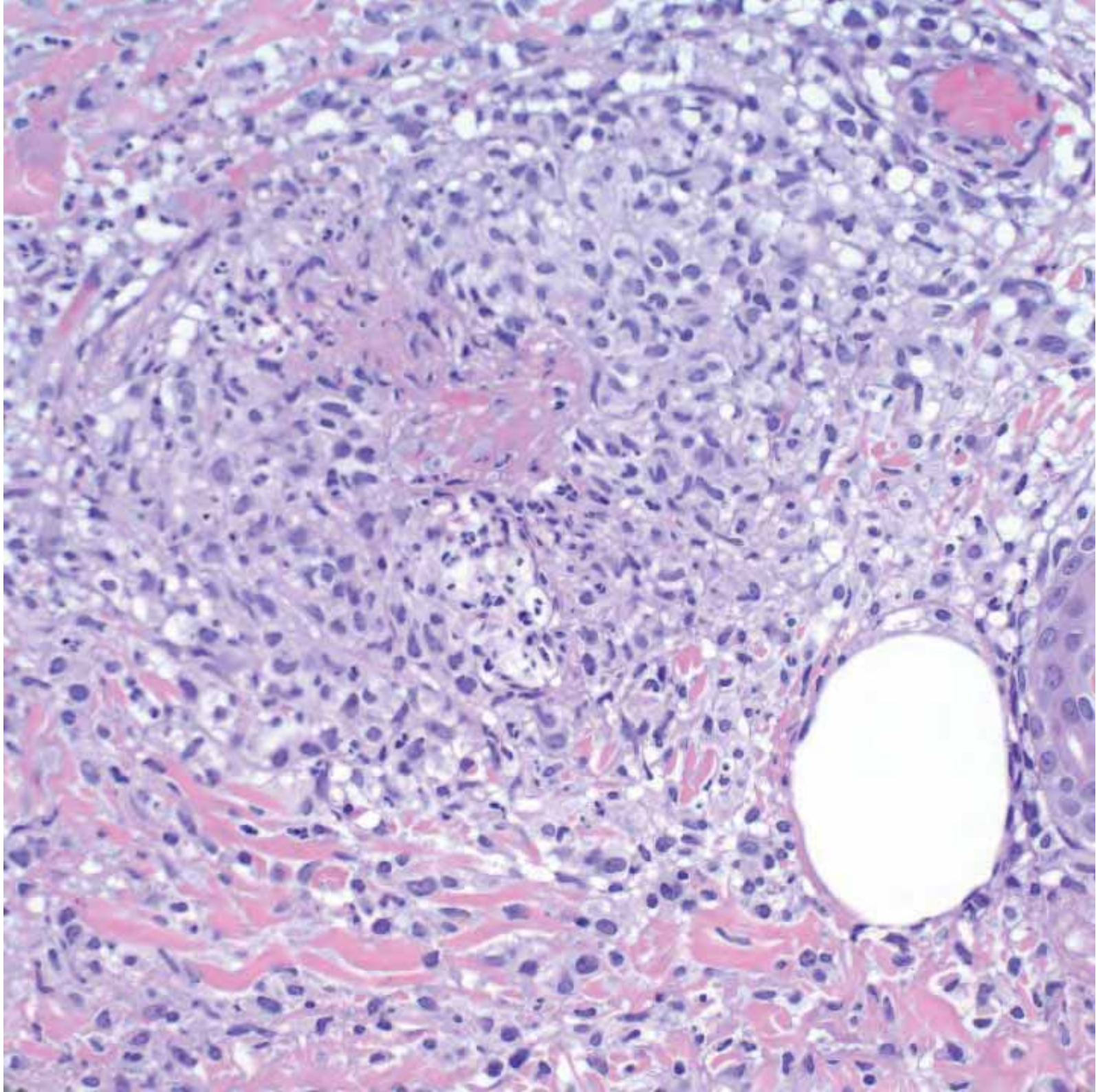


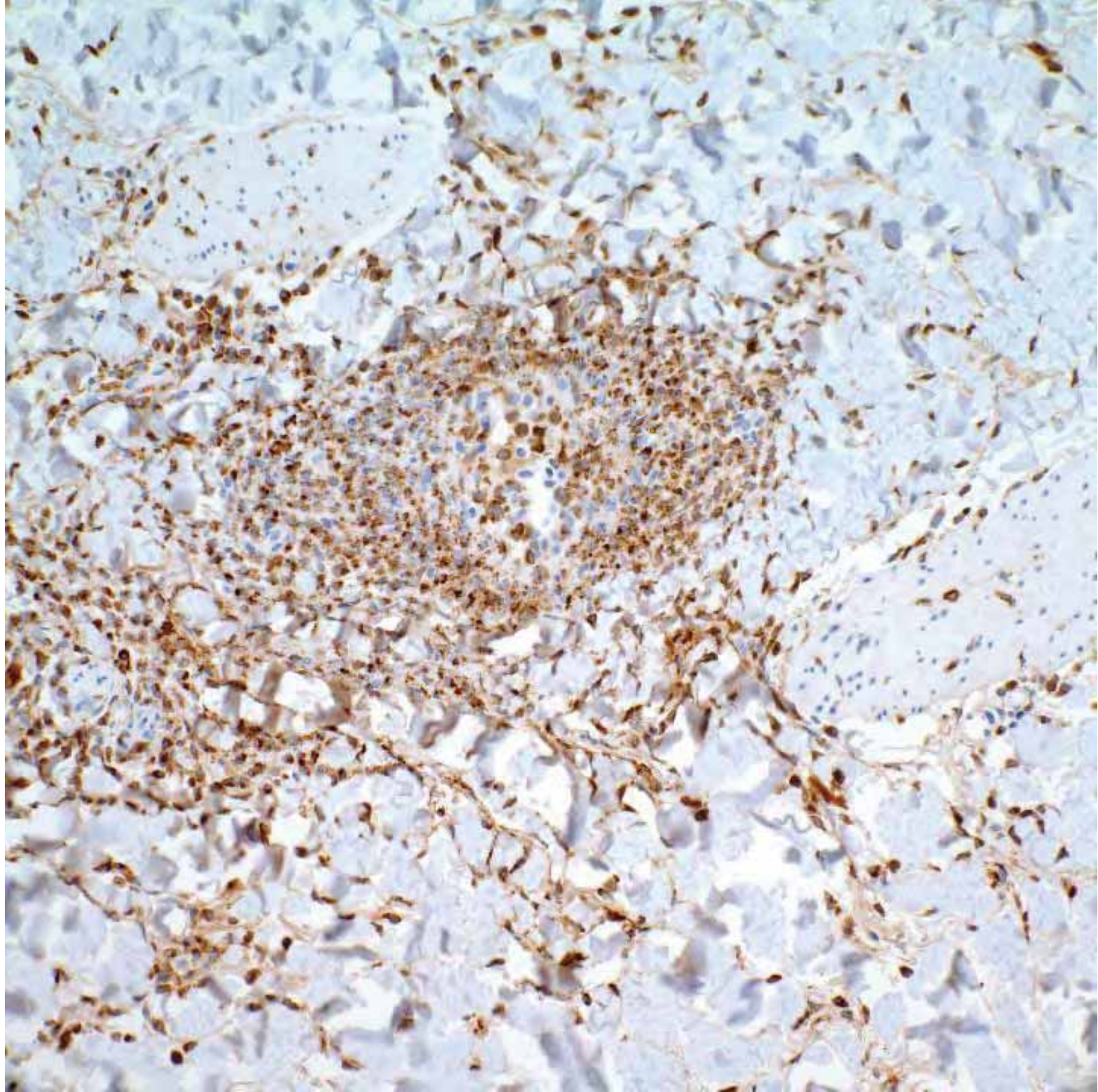




MPO

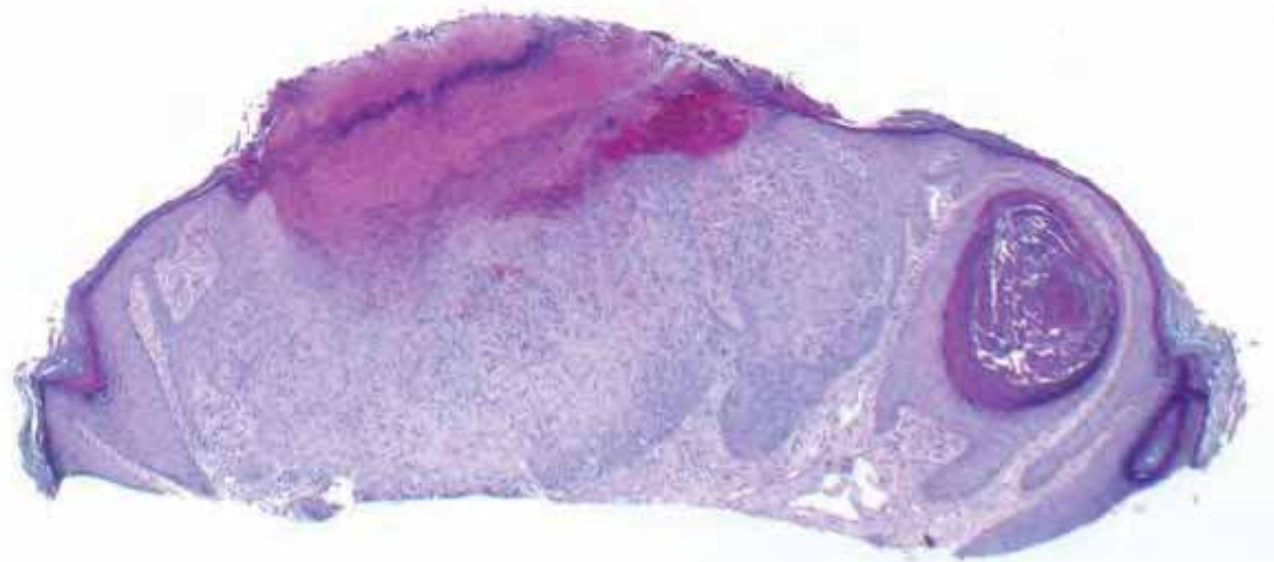
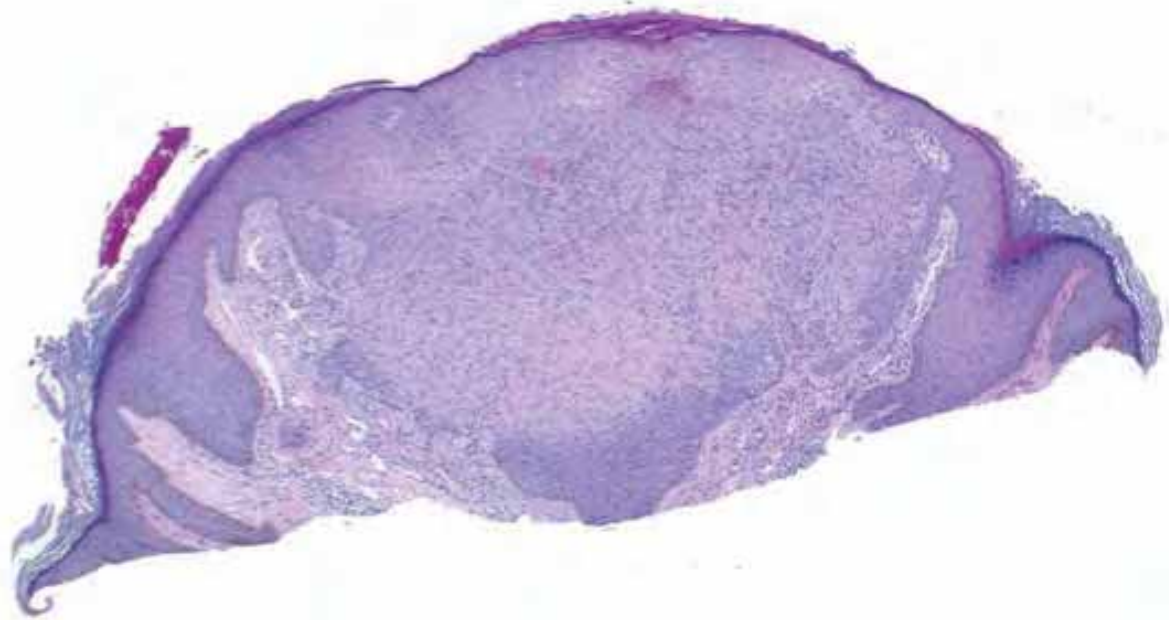


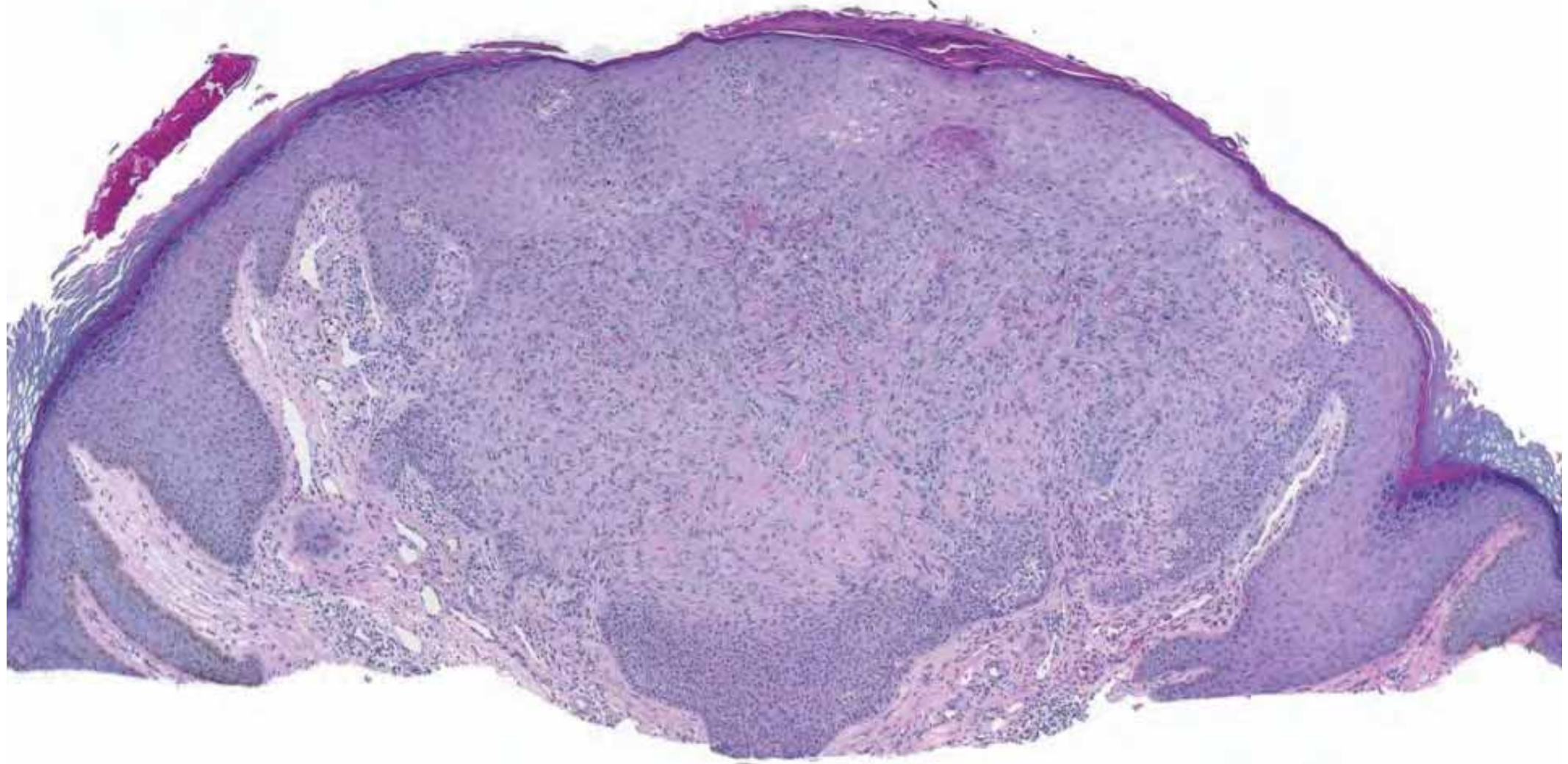


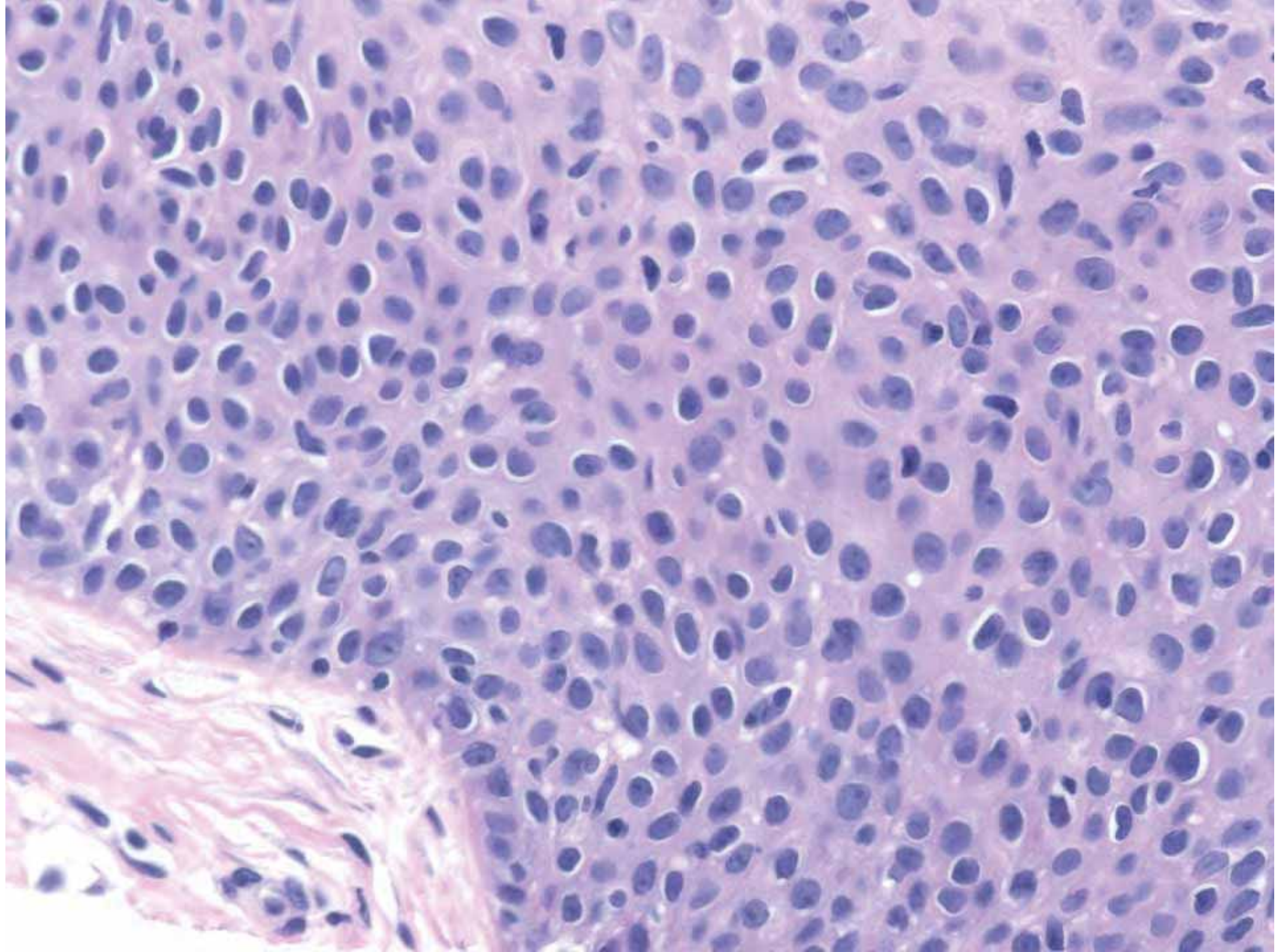


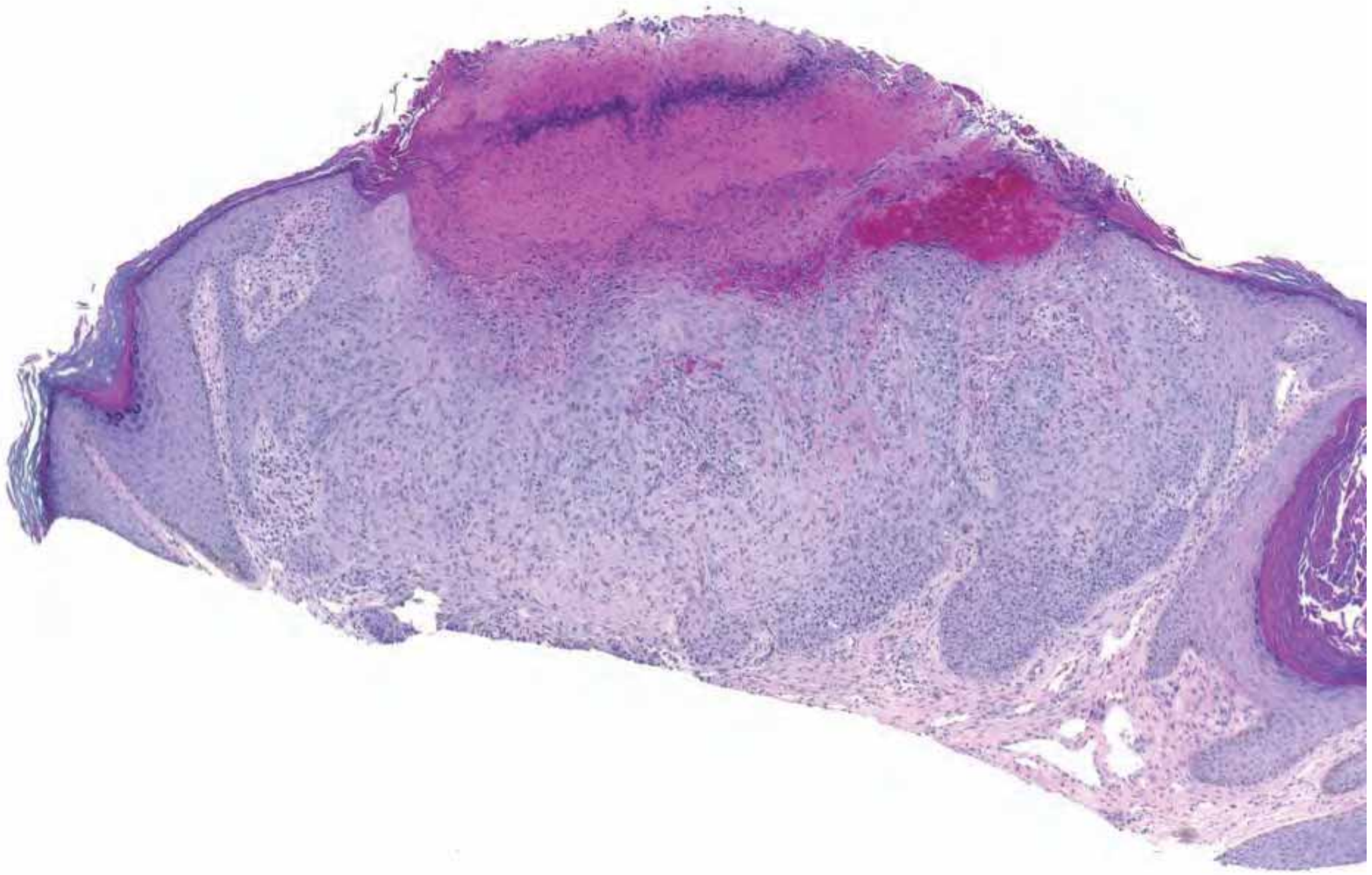
# Desmoplastic trichilemmoma is traumatized trichilemmoma

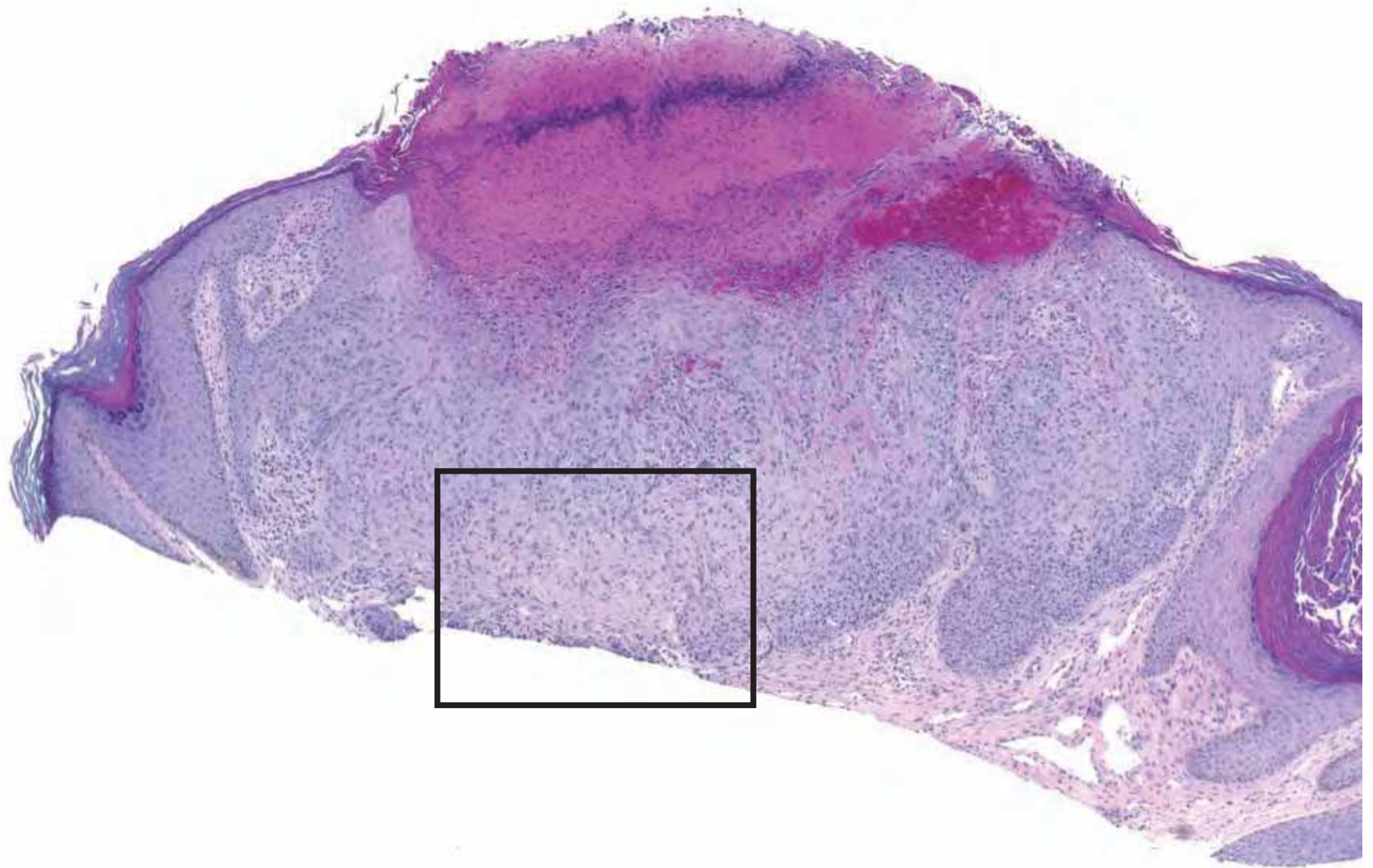
- Usually presents as a small wart-like lesion on the face
- Not really a variant *sui generis*, but probably....
- ...a reaction to trauma in a pre-existent trichilemmoma
- Lobules, necrosis in their centers
- Desmoplasia is in areas of wound healing reaction

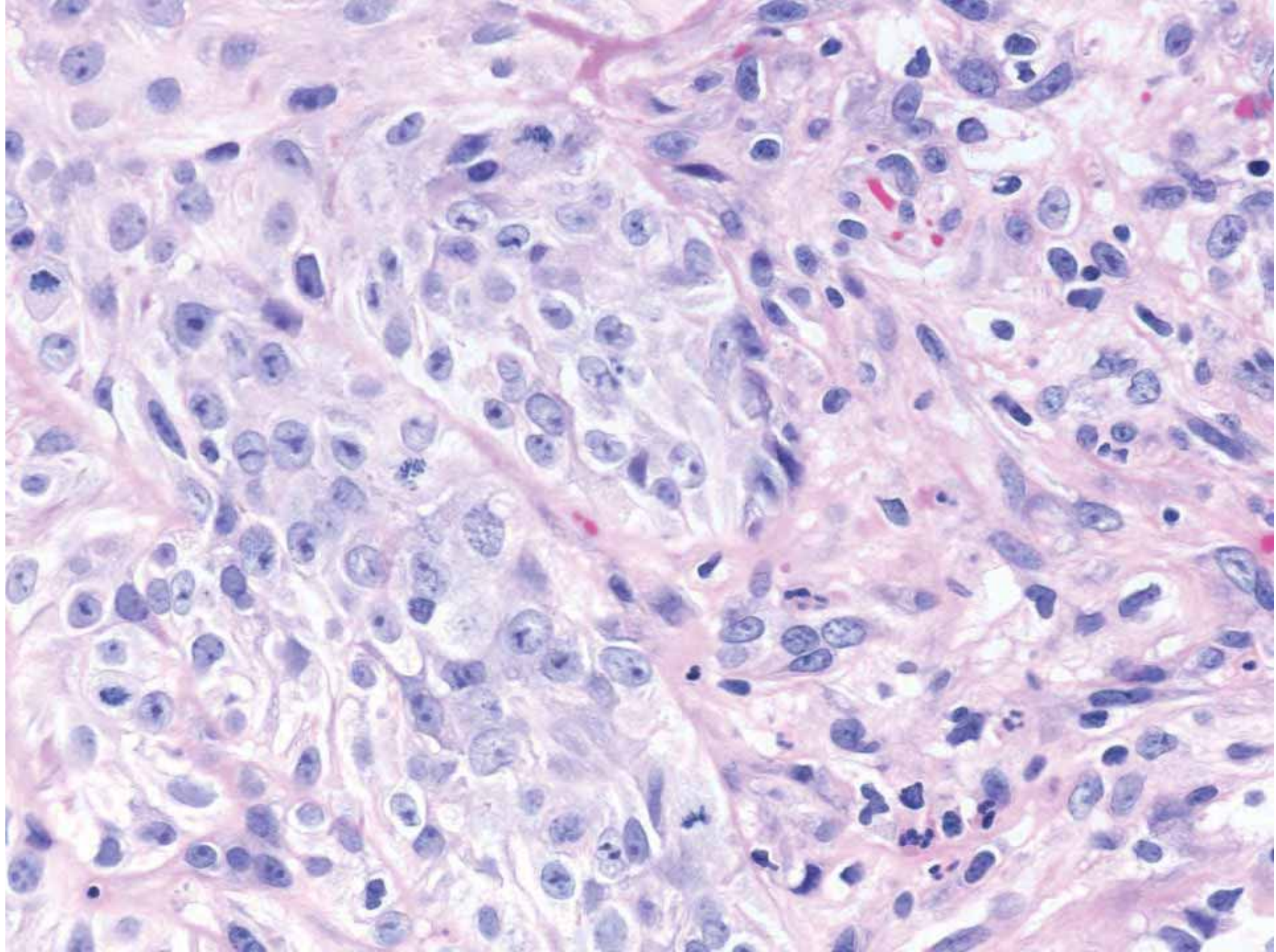








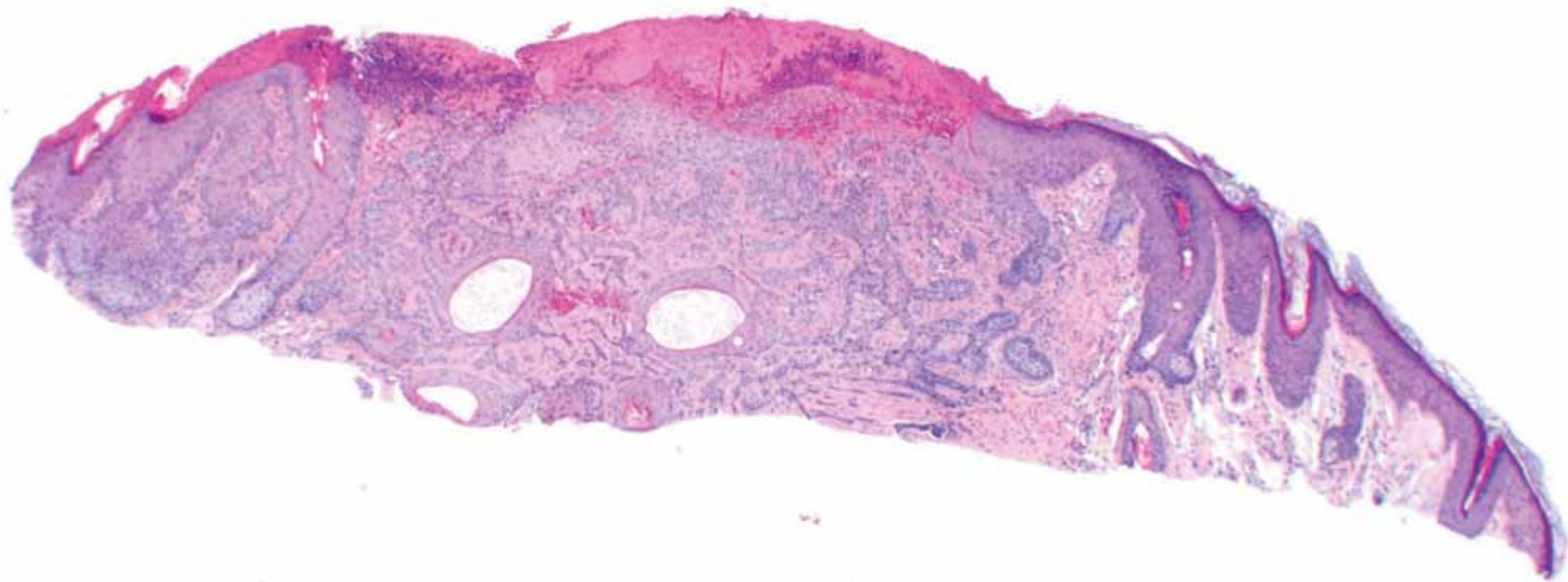


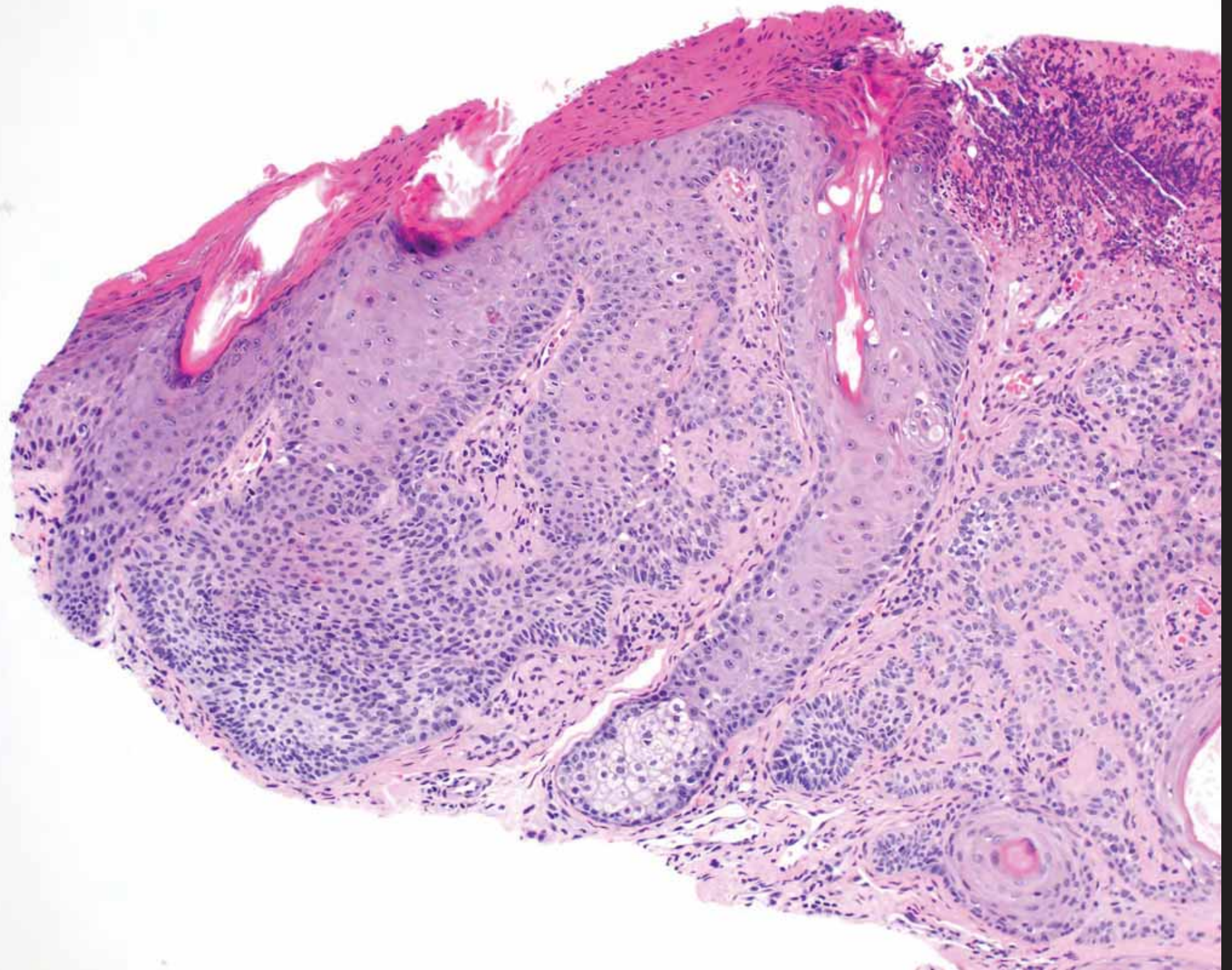


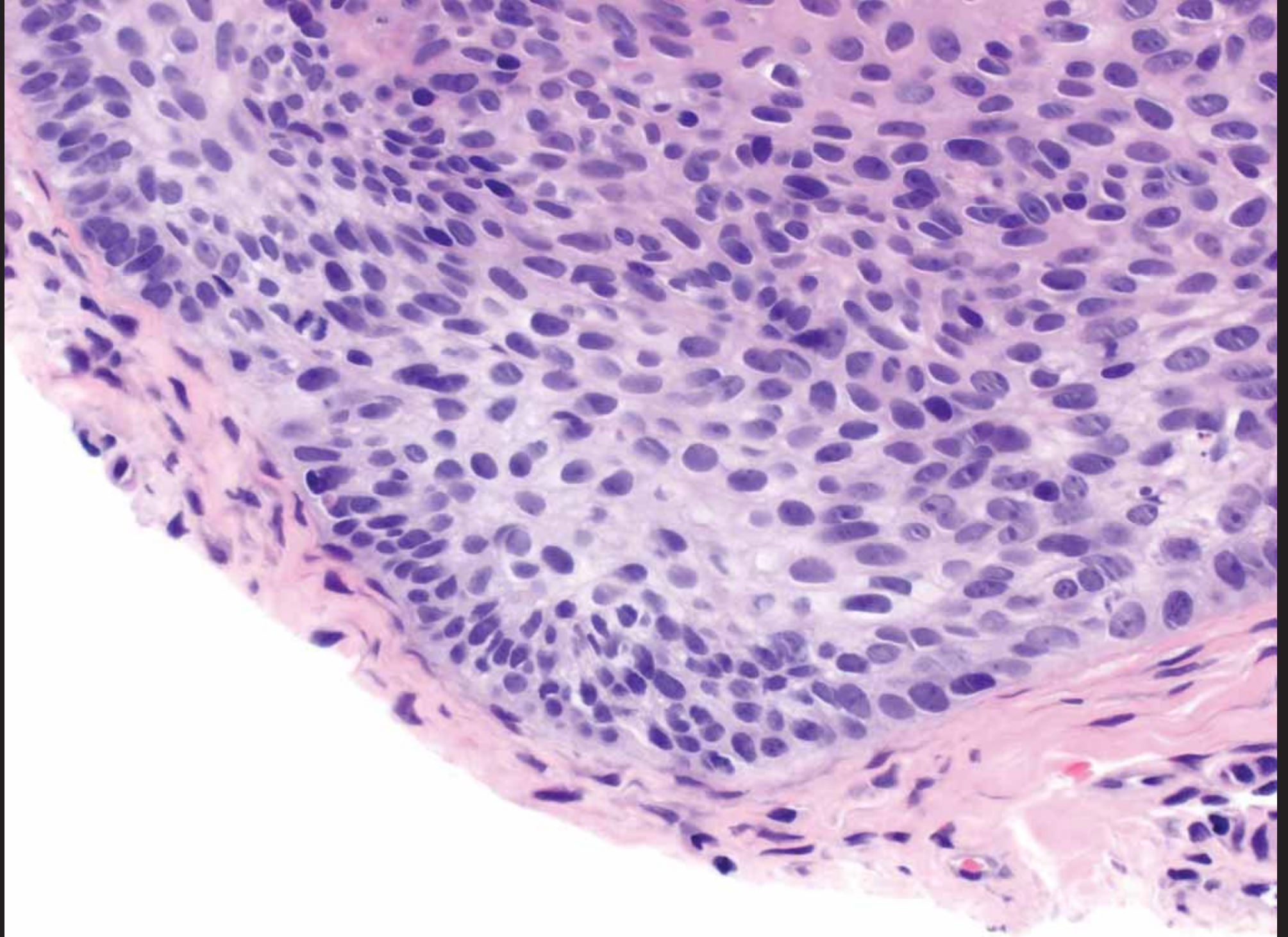
*But there is a true desmoplastic  
trichilemmoma- desmoplastic sui  
generis*

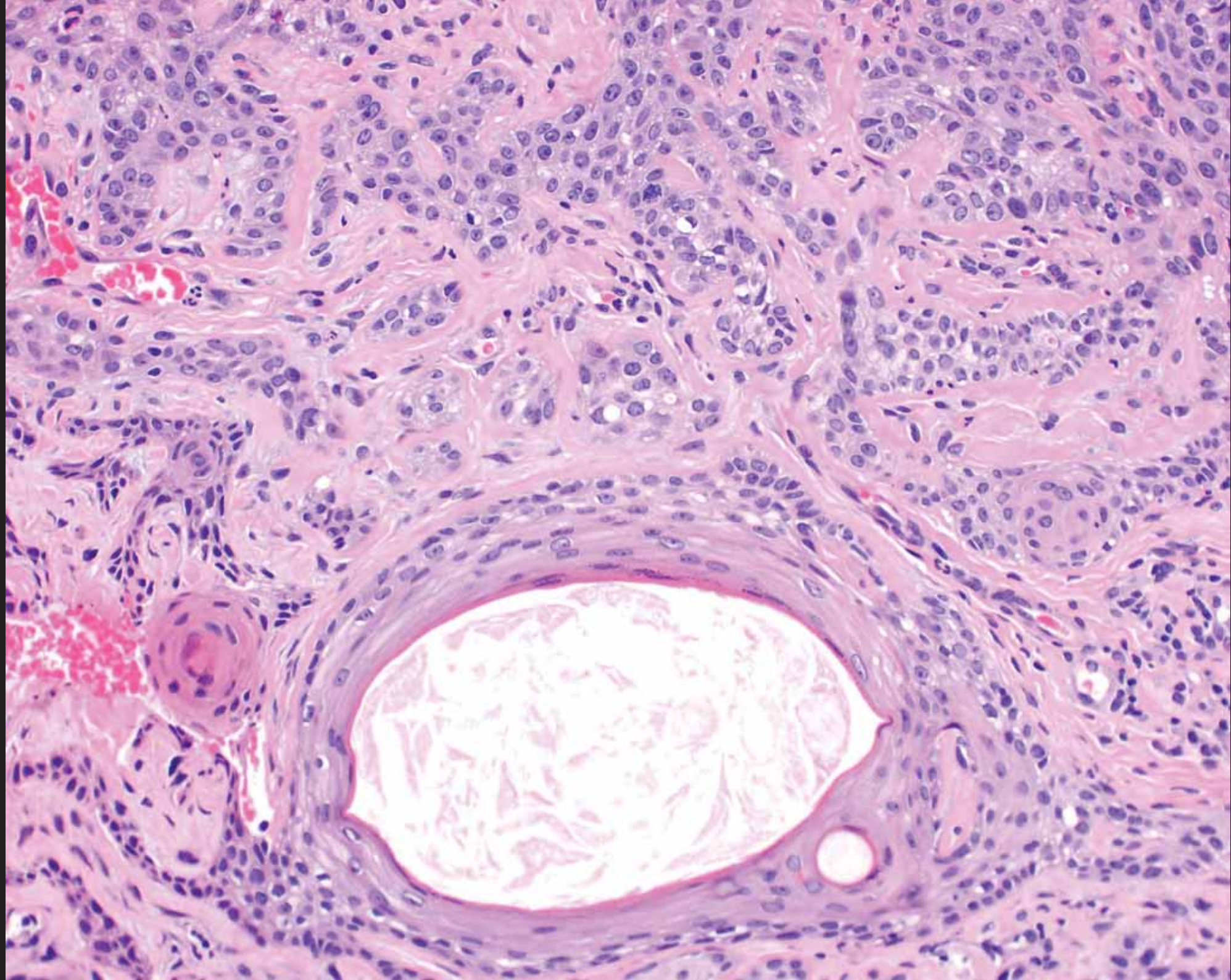
73 year-old man, nasal tip.

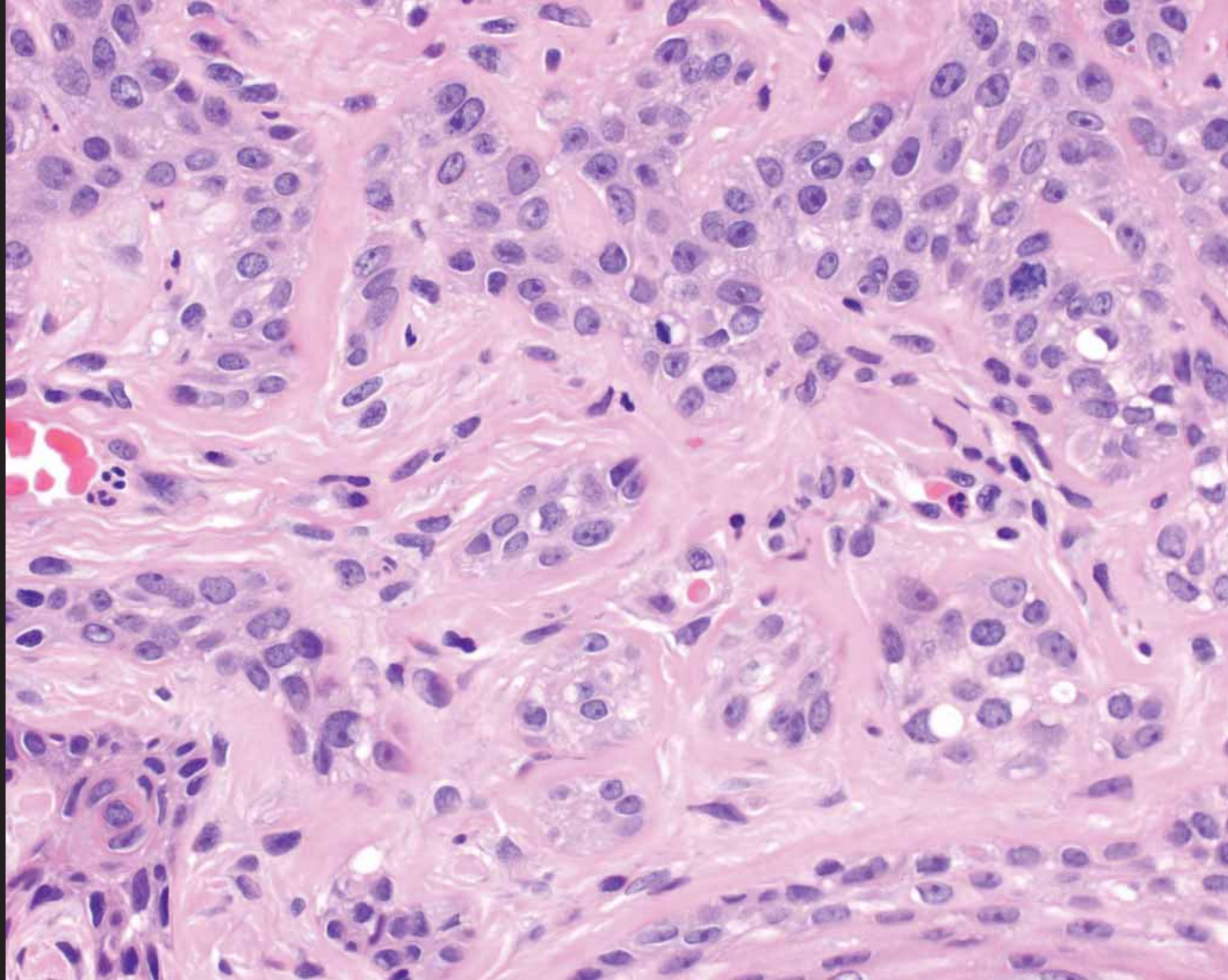
*Clinical diagnosis: NUB.*

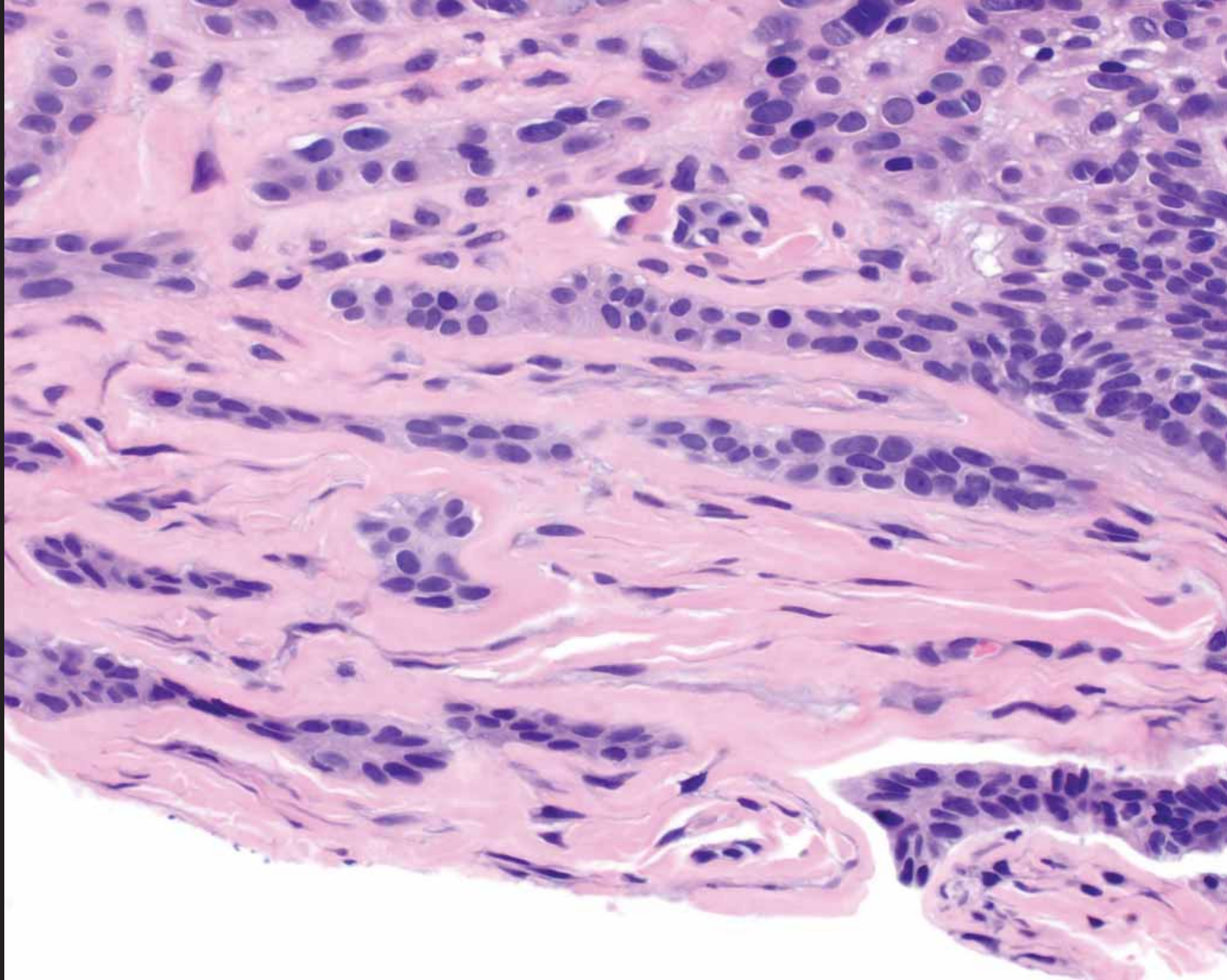




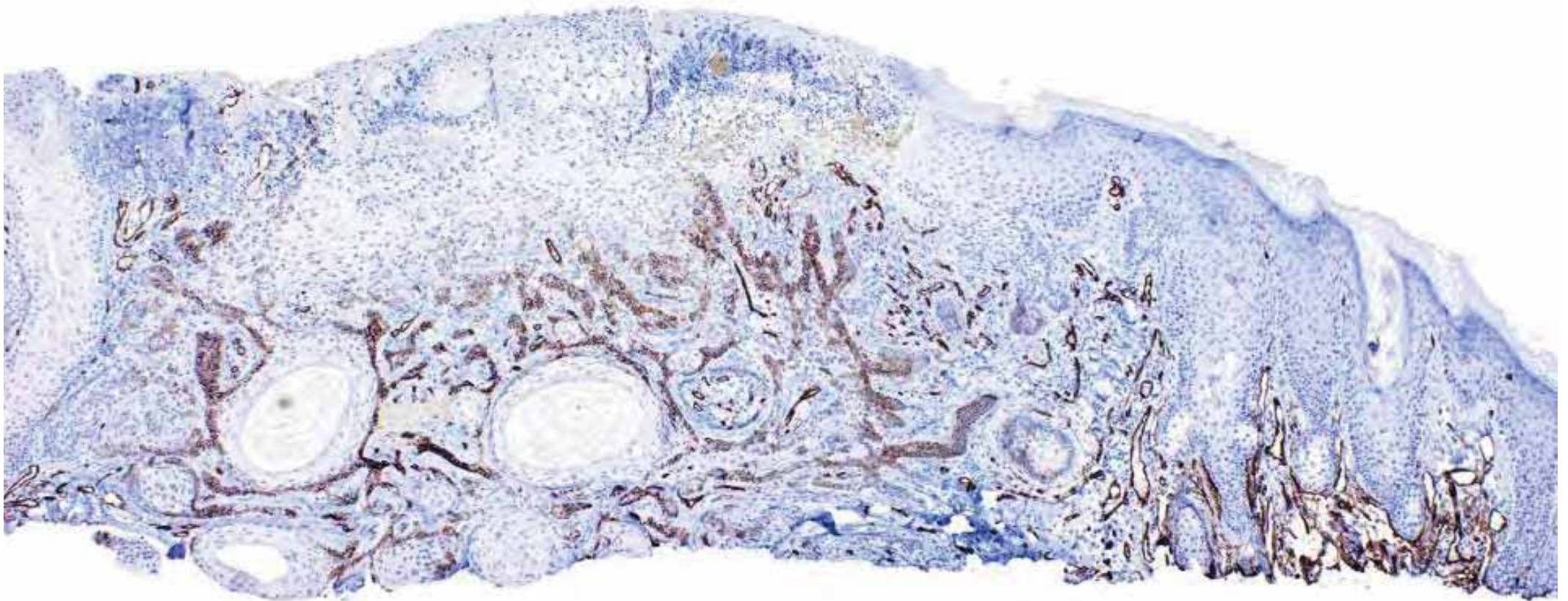


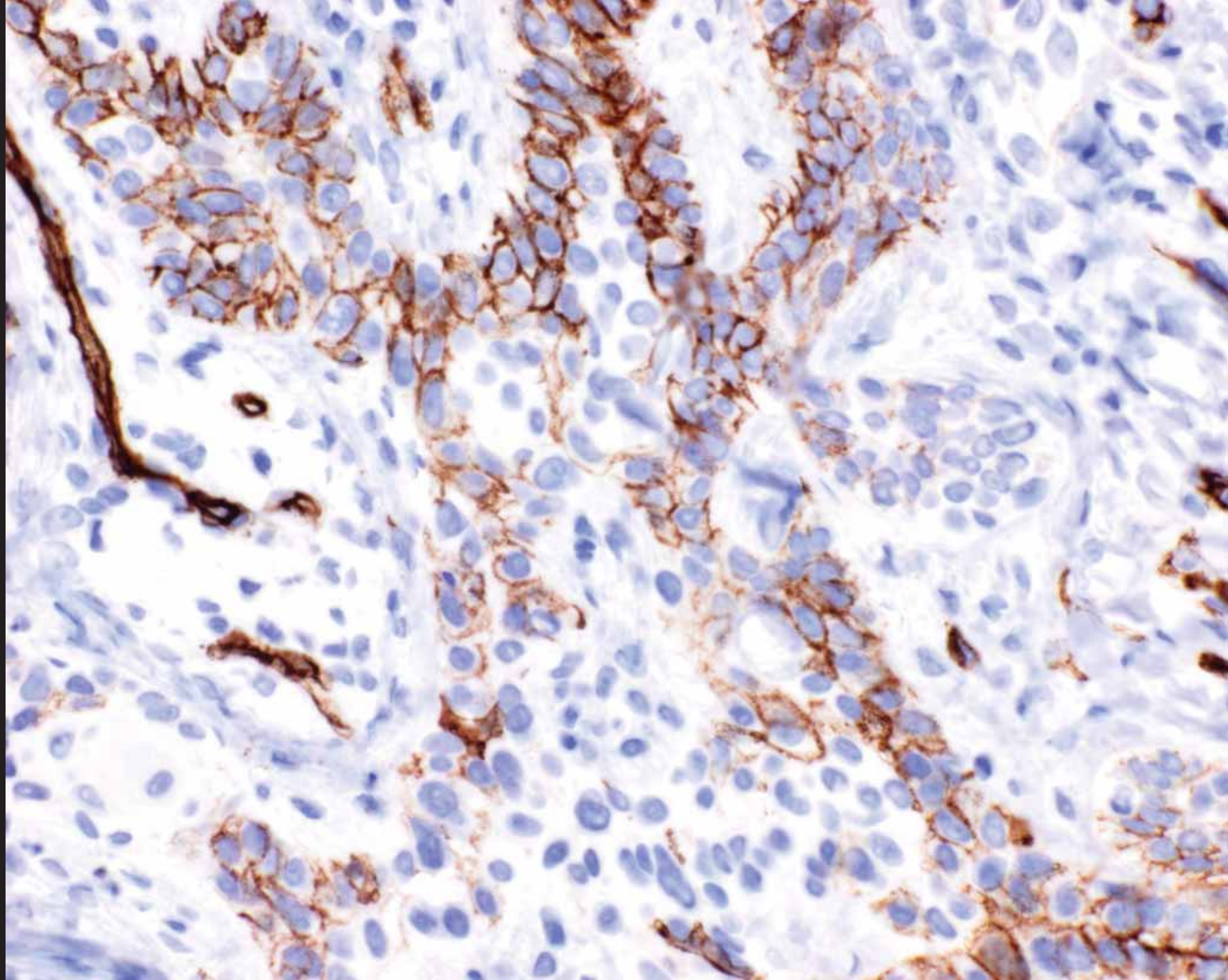




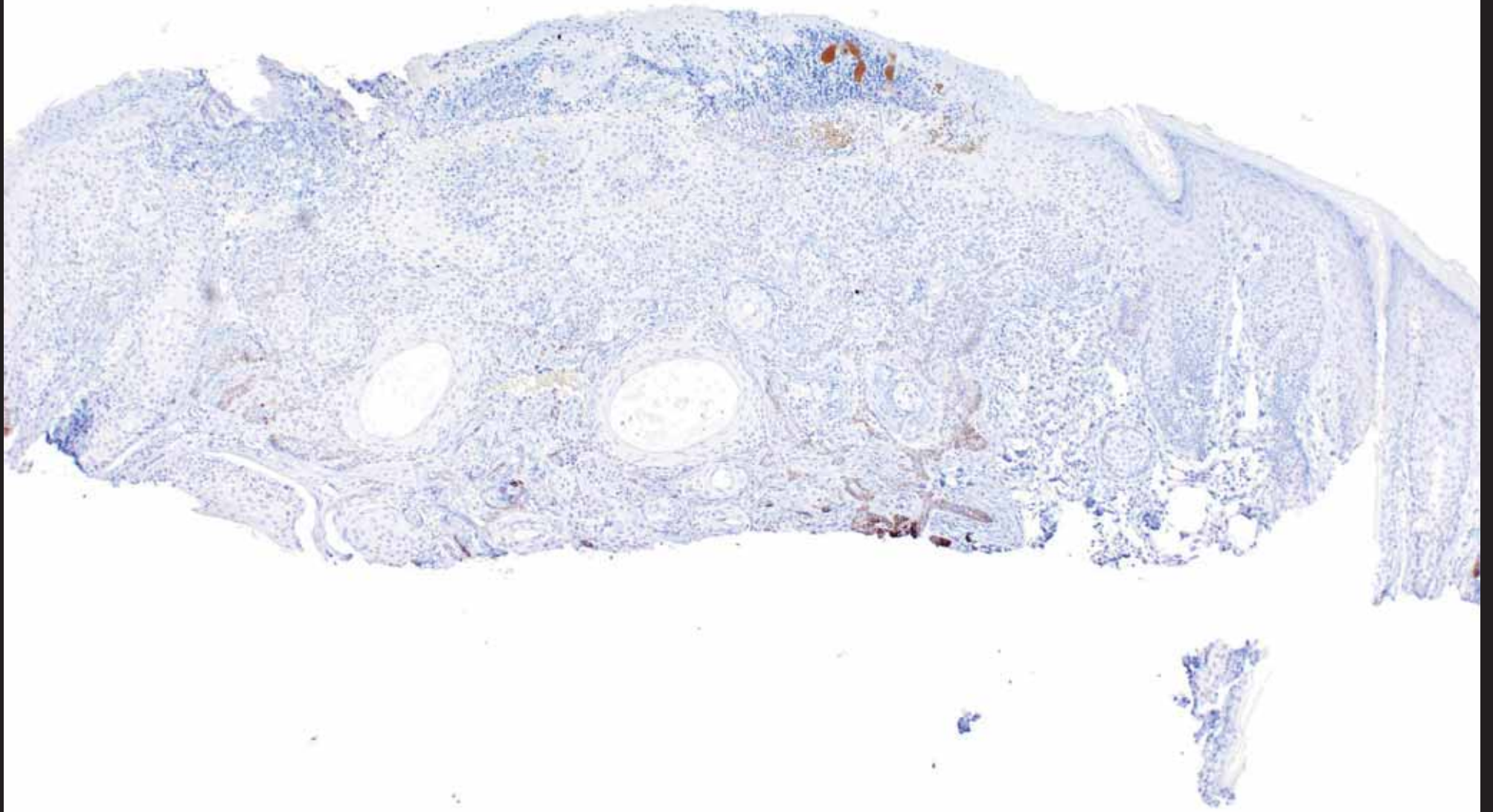


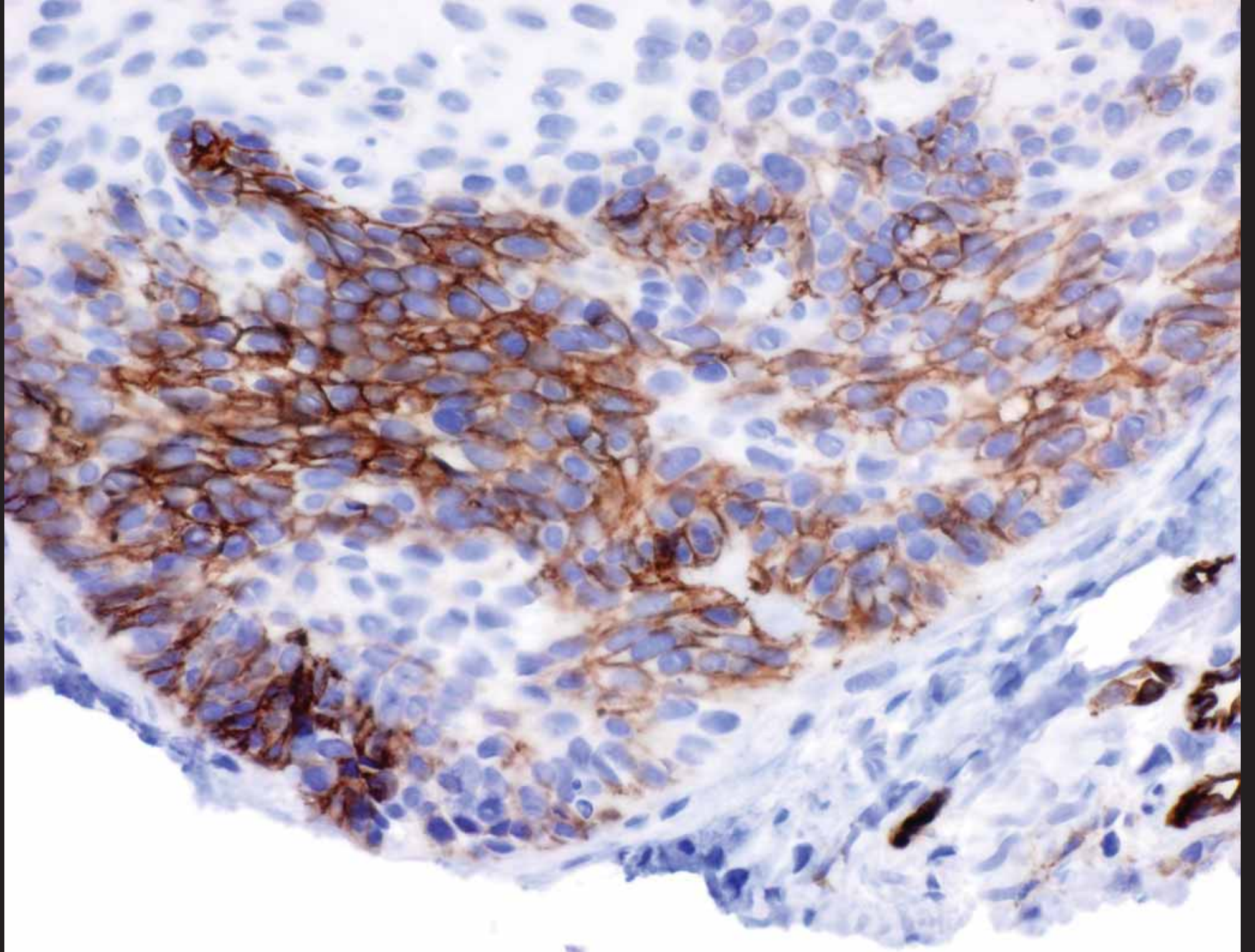
# CD34

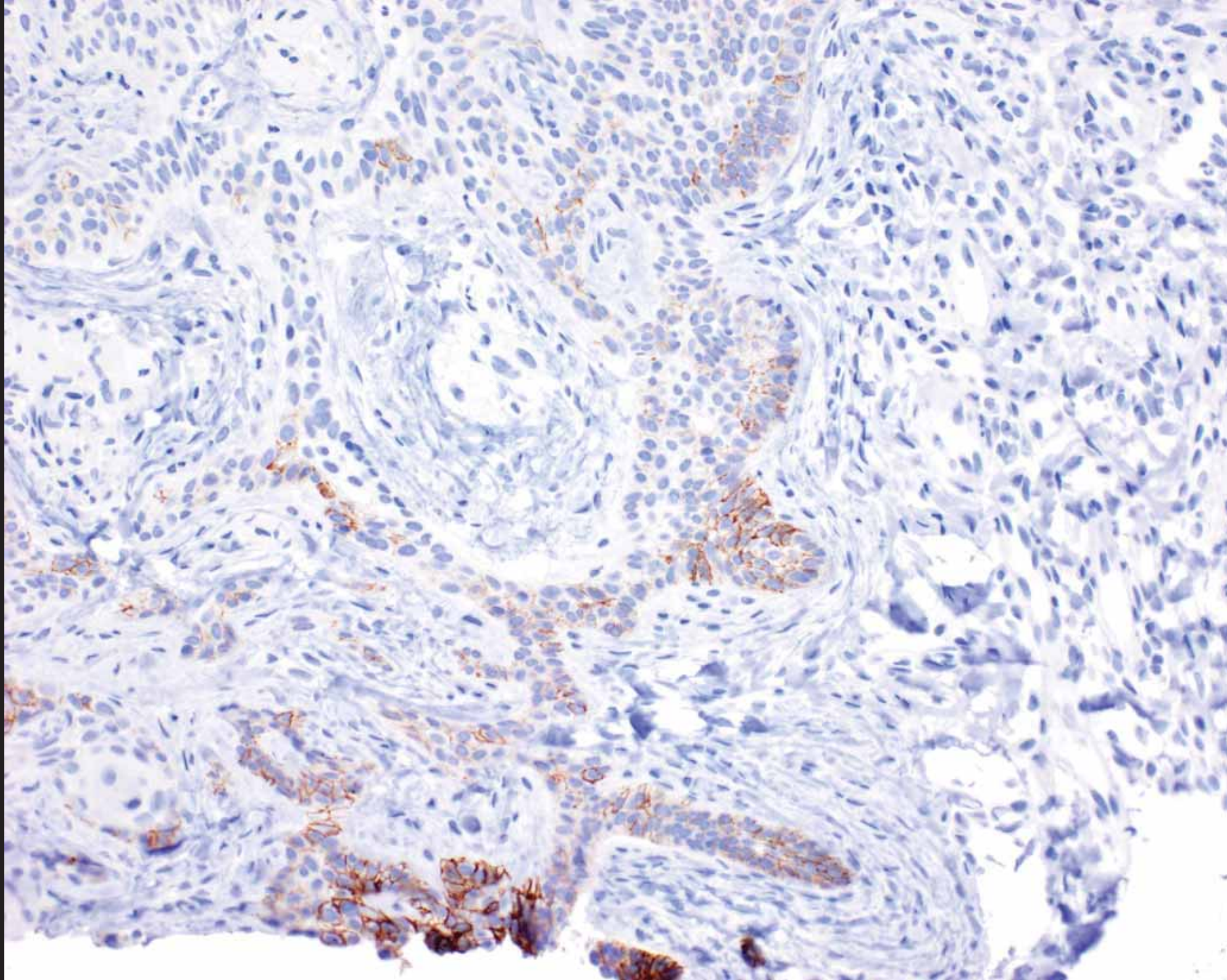




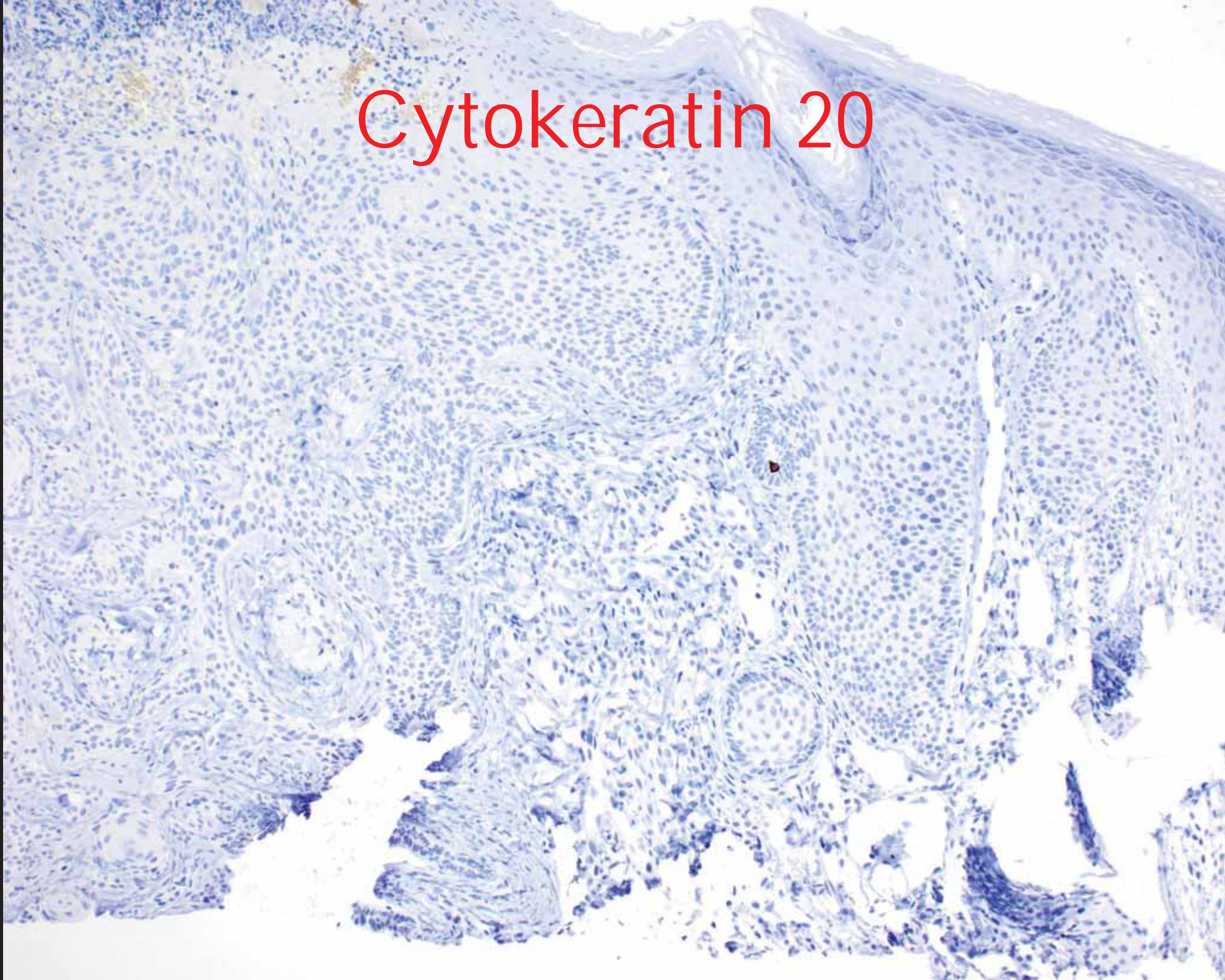
# Ber-EP4





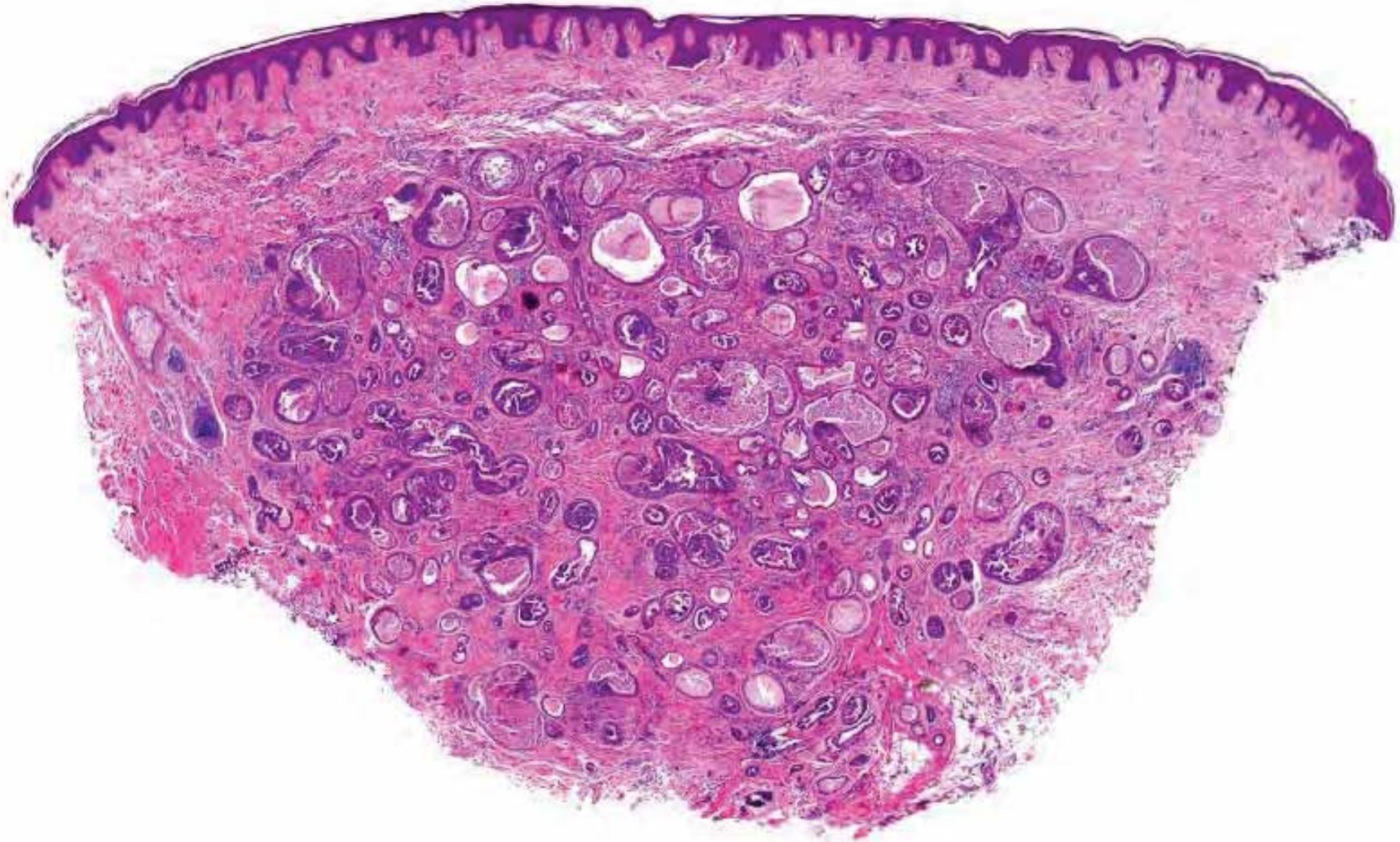


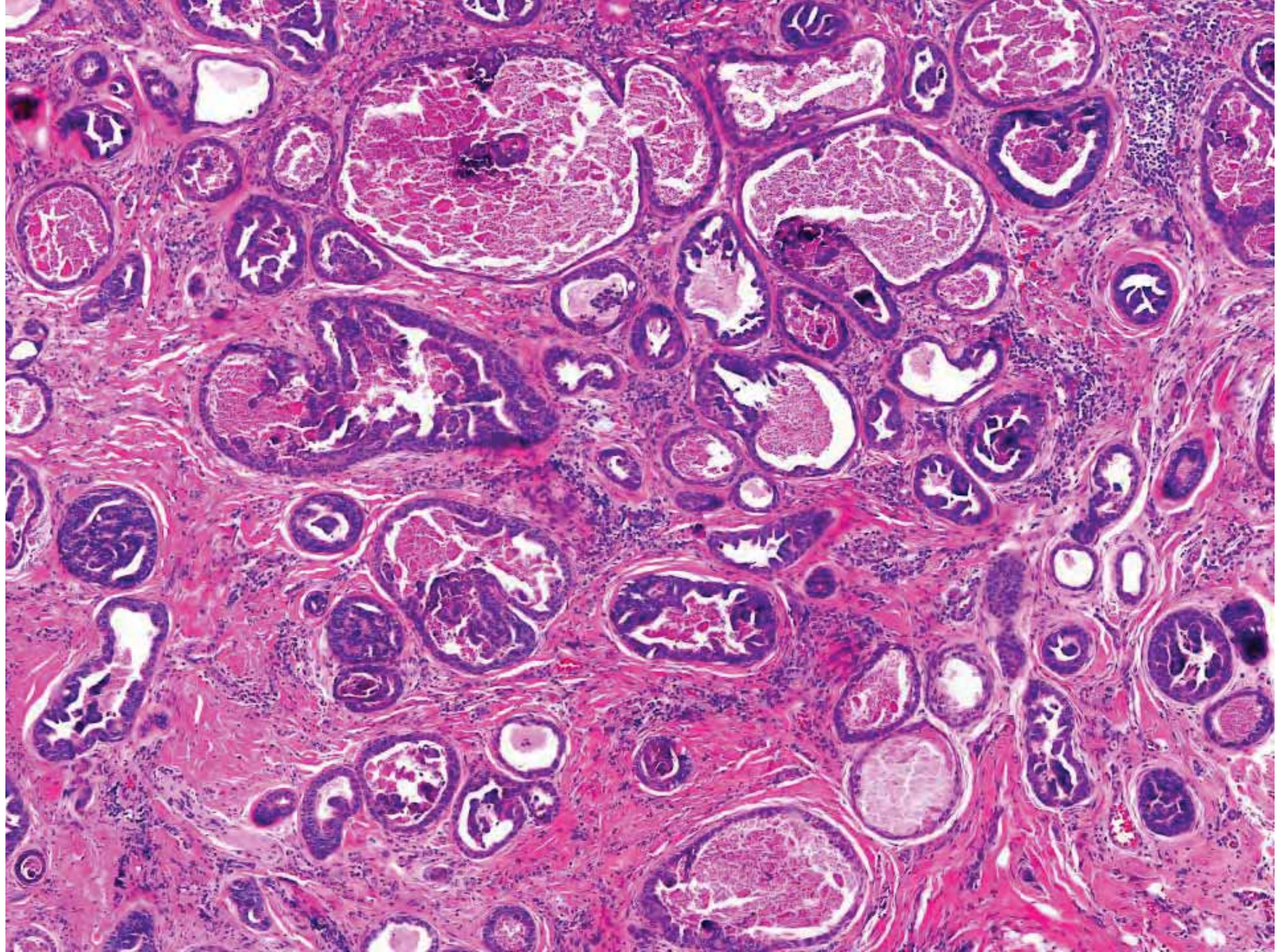
# Cytokeratin 20

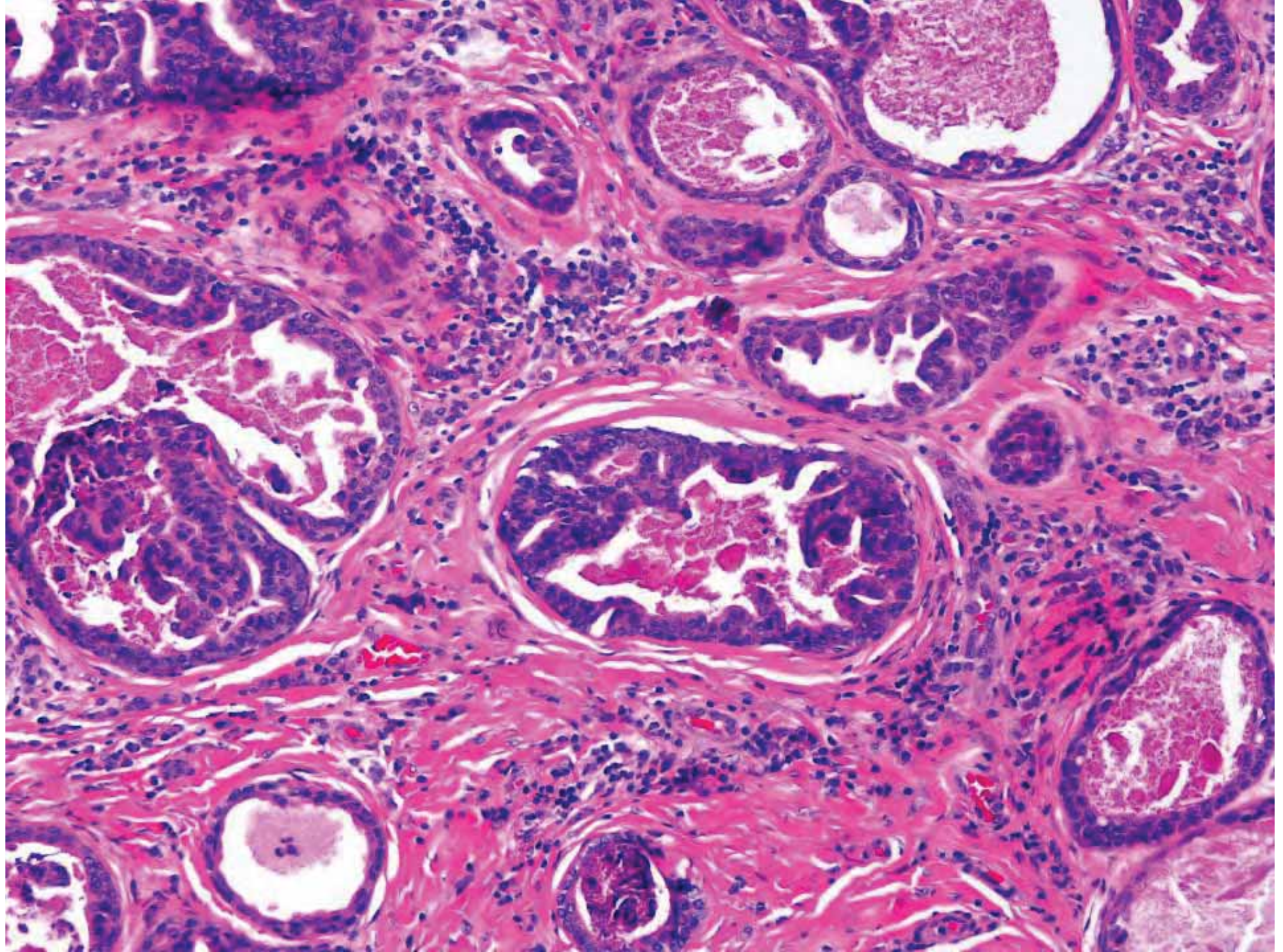


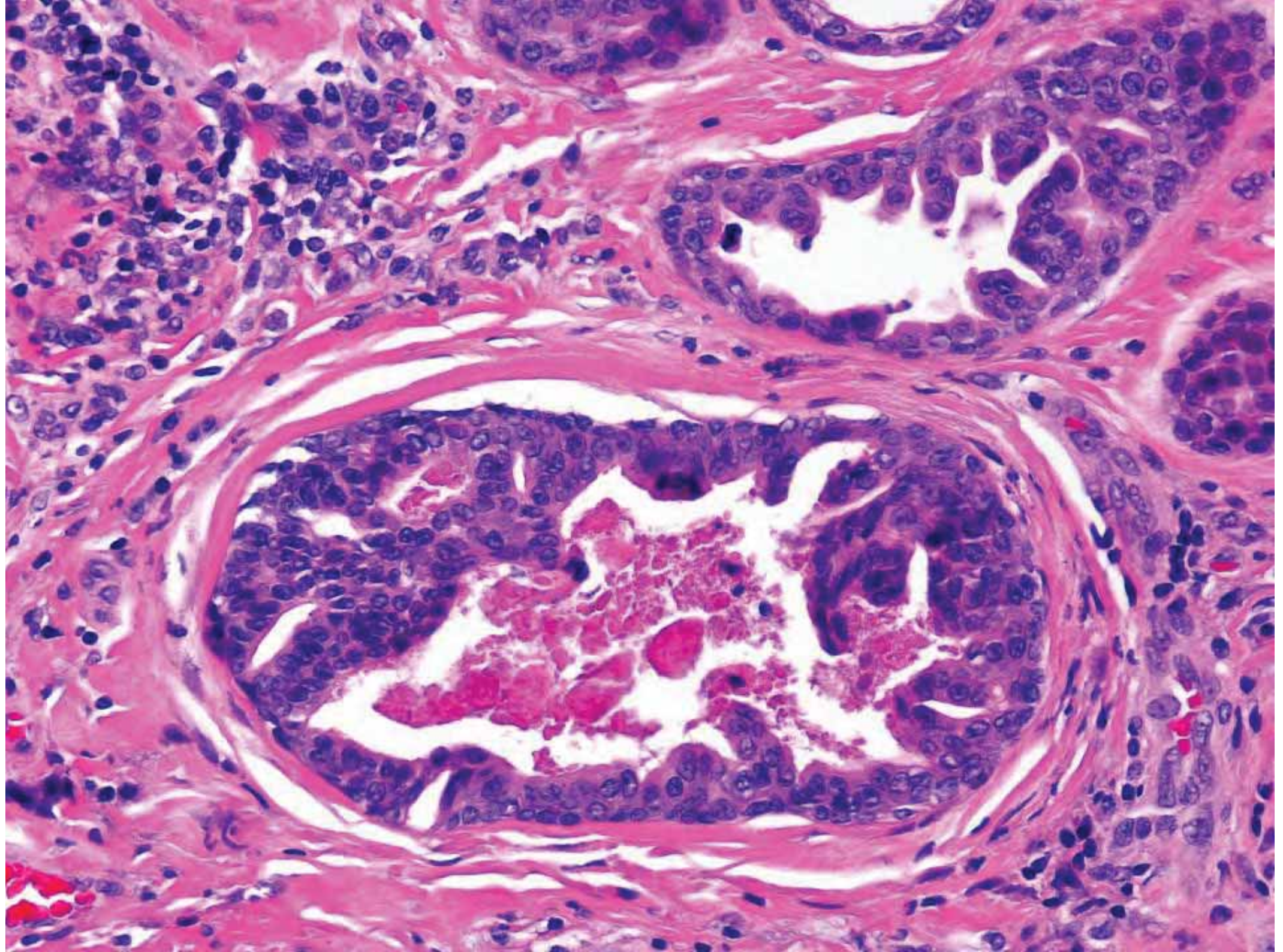
Low grade papillary/tubular  
adenomacarcinoma

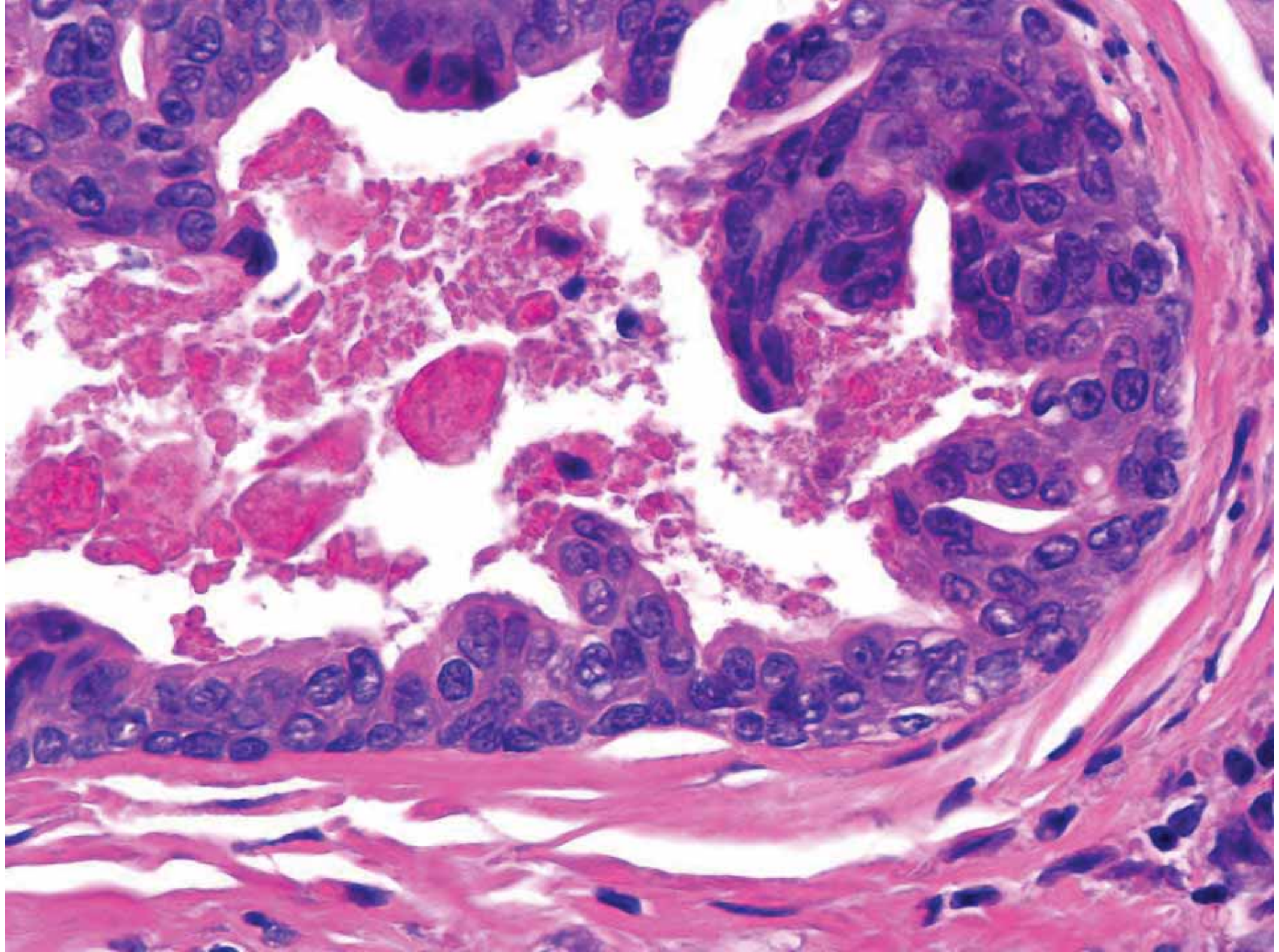
# Tubular and papillary/tubular adenoma

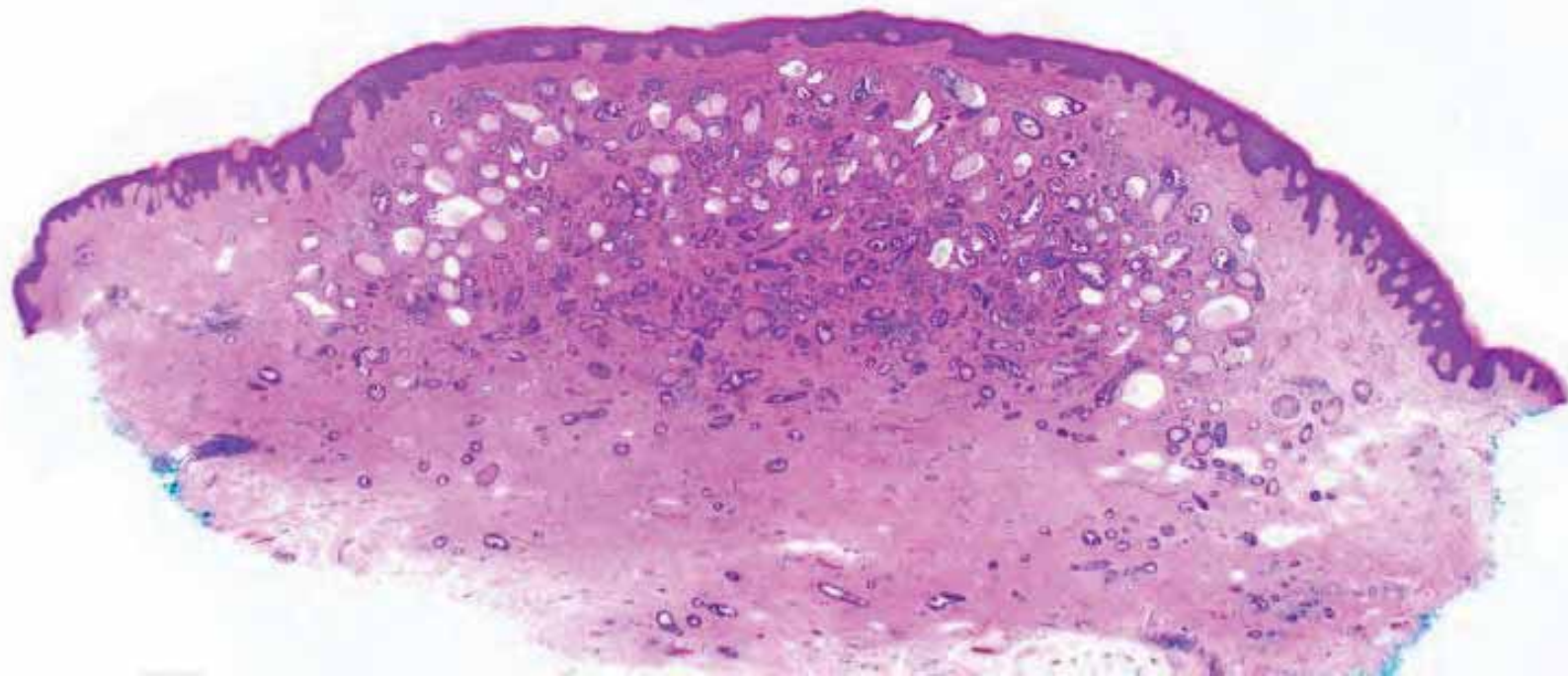
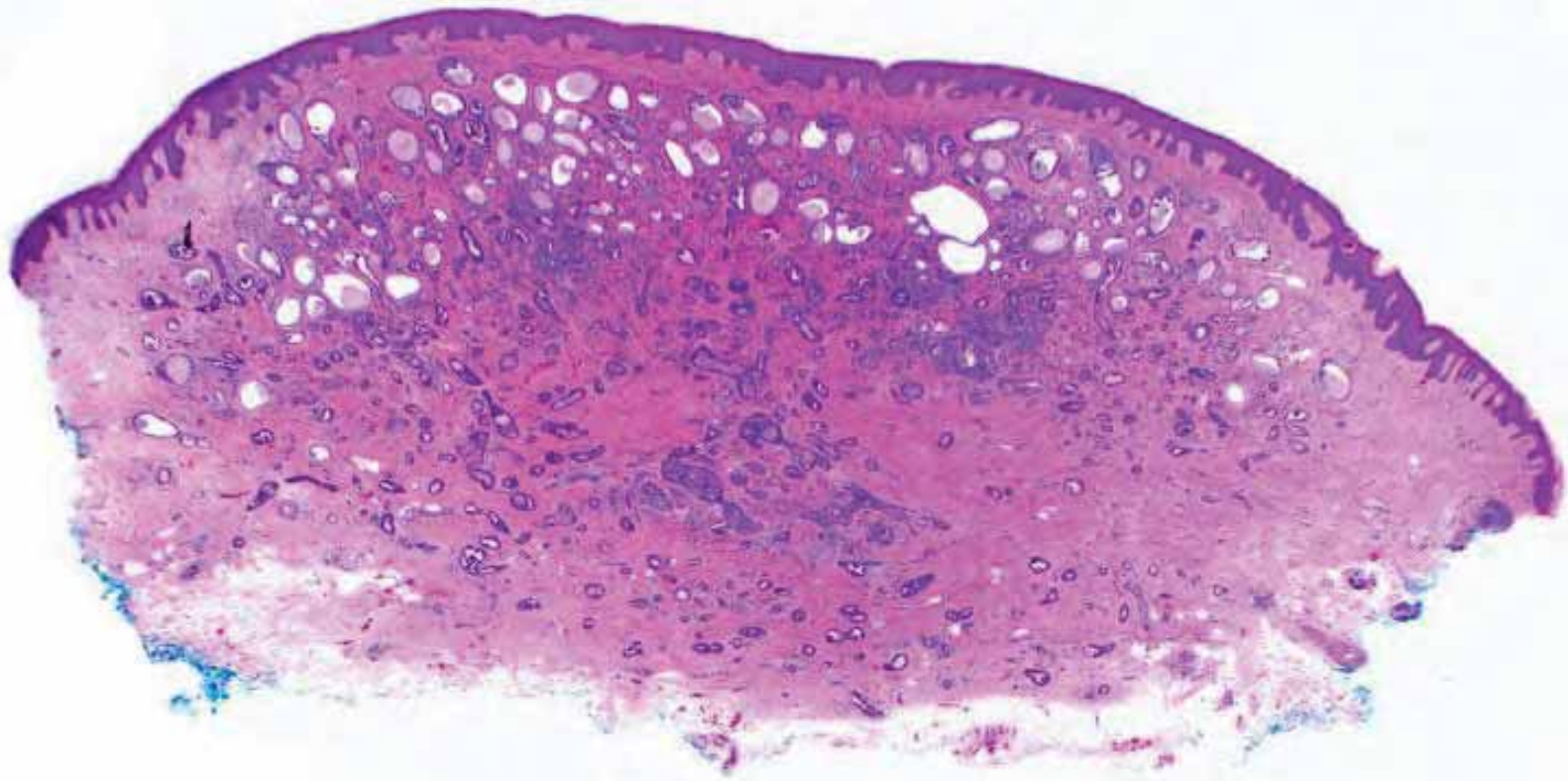


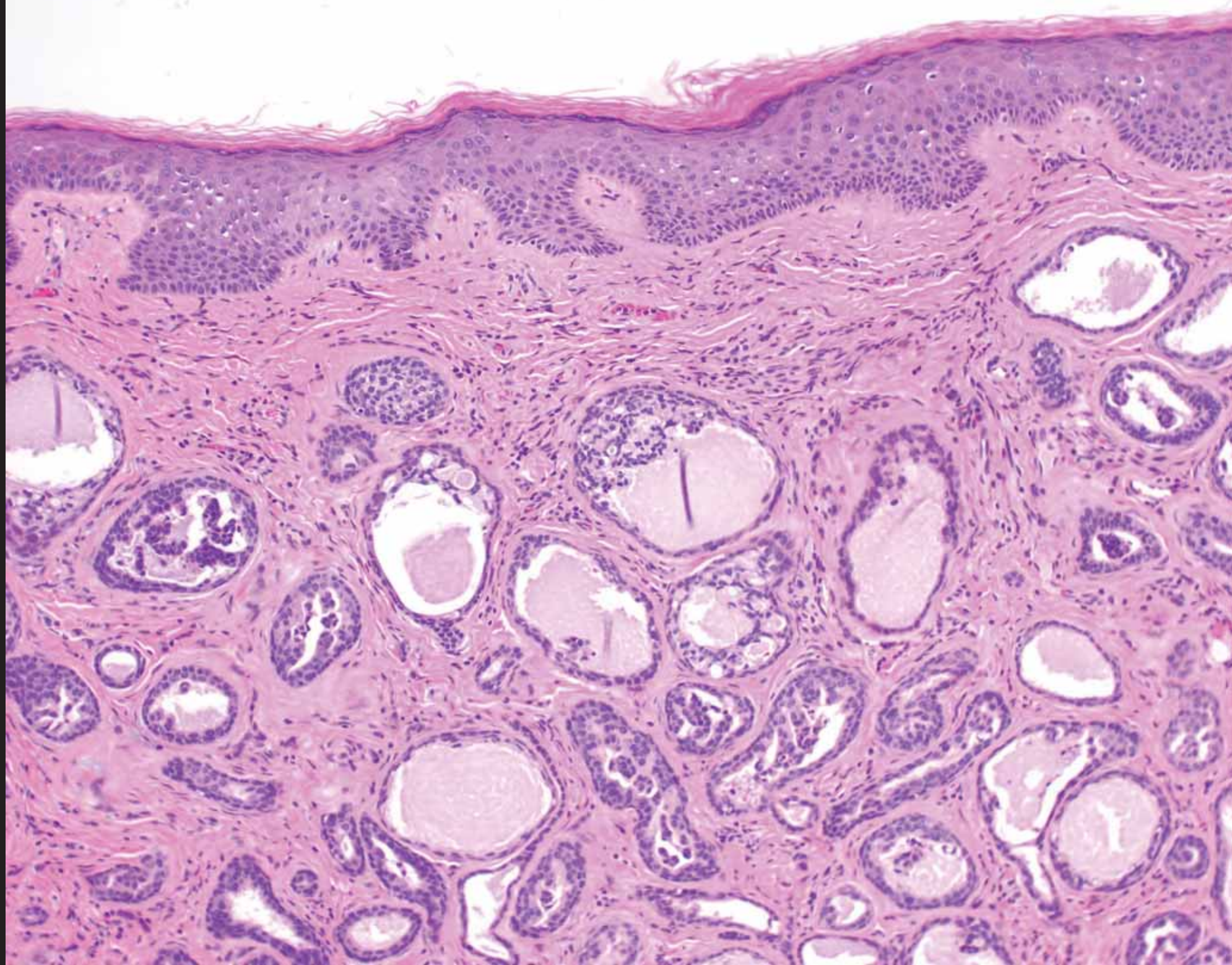


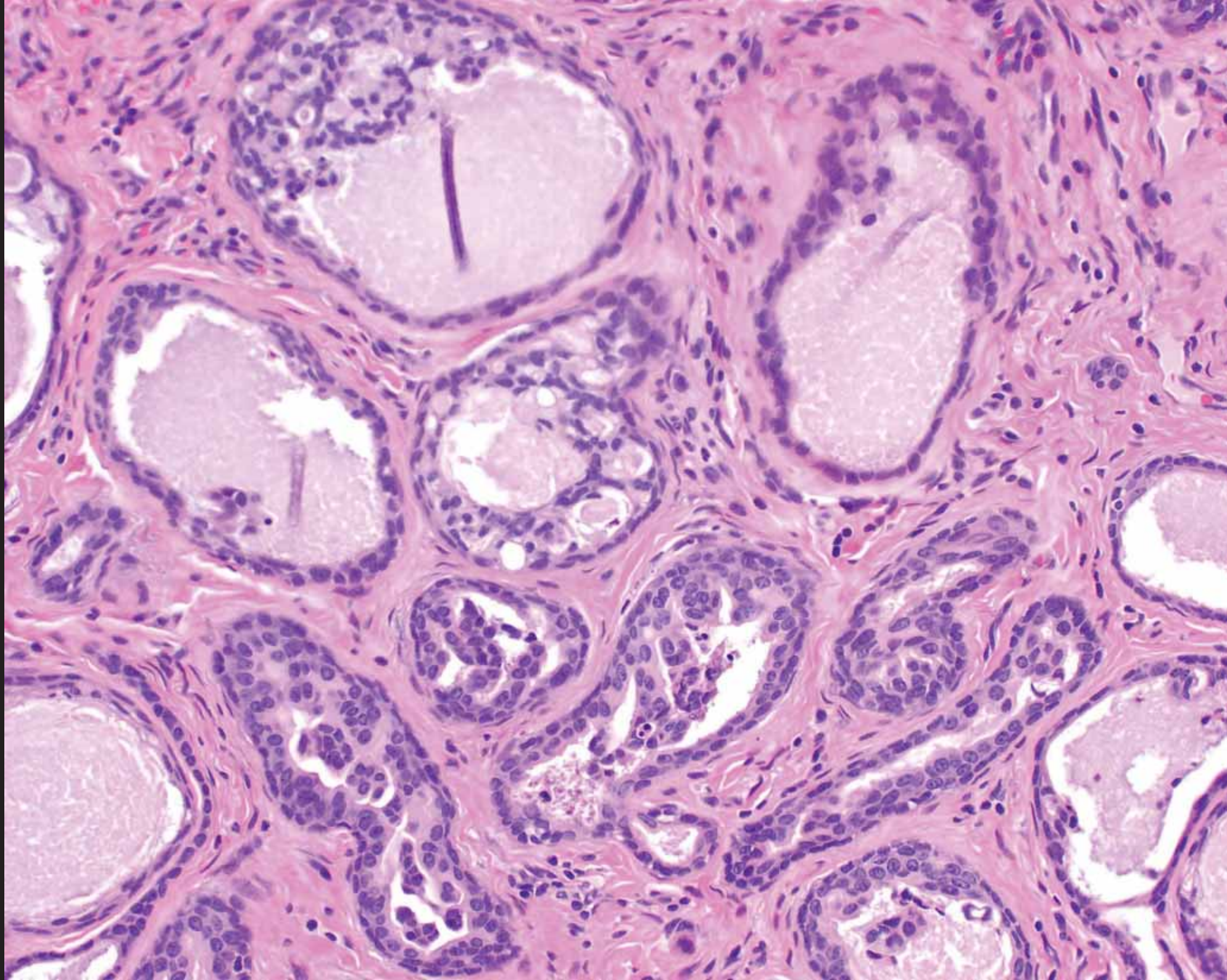


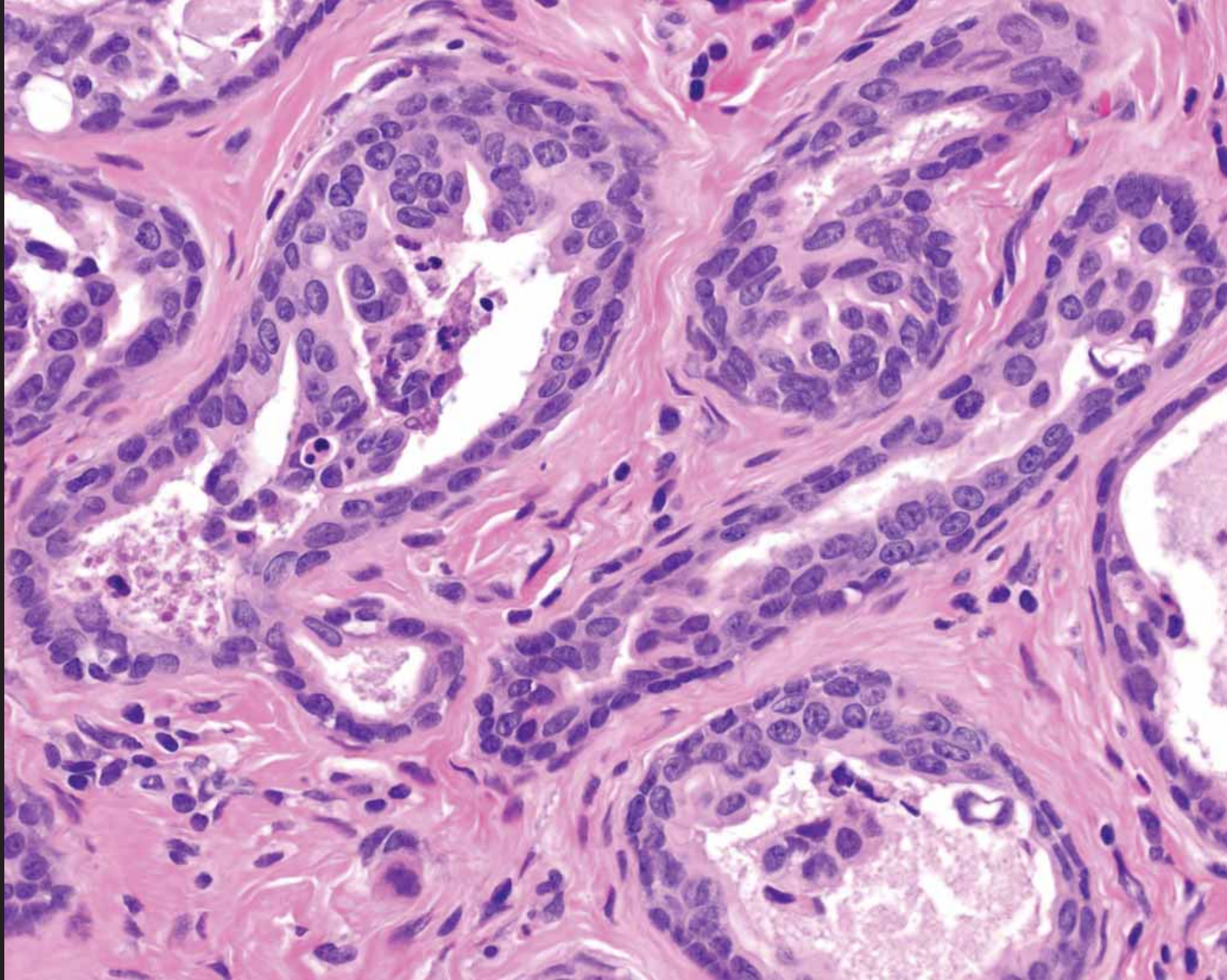


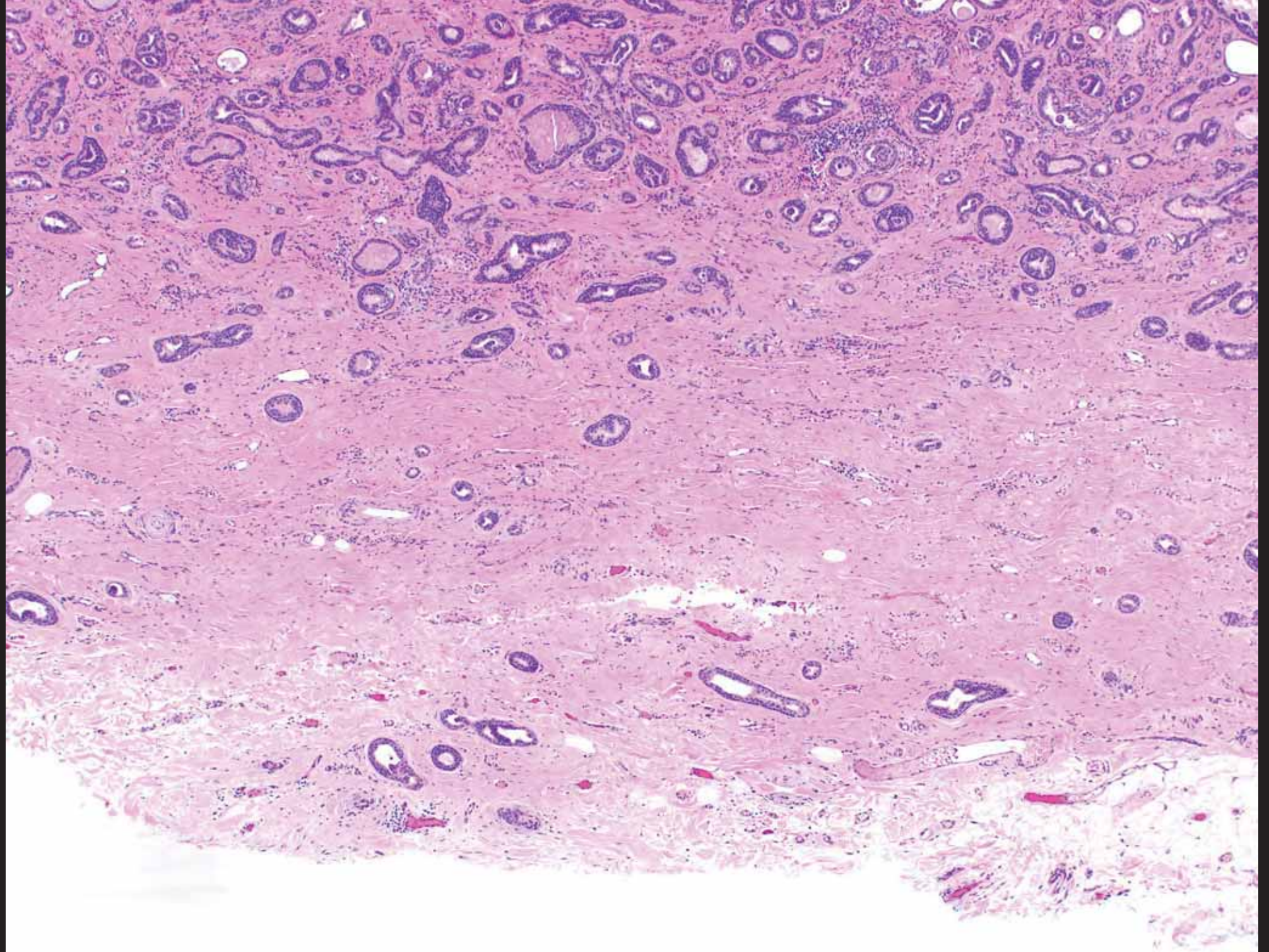


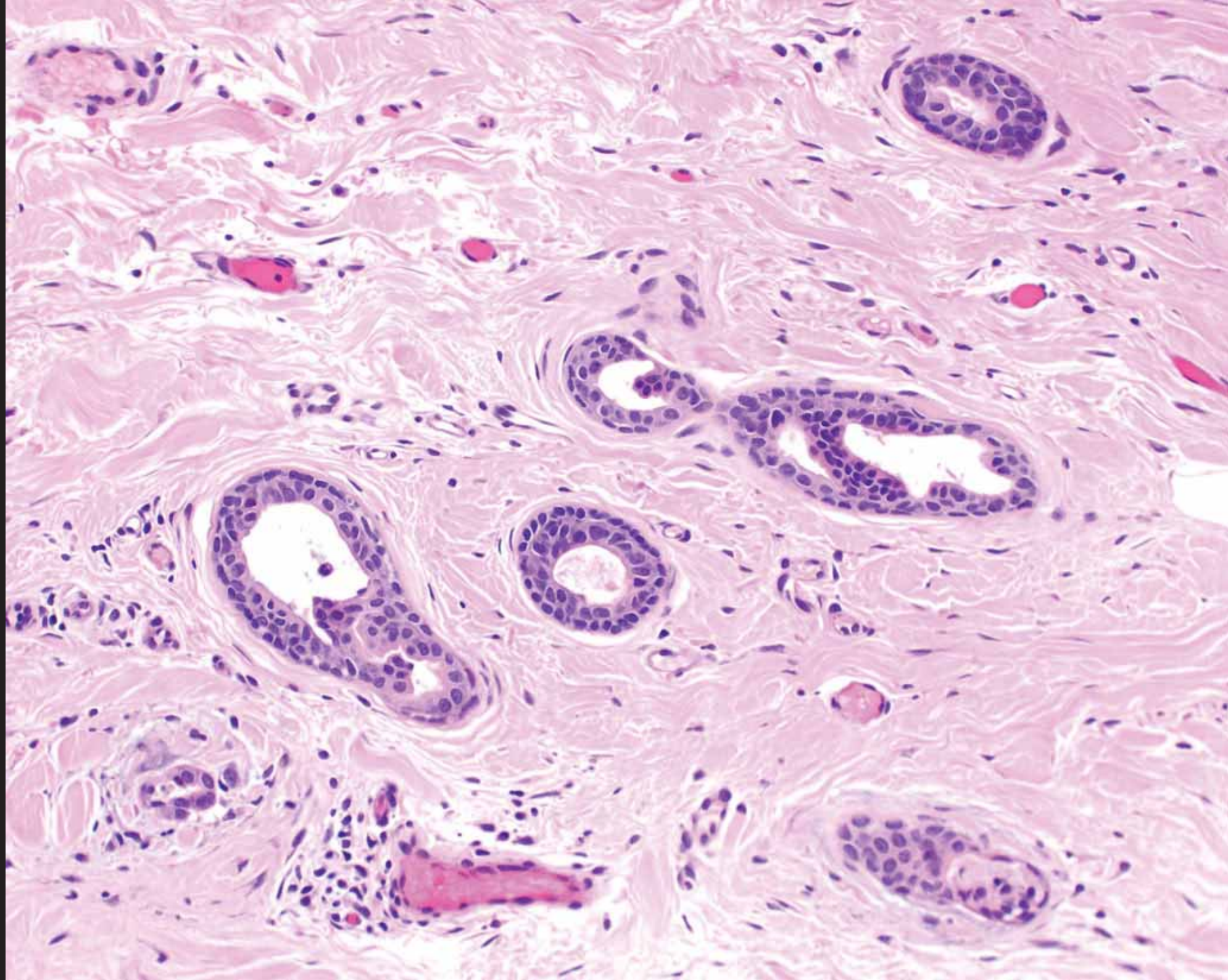


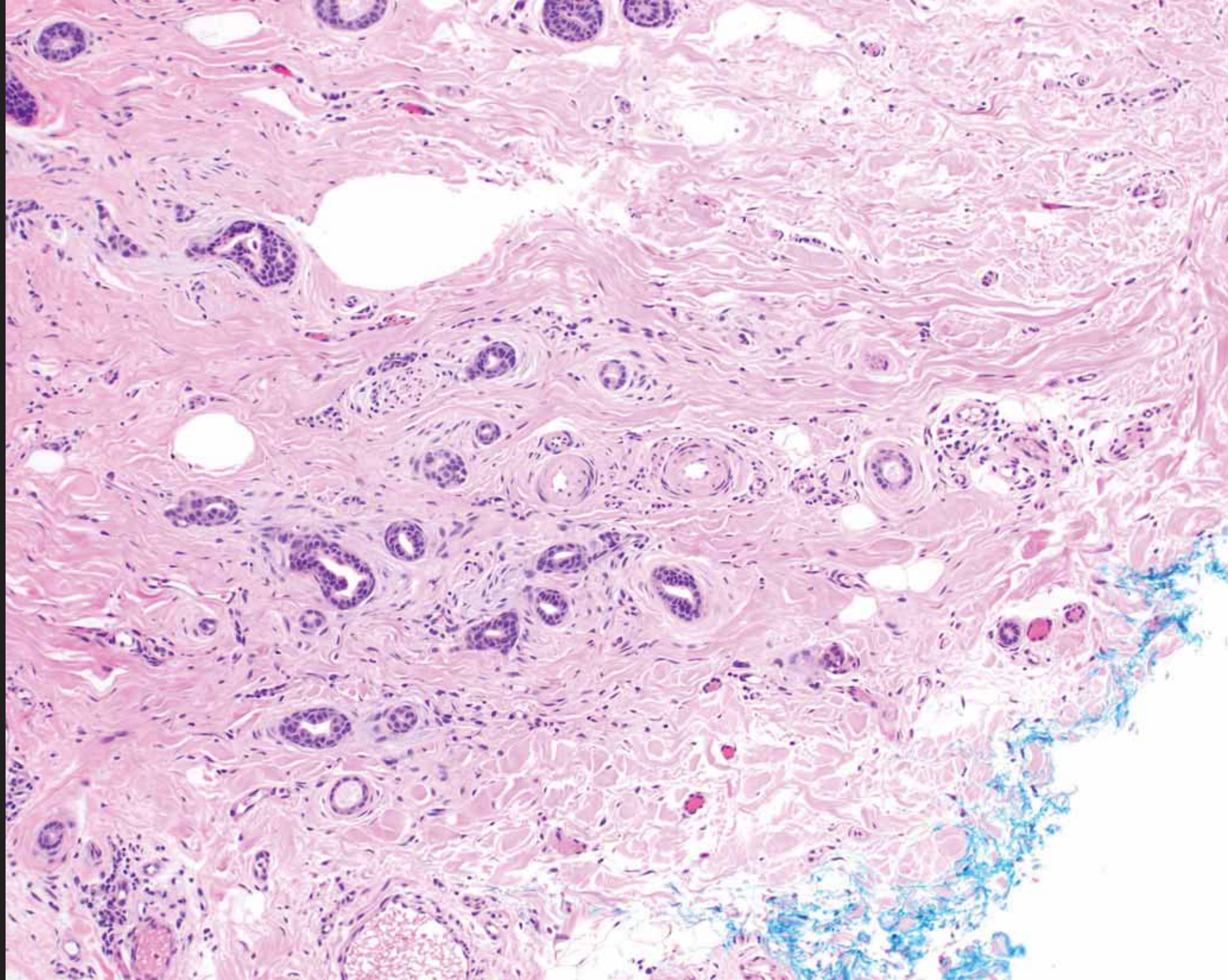


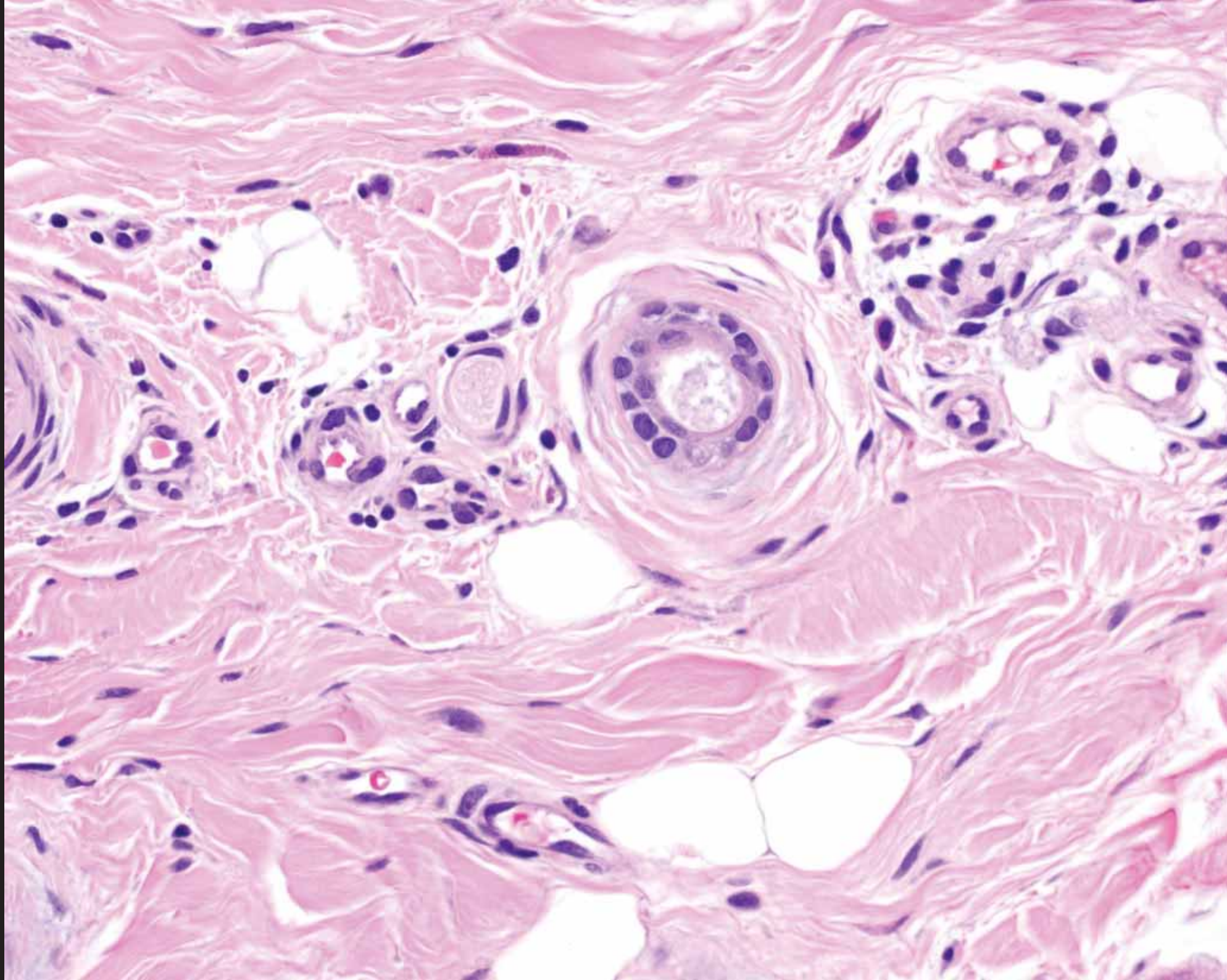












Clinical Reference / Dermatopathology: Practical & Conceptual / Oct – Dec 2003 | Vol. 9, No. 4 / Papillary eccrine adenoma is apocrine papillary carcinoma

## PAPILLARY ECCRINE ADENOMA IS APOCRINE PAPILLARY CARCINOMA

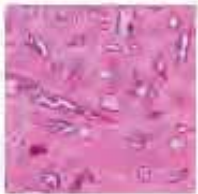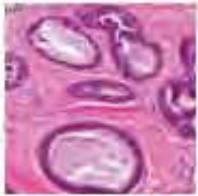Oct – Dec 2003 | Vol. 9, No. 4

---

Ackerman, A. Bernard; Denianke, Kwame

**THE ISSUE OF ECCRINE VERSUS APOCRINE DIFFERENTIATION OF CUTANEOUS NEOPLASMS AFFILIATED WITH TUBULES**

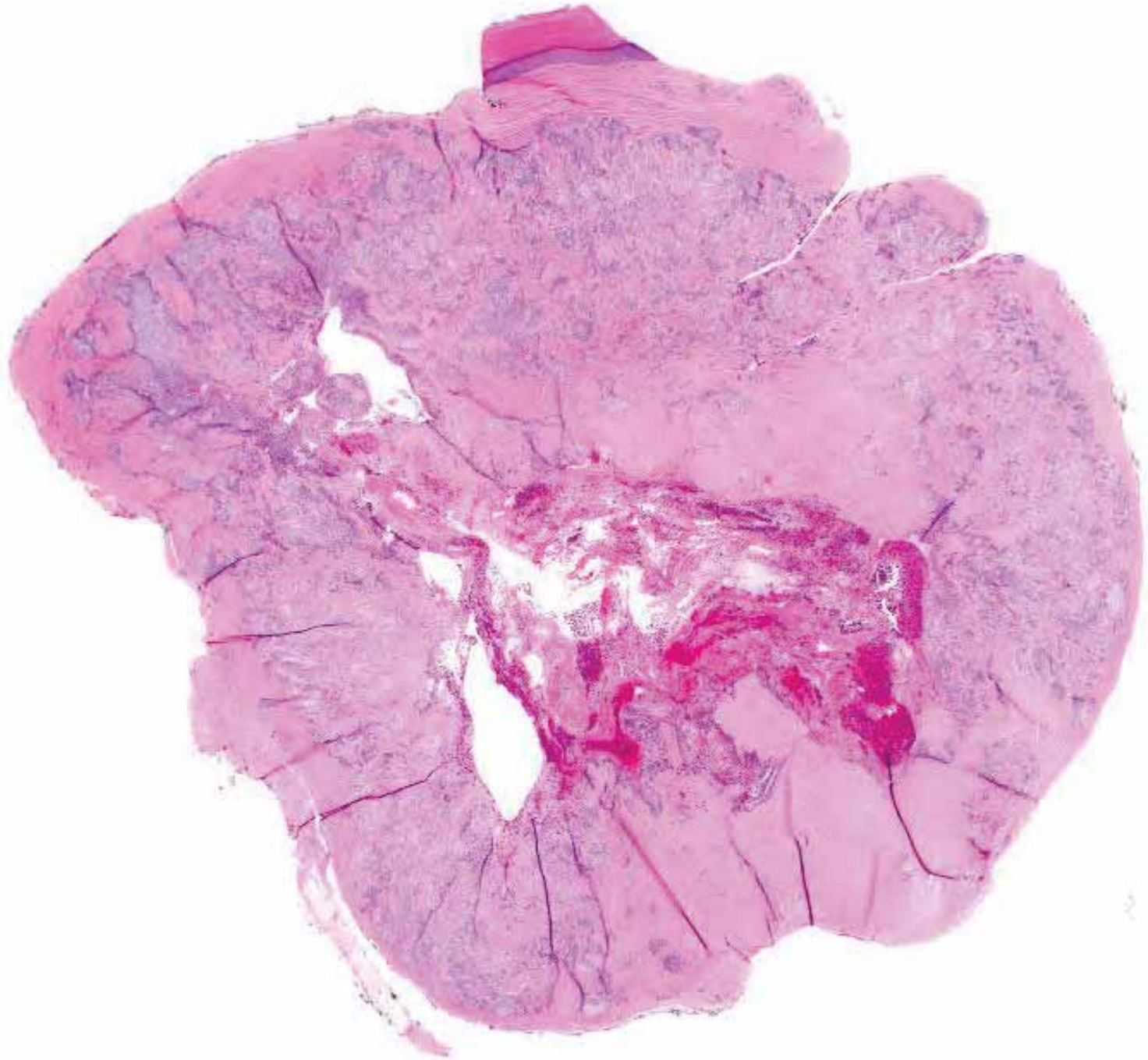
Figs. 5A-C

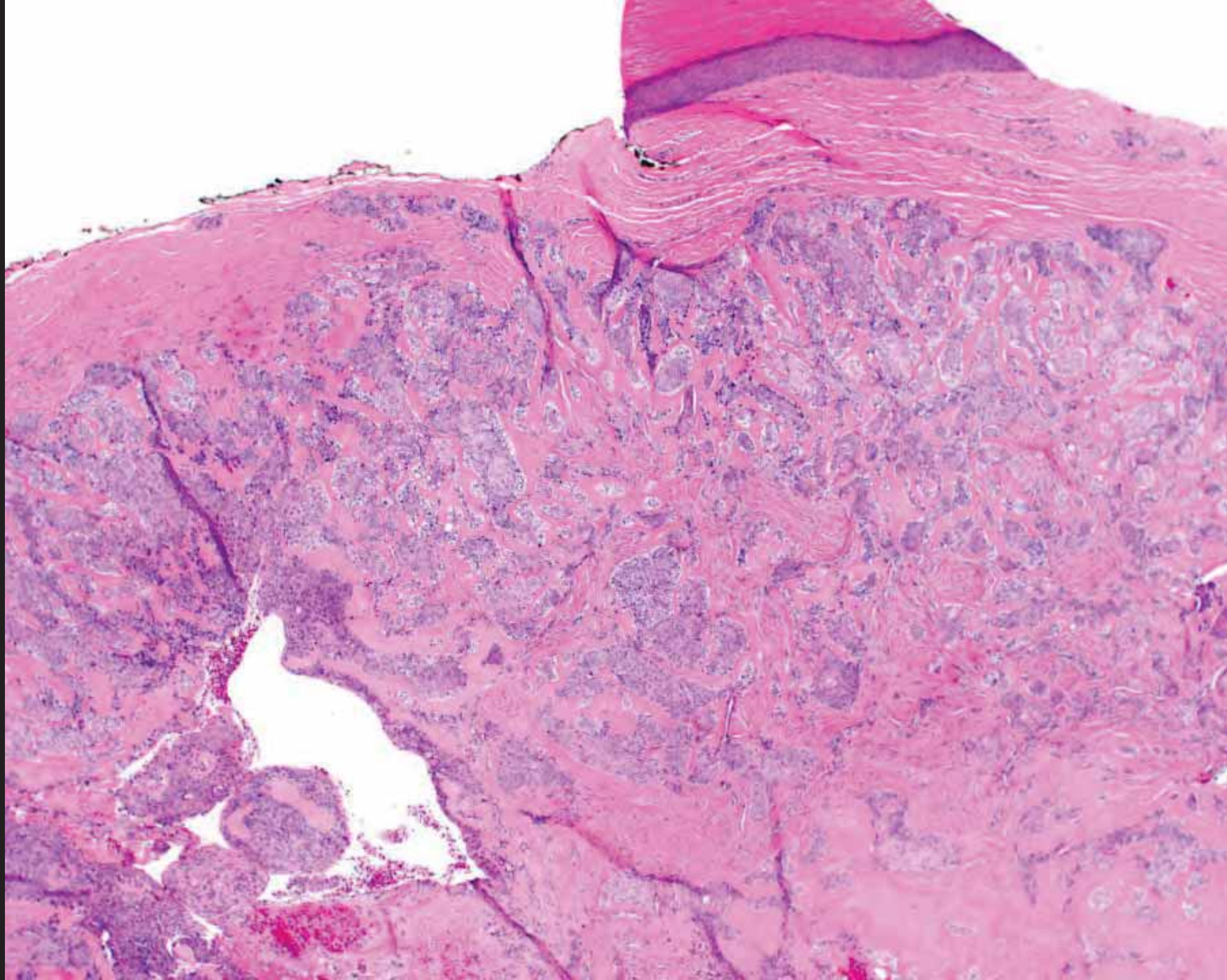


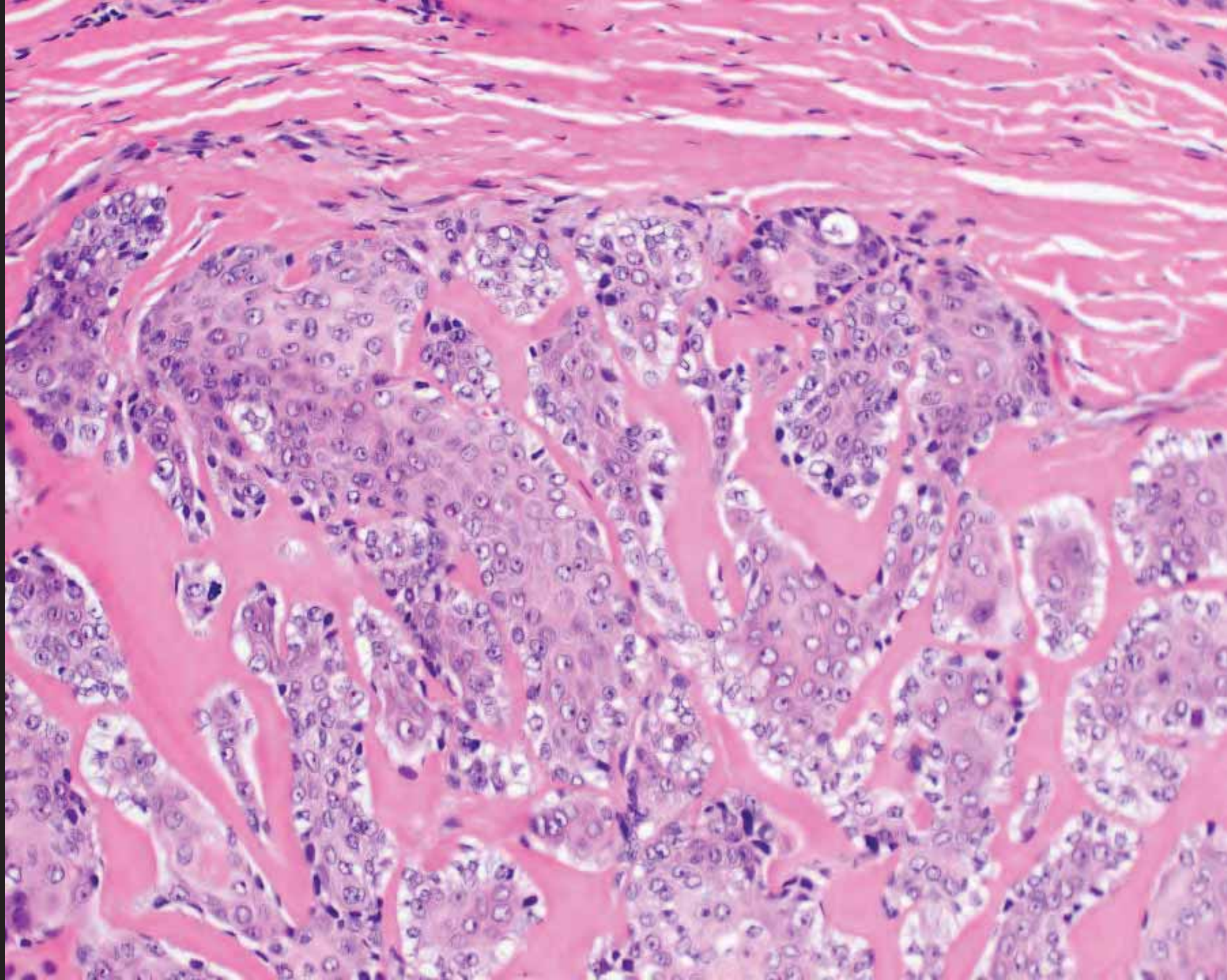
**Apocrine papillary carcinoma** This neoplasm that extends throughout the reticular dermis and well into the subcutaneous fat is malignant because of its silhouette and its cytopathologic attributes. Aggregations of epithelial cells punctuated by tubules are distributed randomly, they vary considerably in size and shape, and some have assumed peculiar geometric outlines. Moreover, at higher magnification, nuclei seem to be crowded and pleomorphic; some were in mitosis. There also are foci of necrosis *en masse*. In sum, this is an apocrine papillary carcinoma.

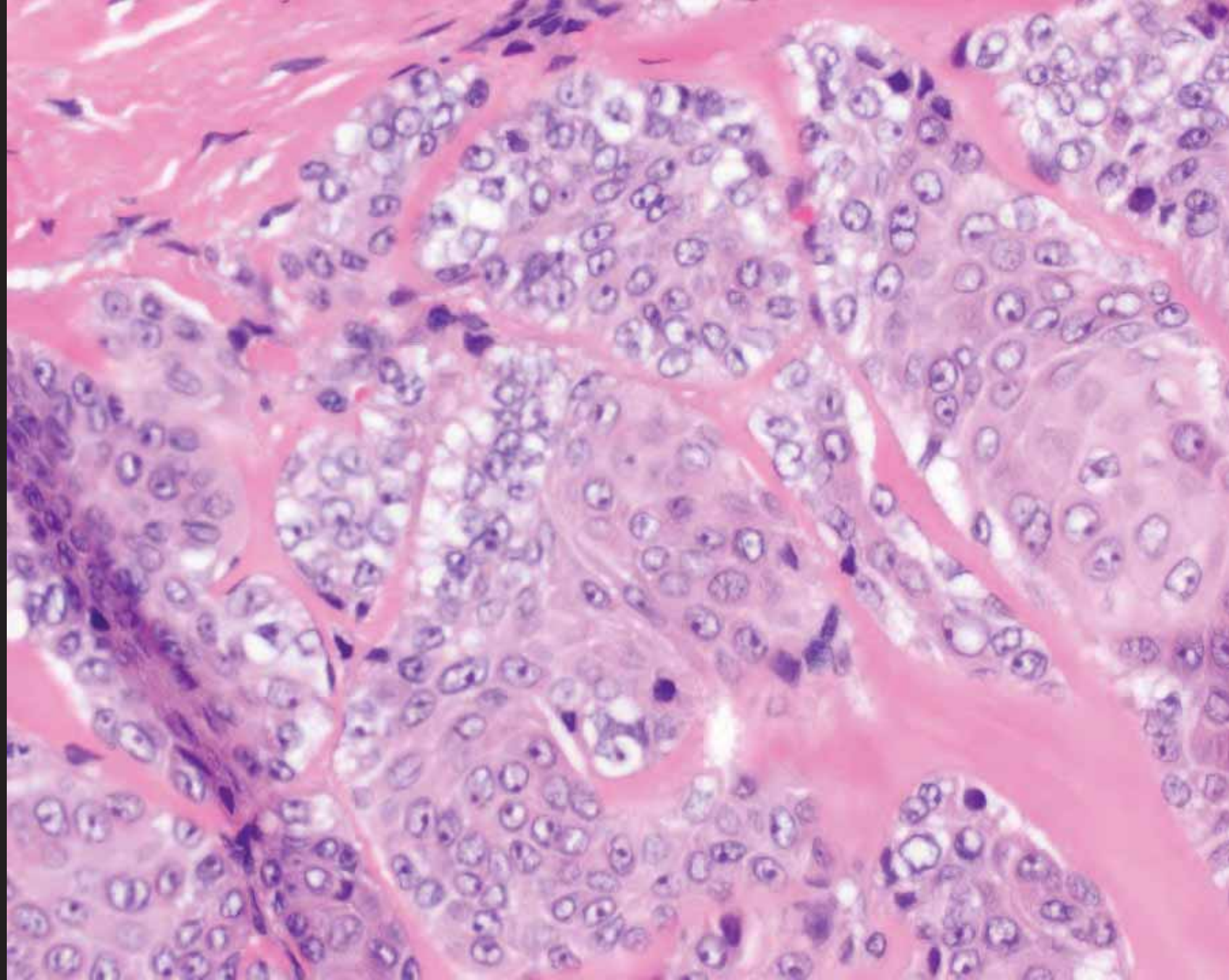
Desmoplastic hidradenoma and  
? Desmoplastic  
hidradenocarcinoma

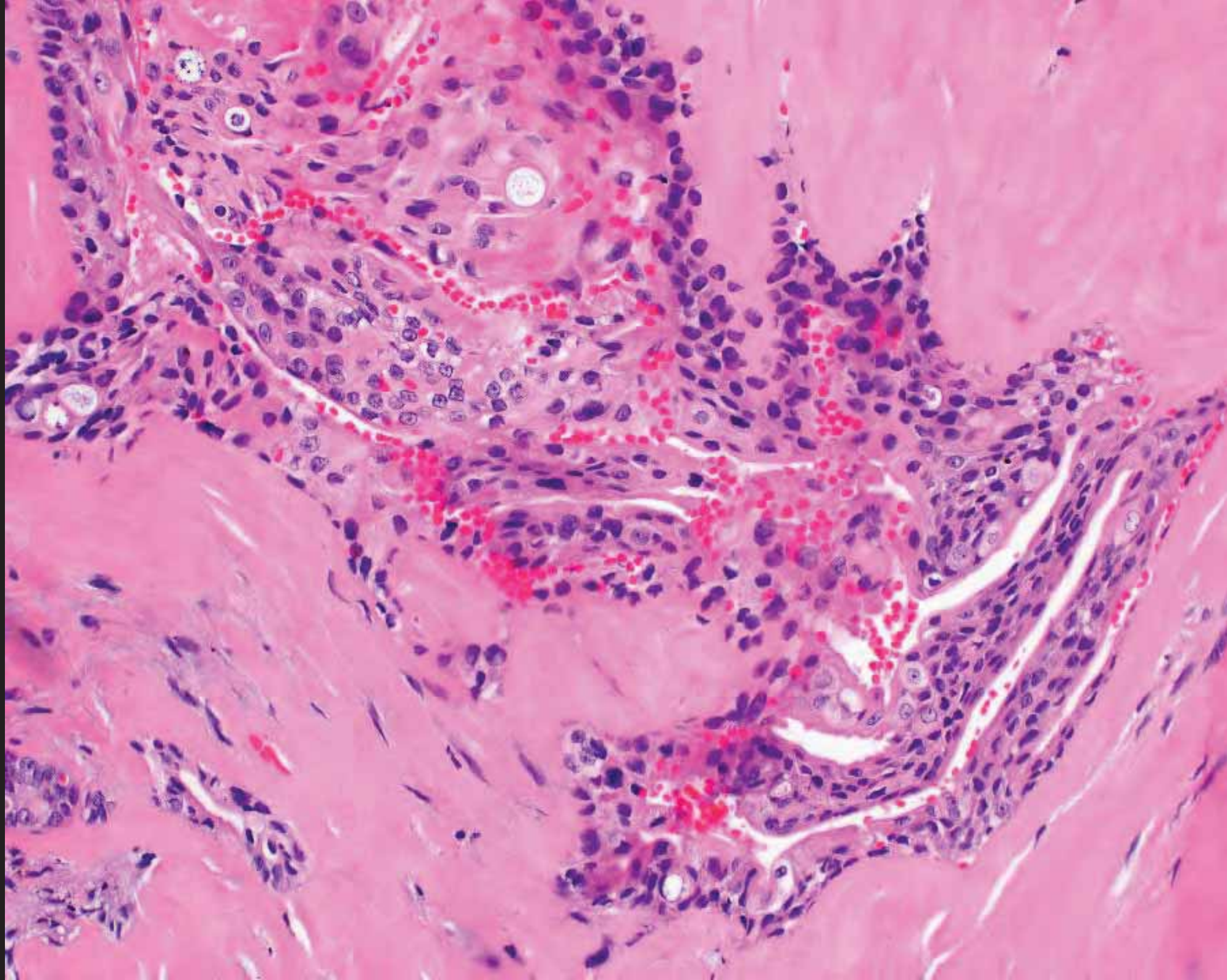
# Desmoplastic hidradenoma

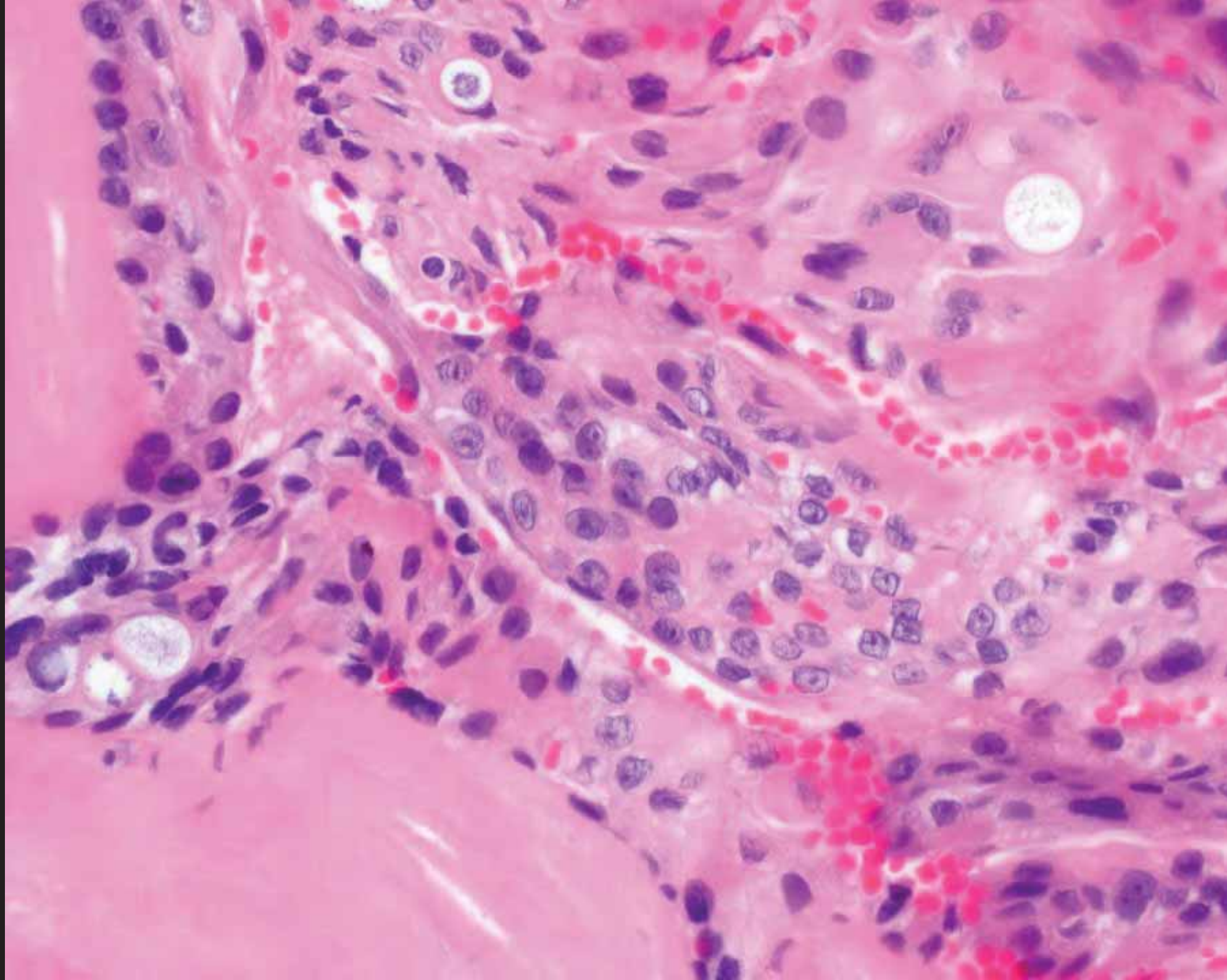


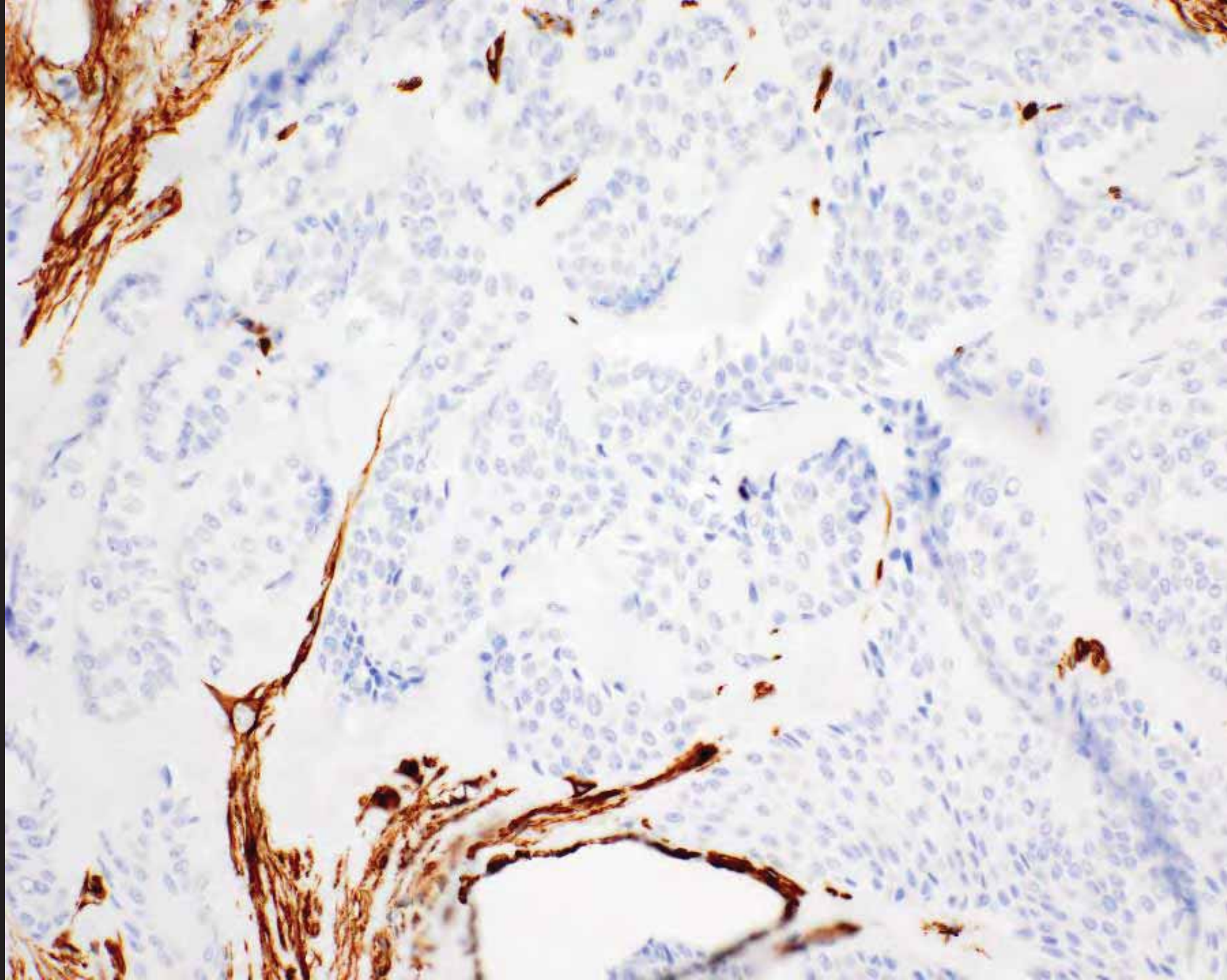


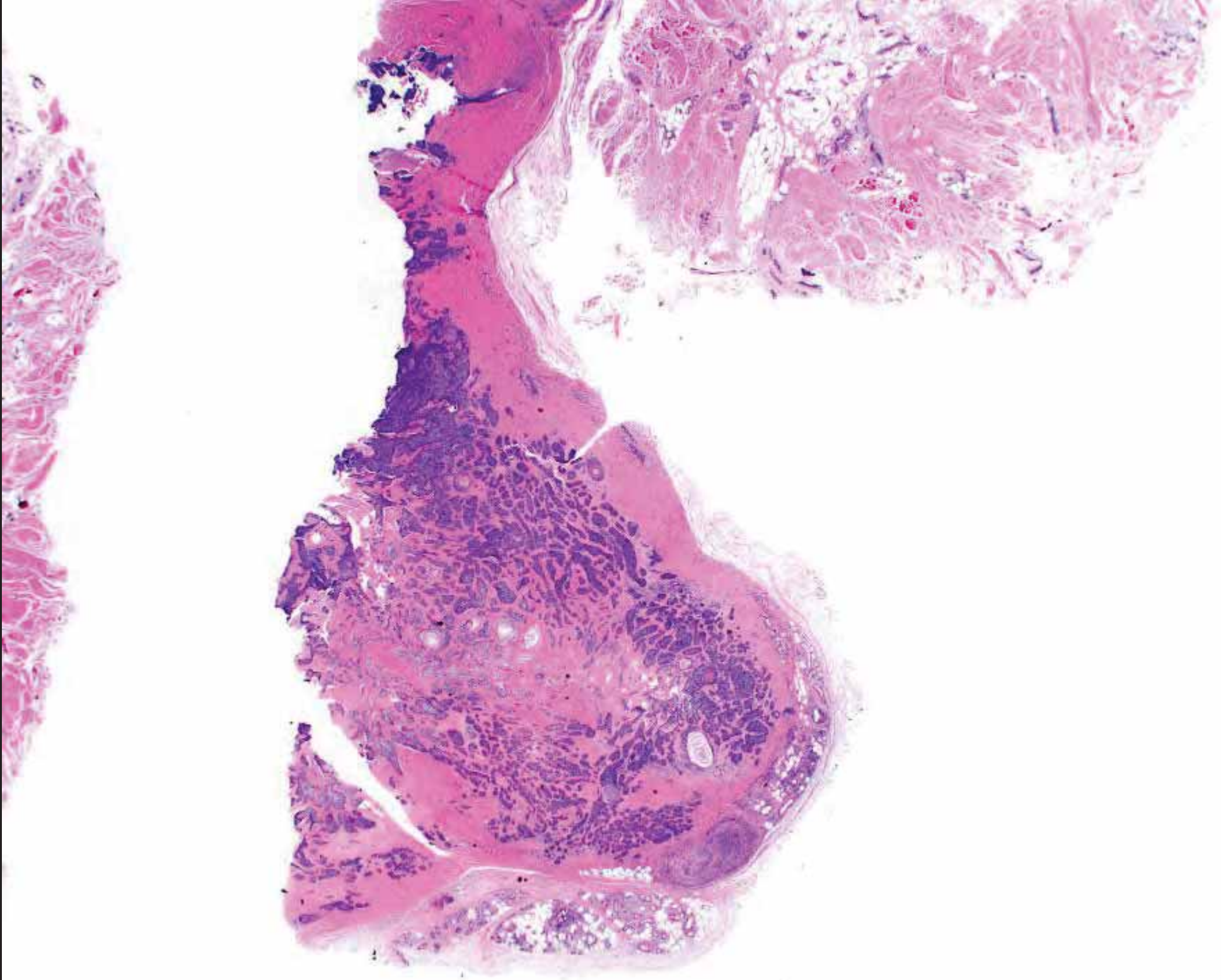


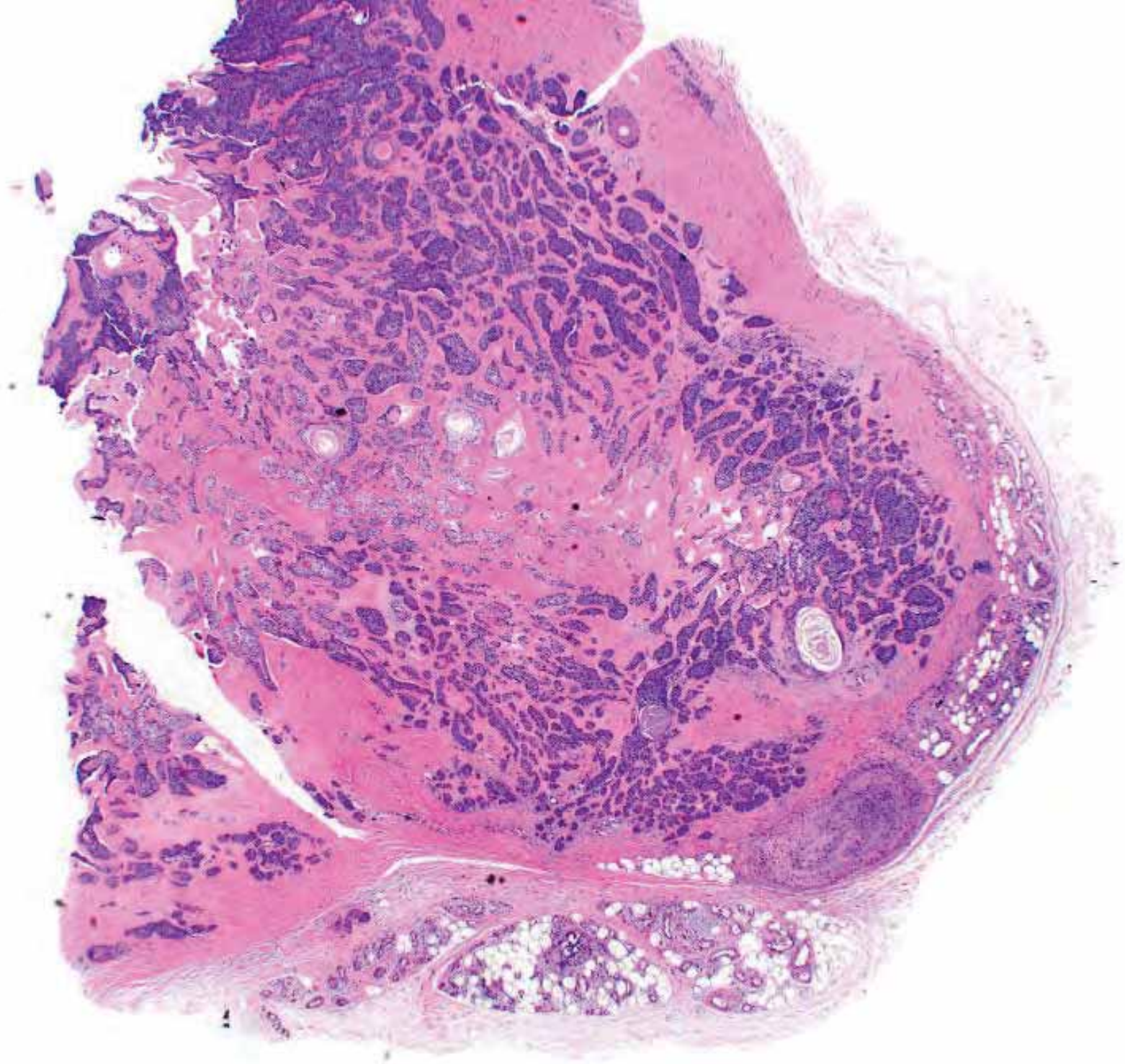


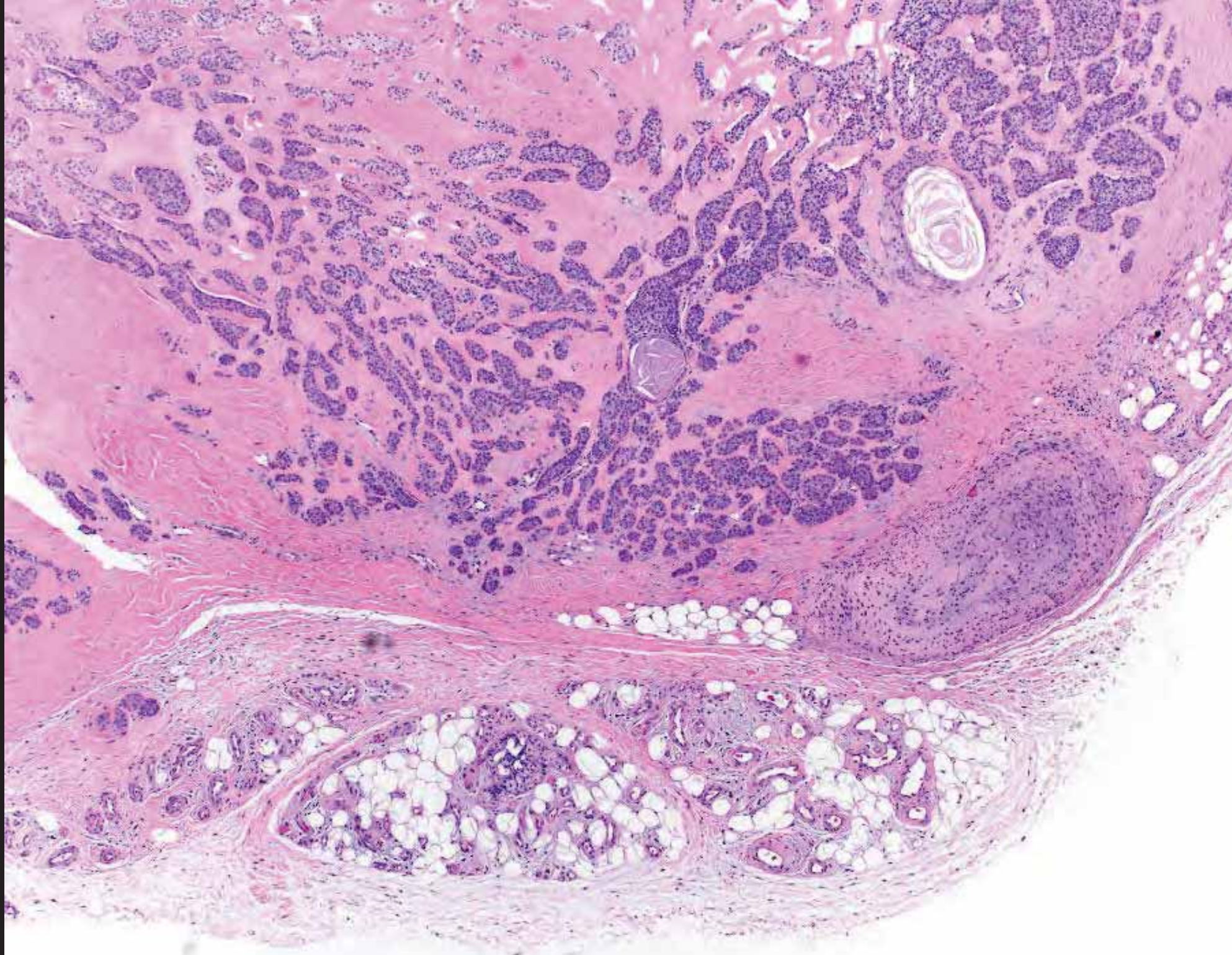


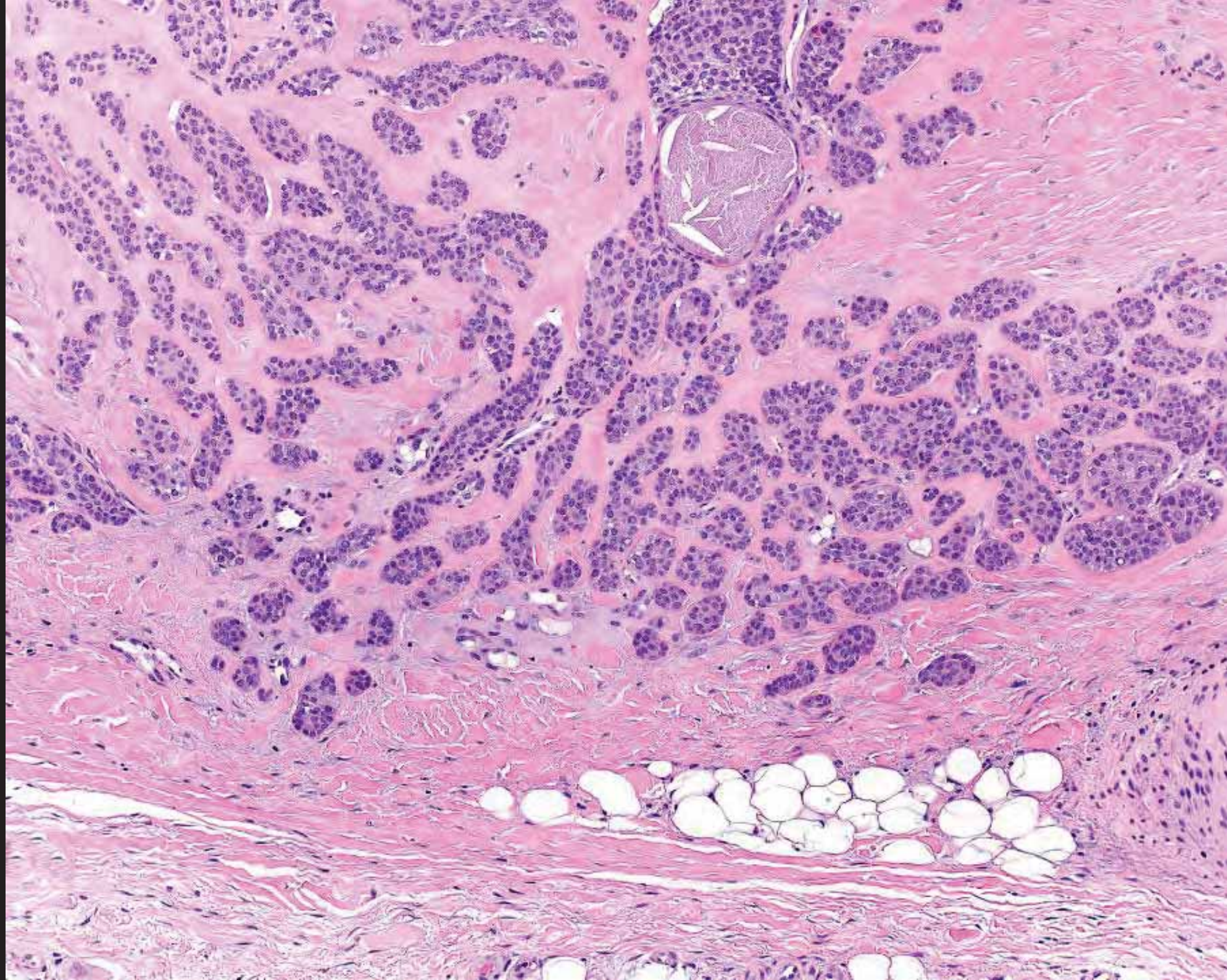


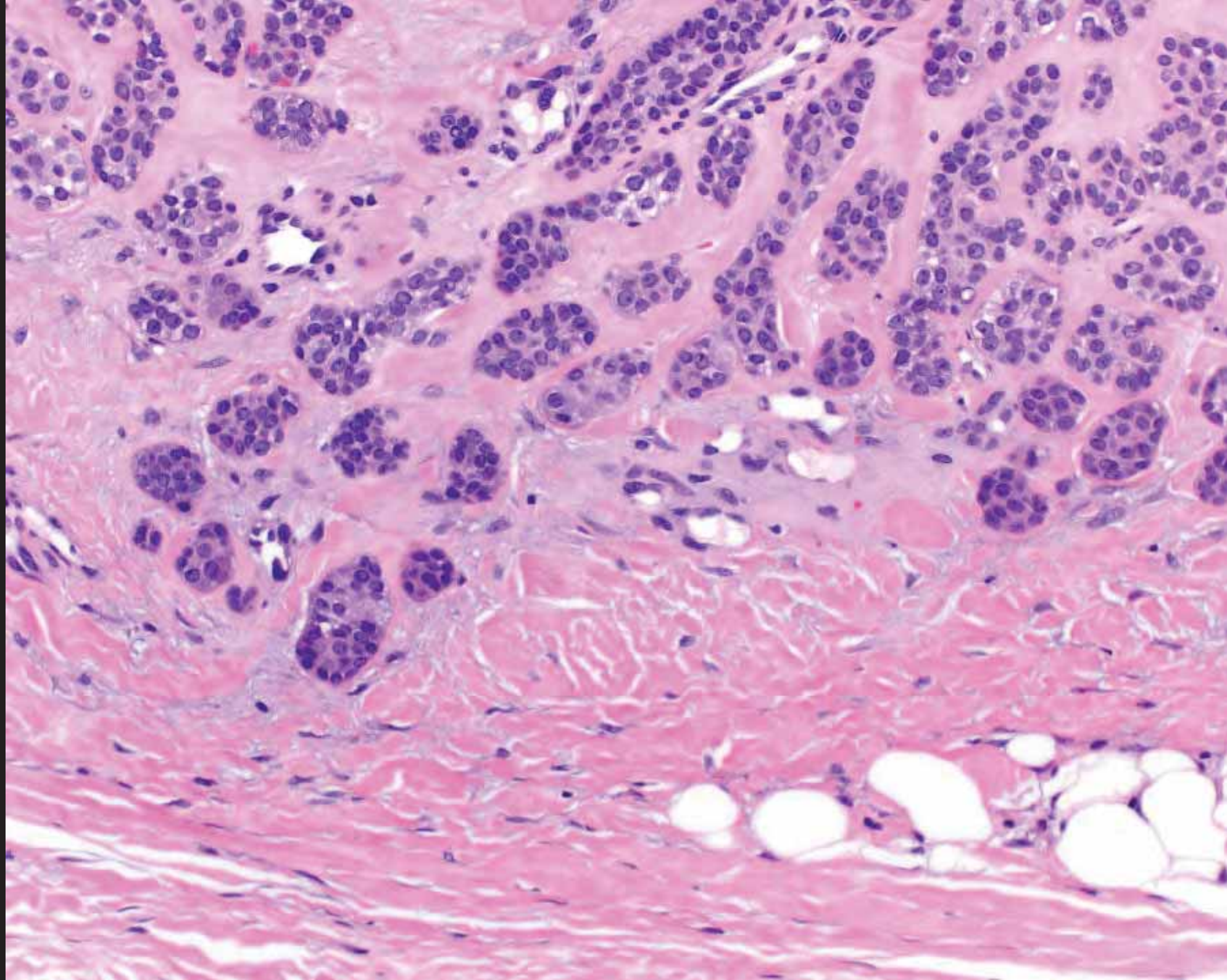


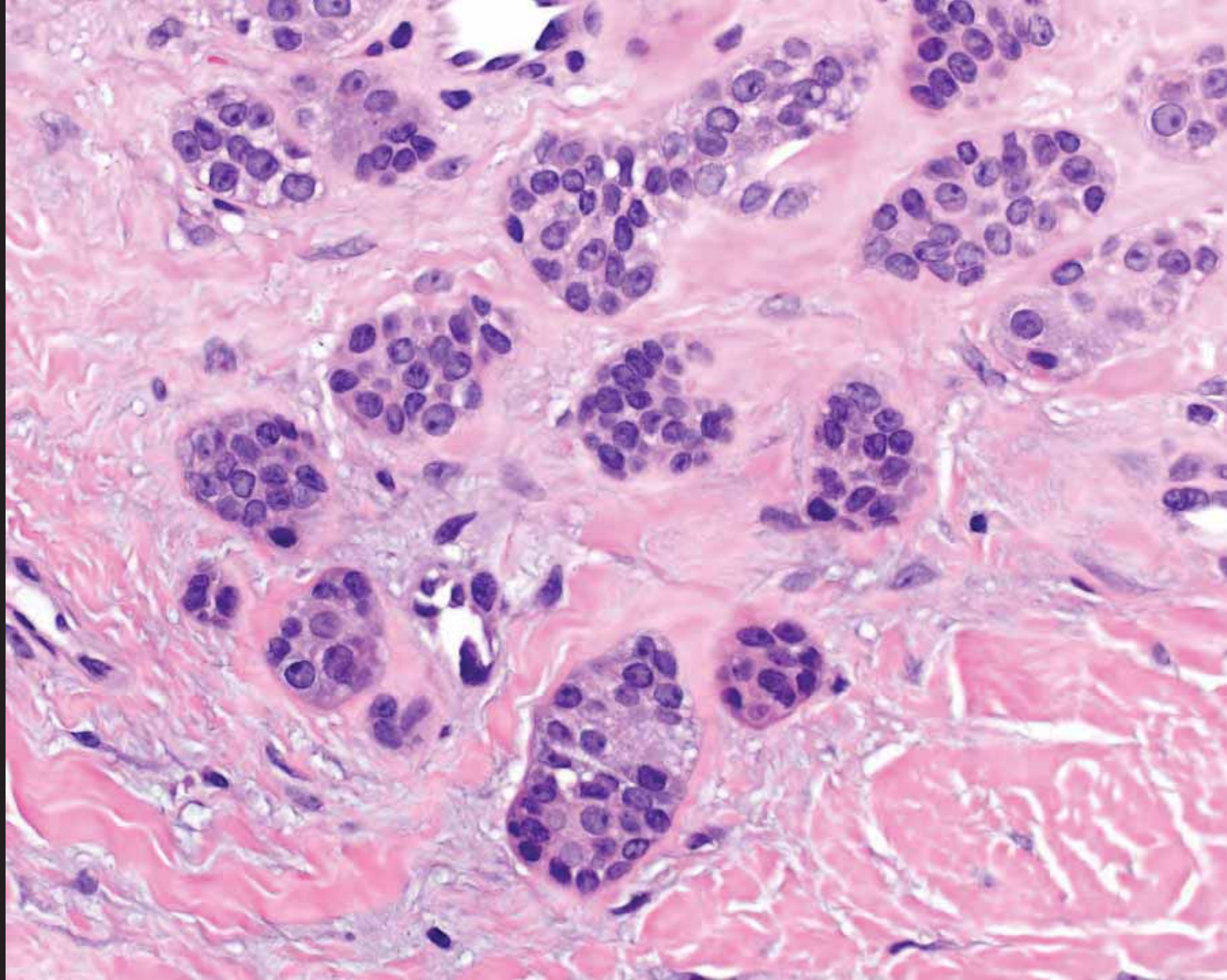


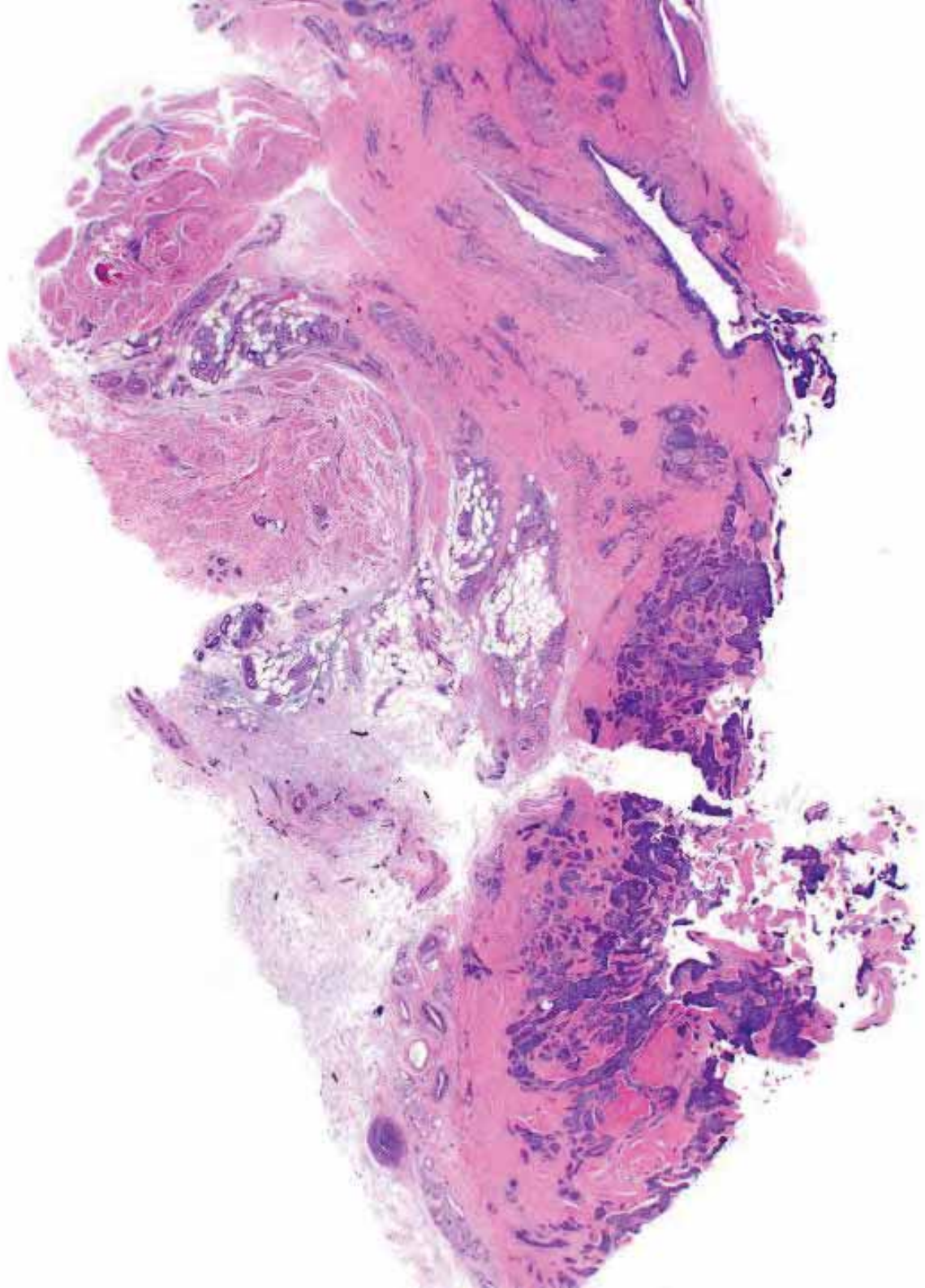


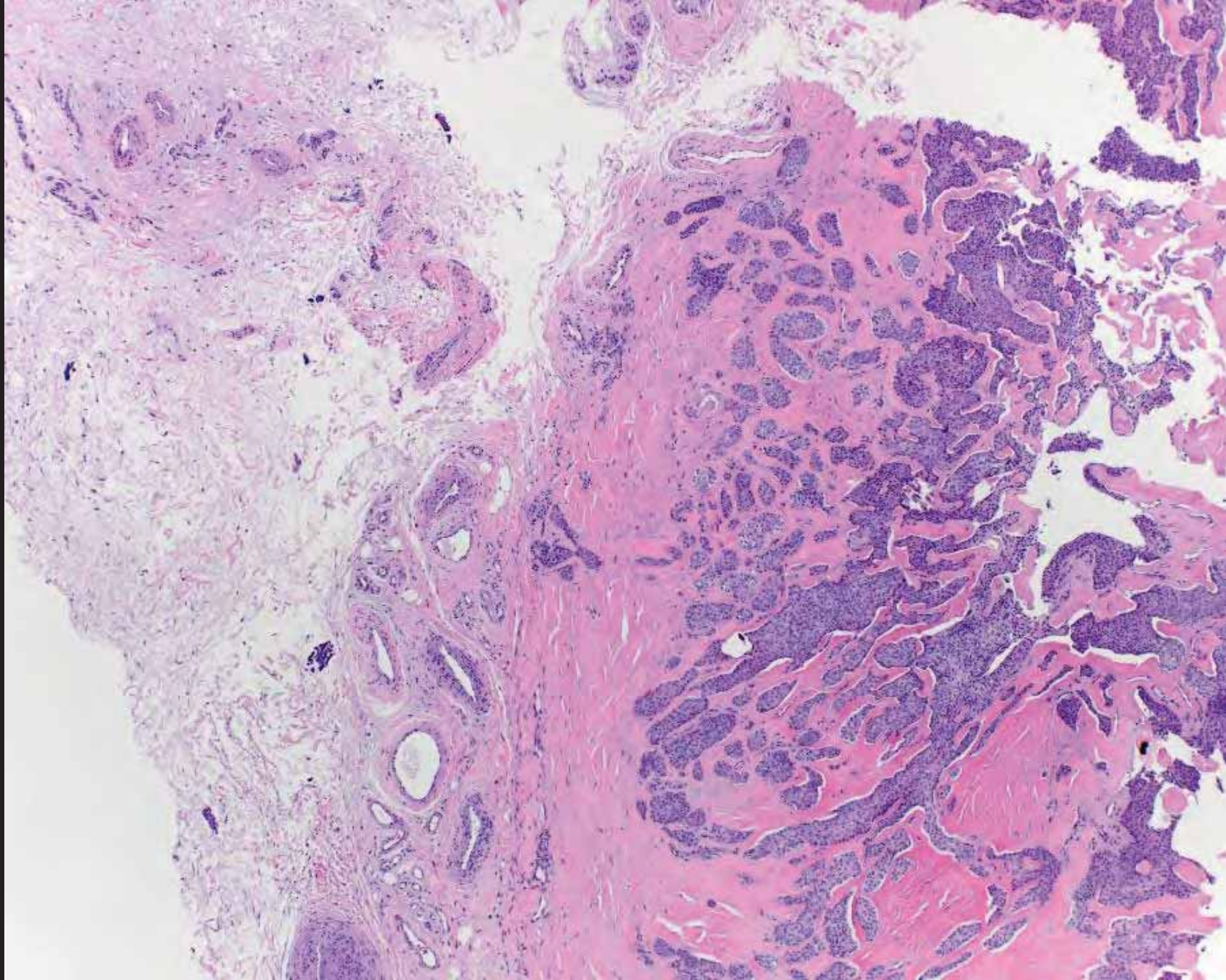


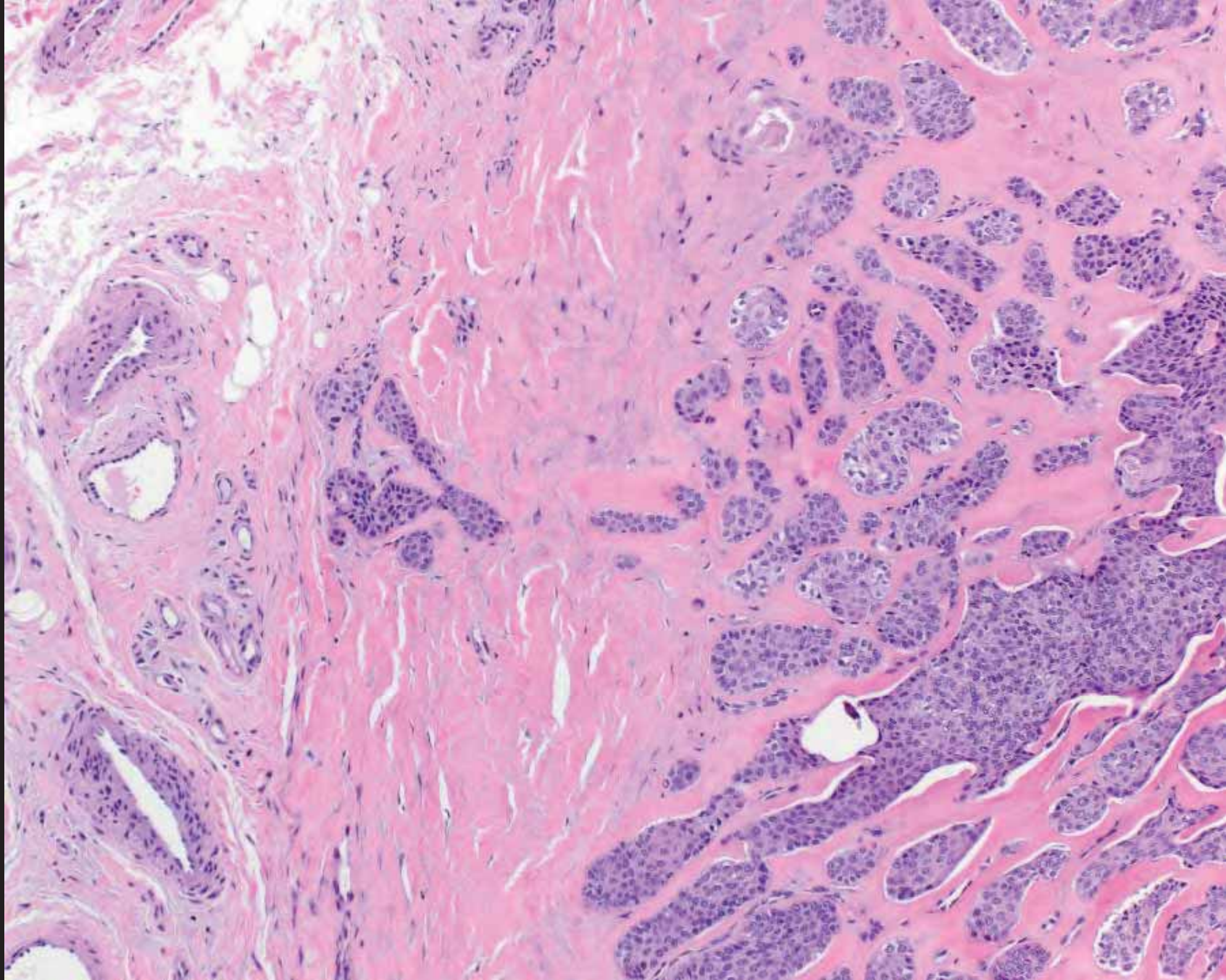


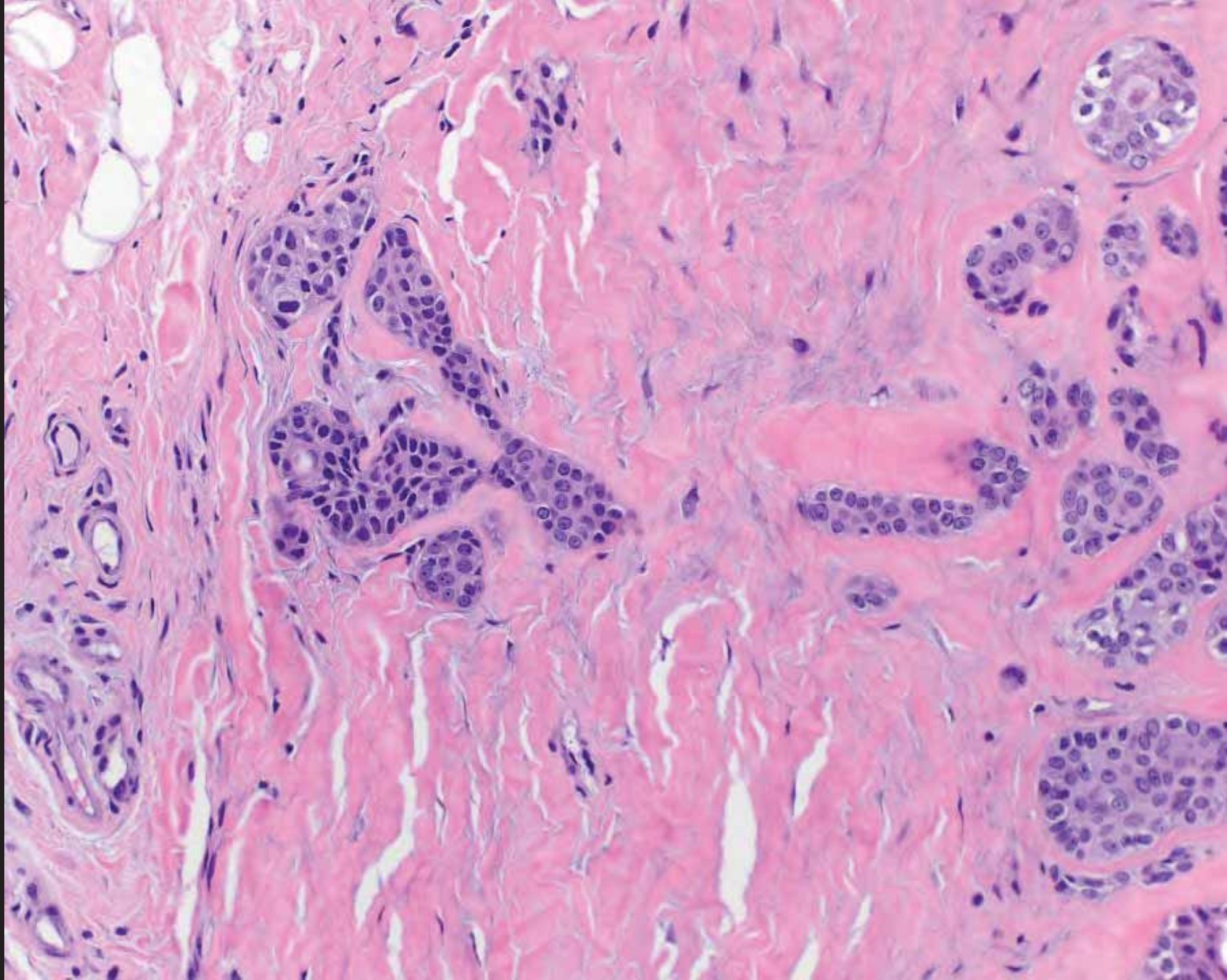


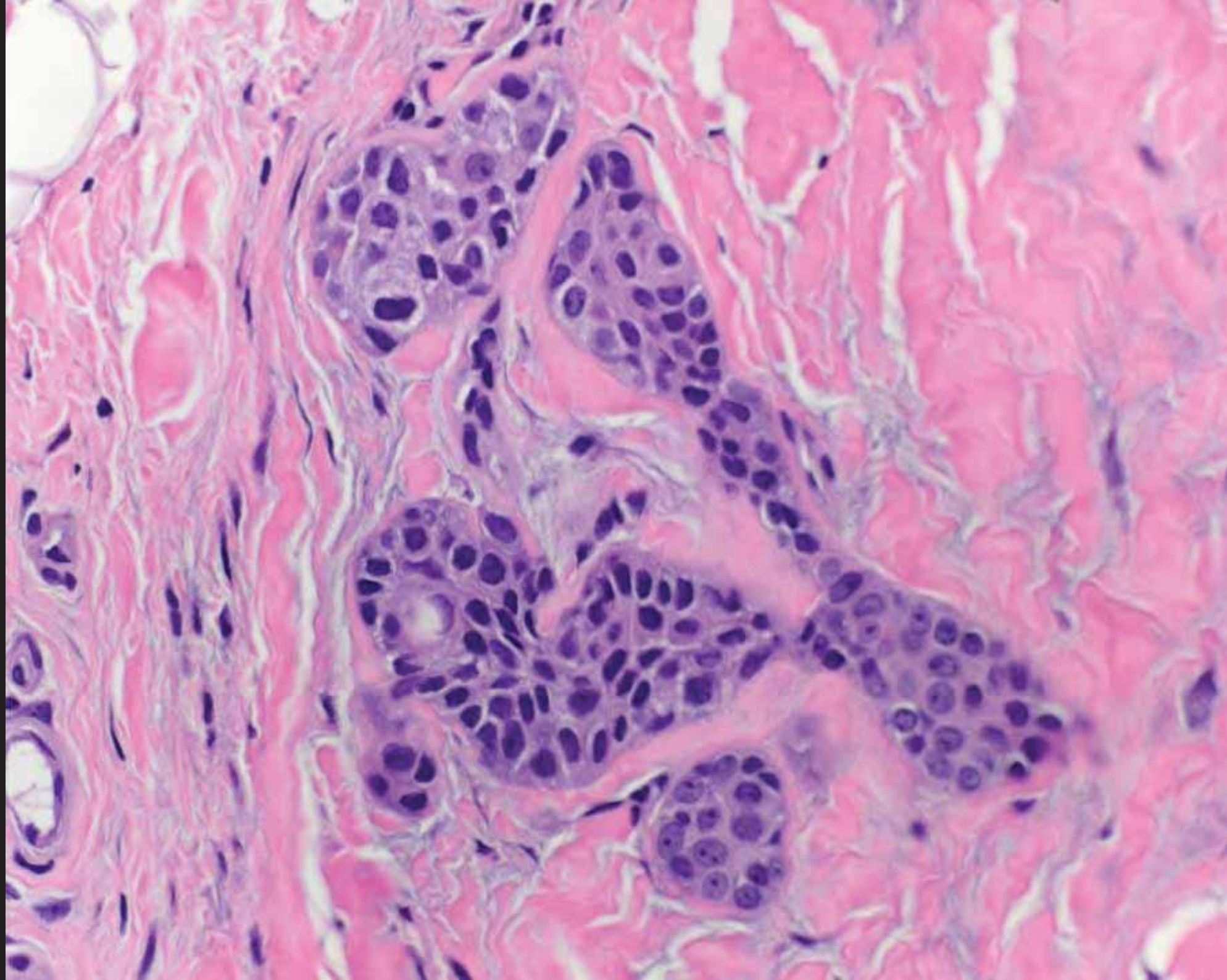


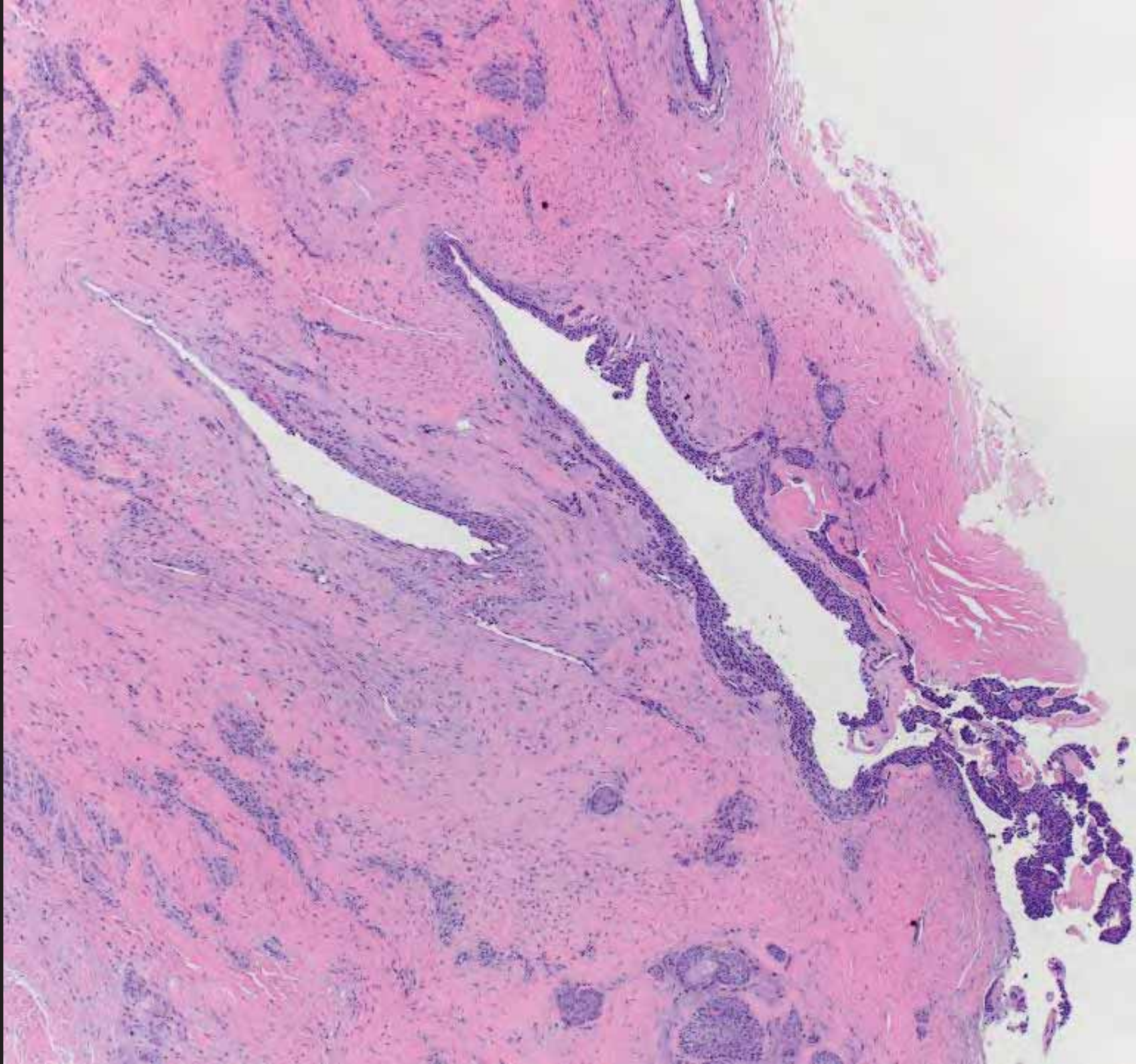


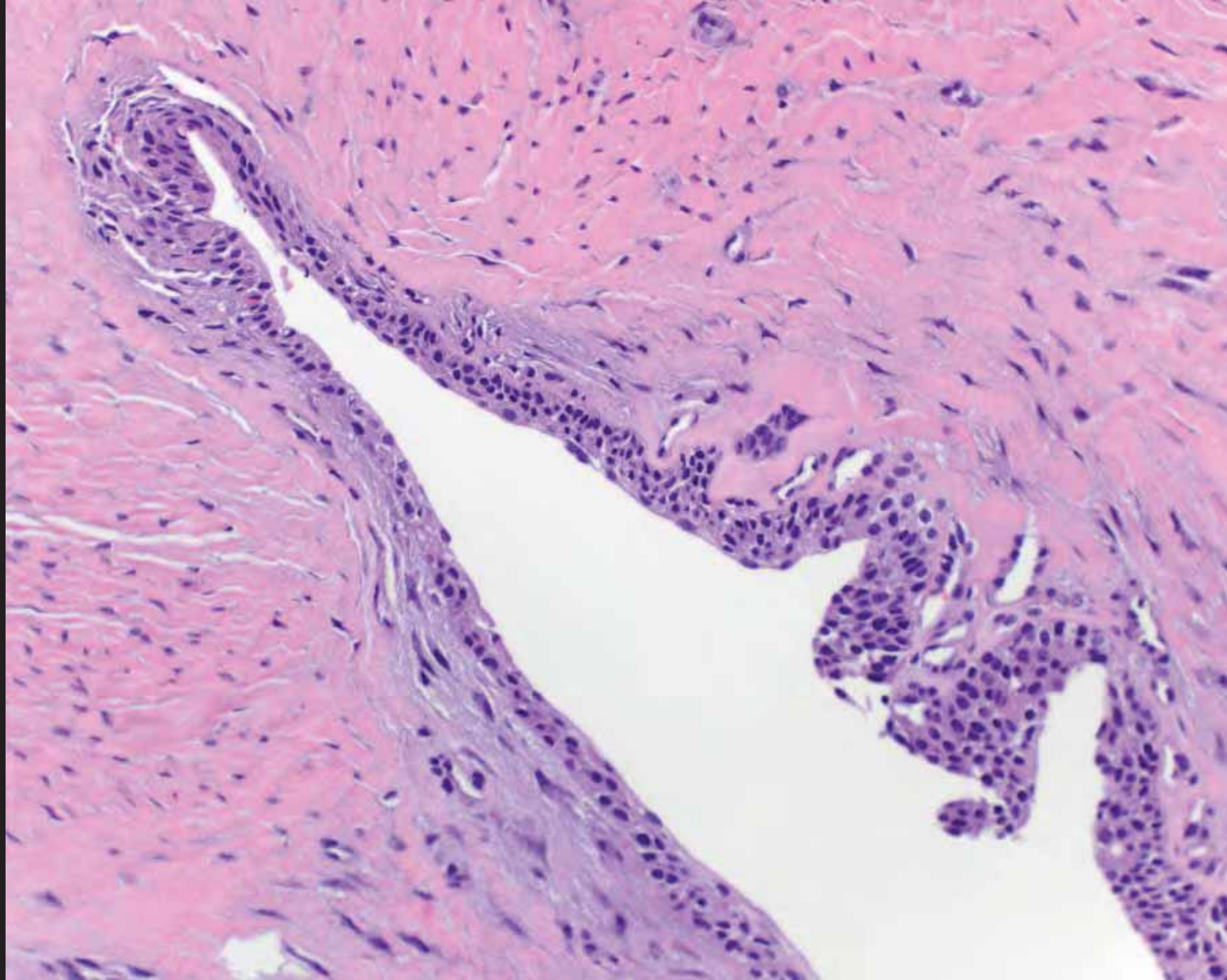


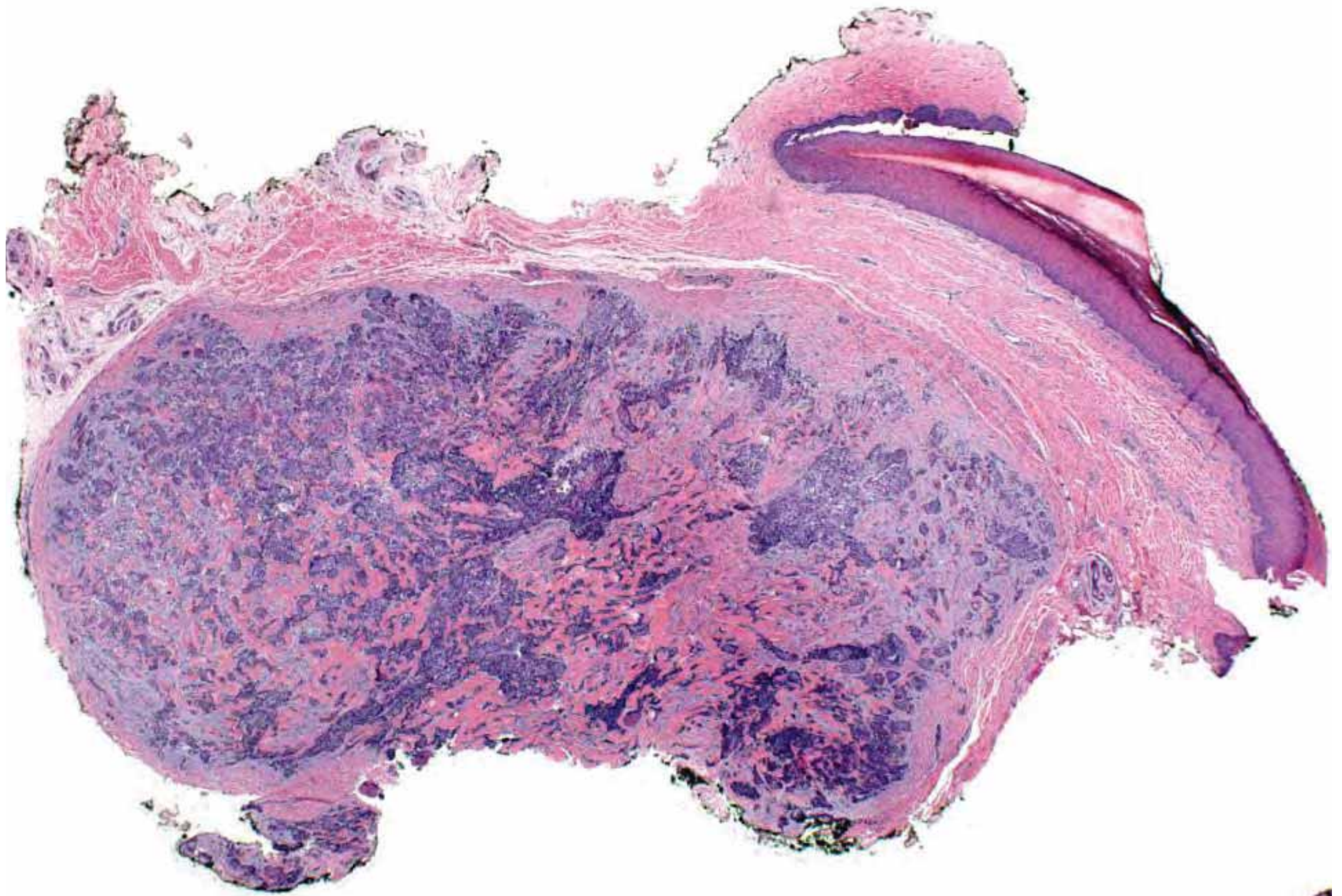


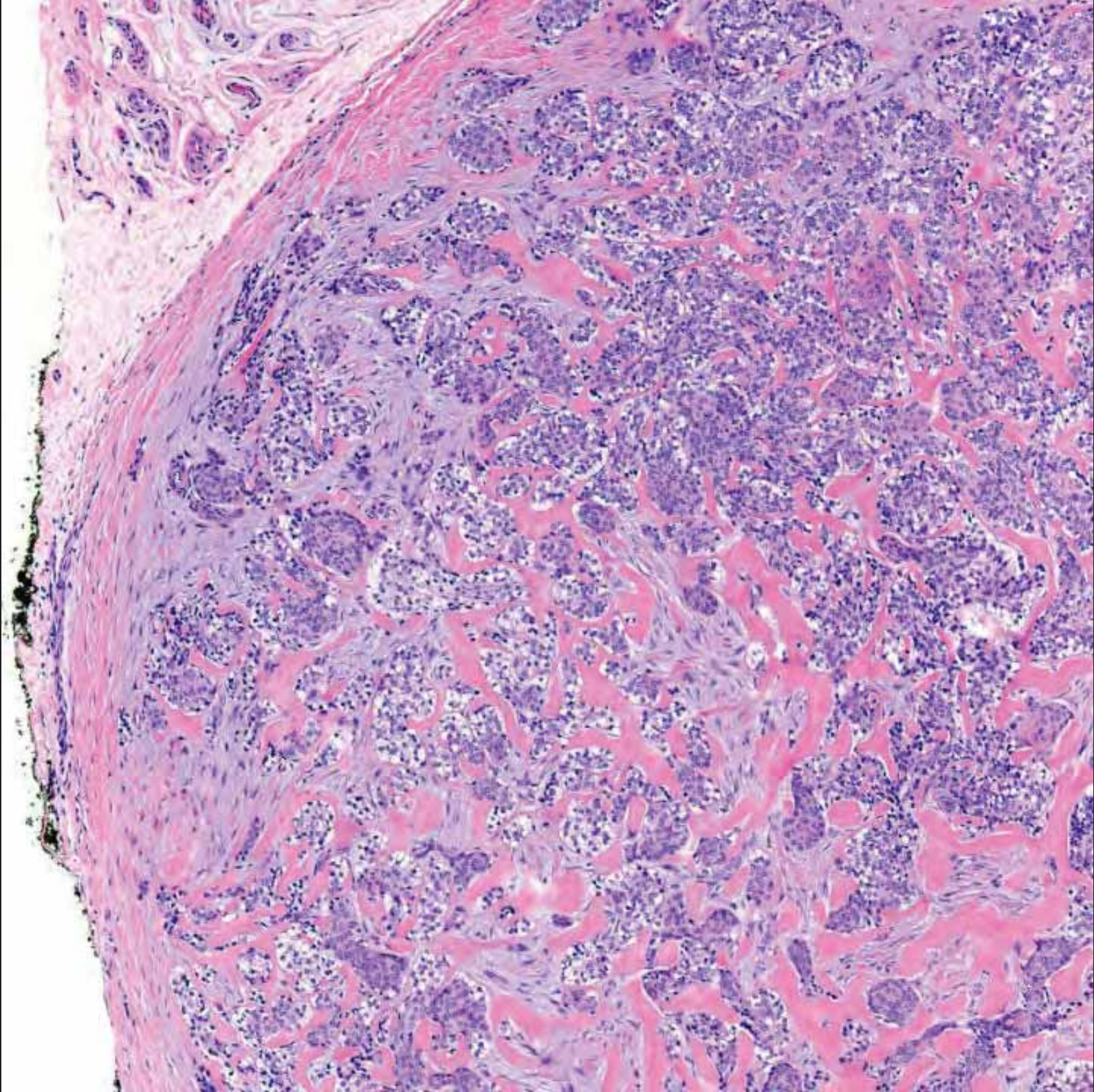


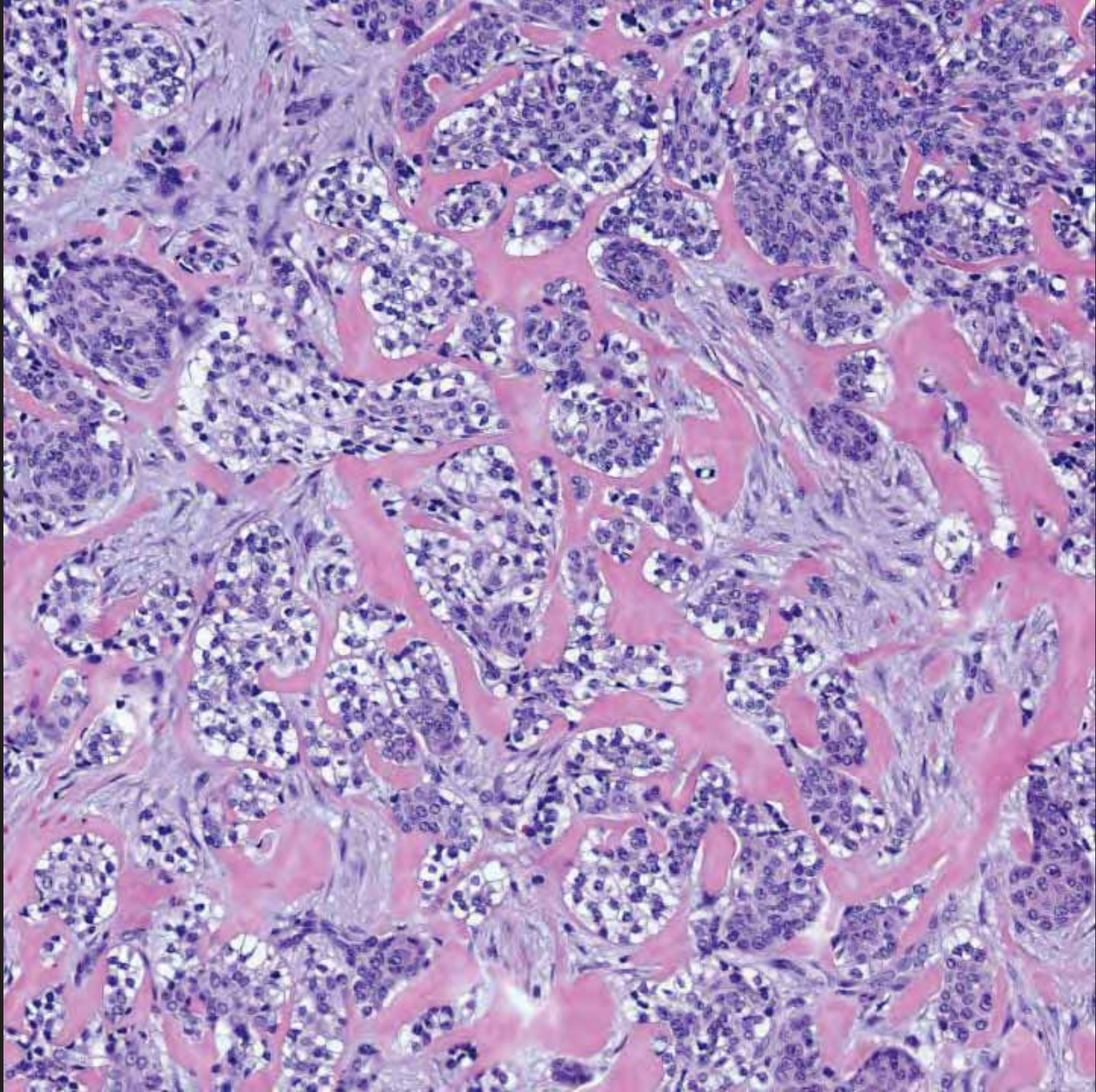


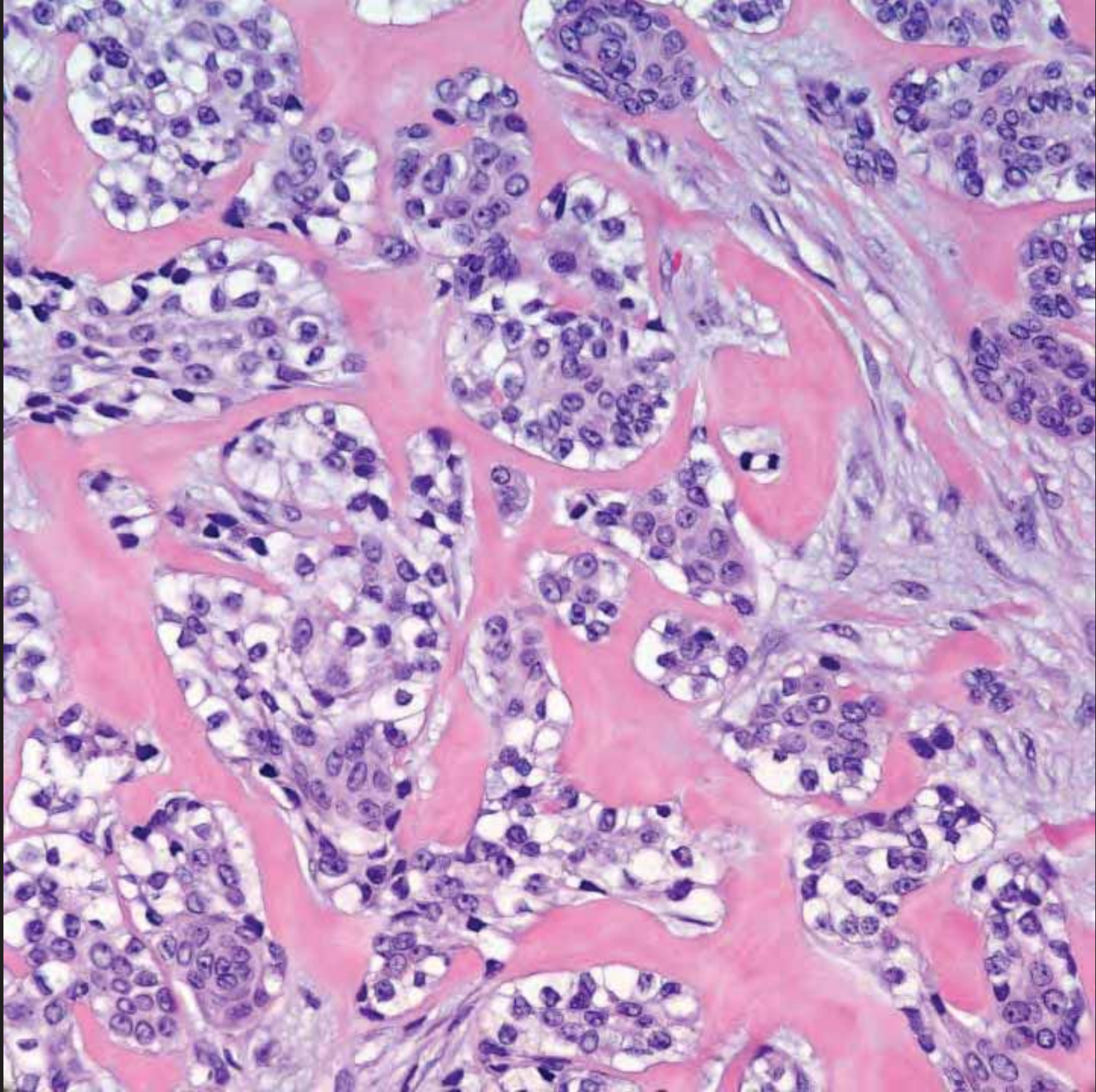


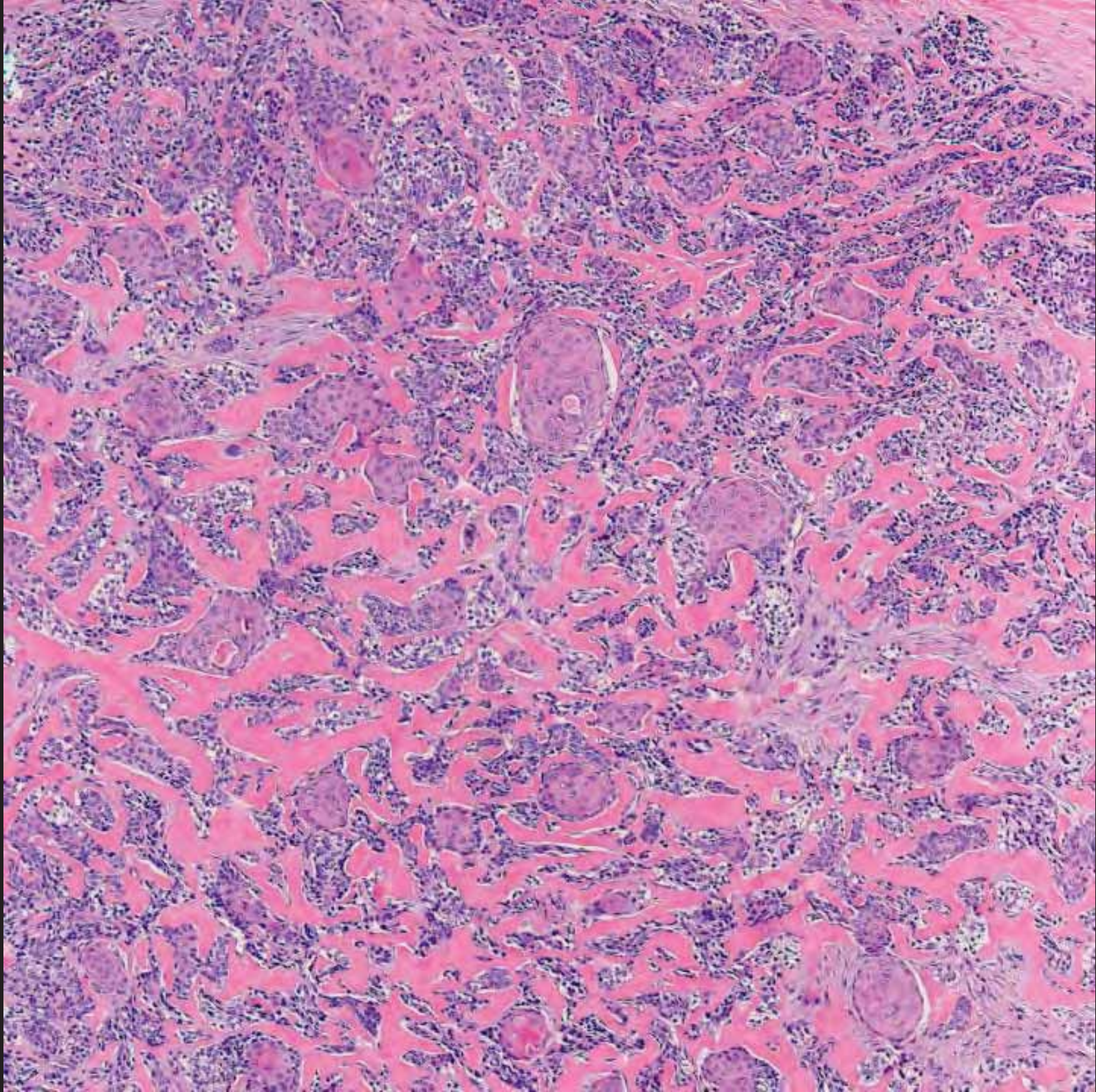


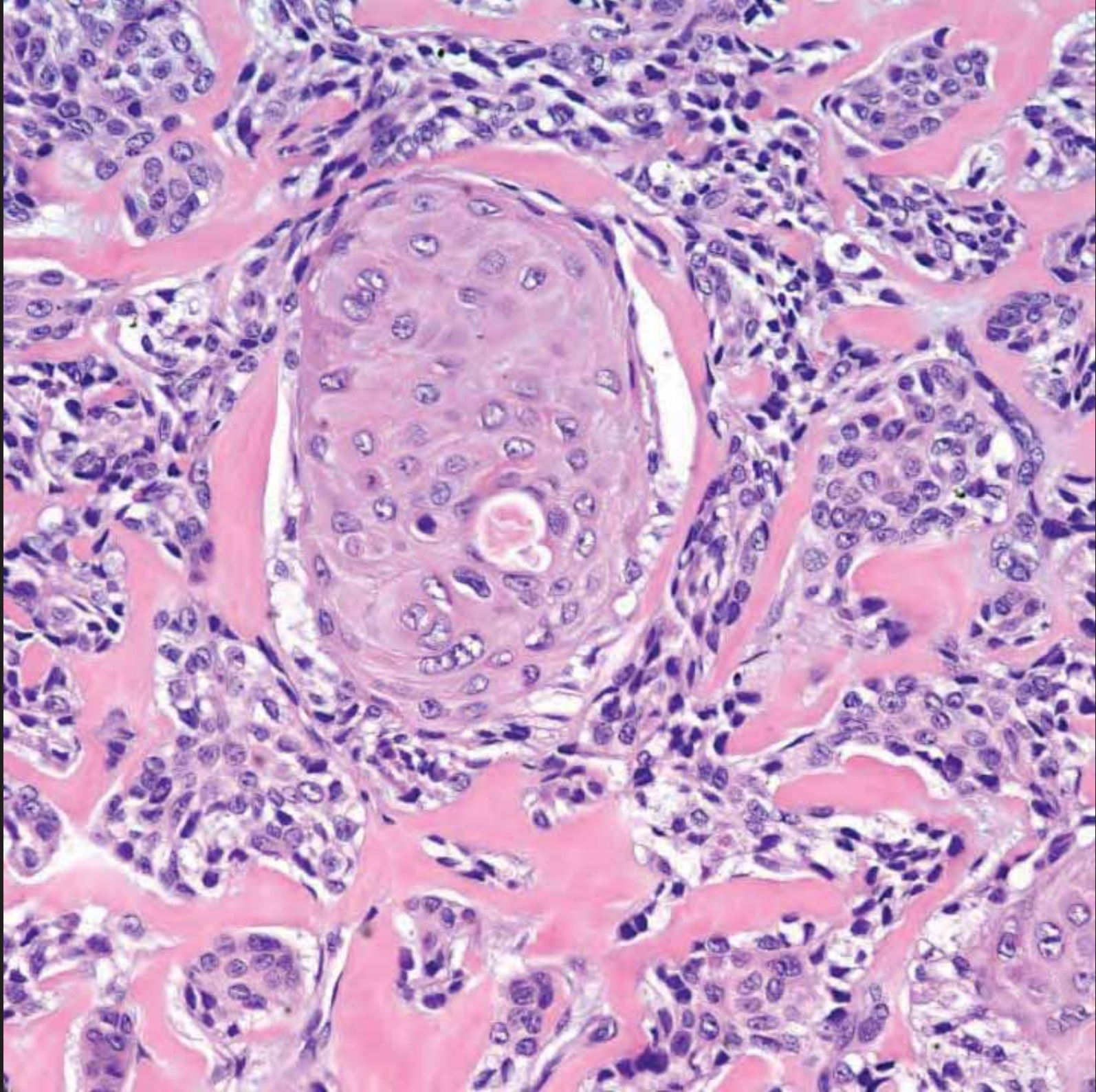


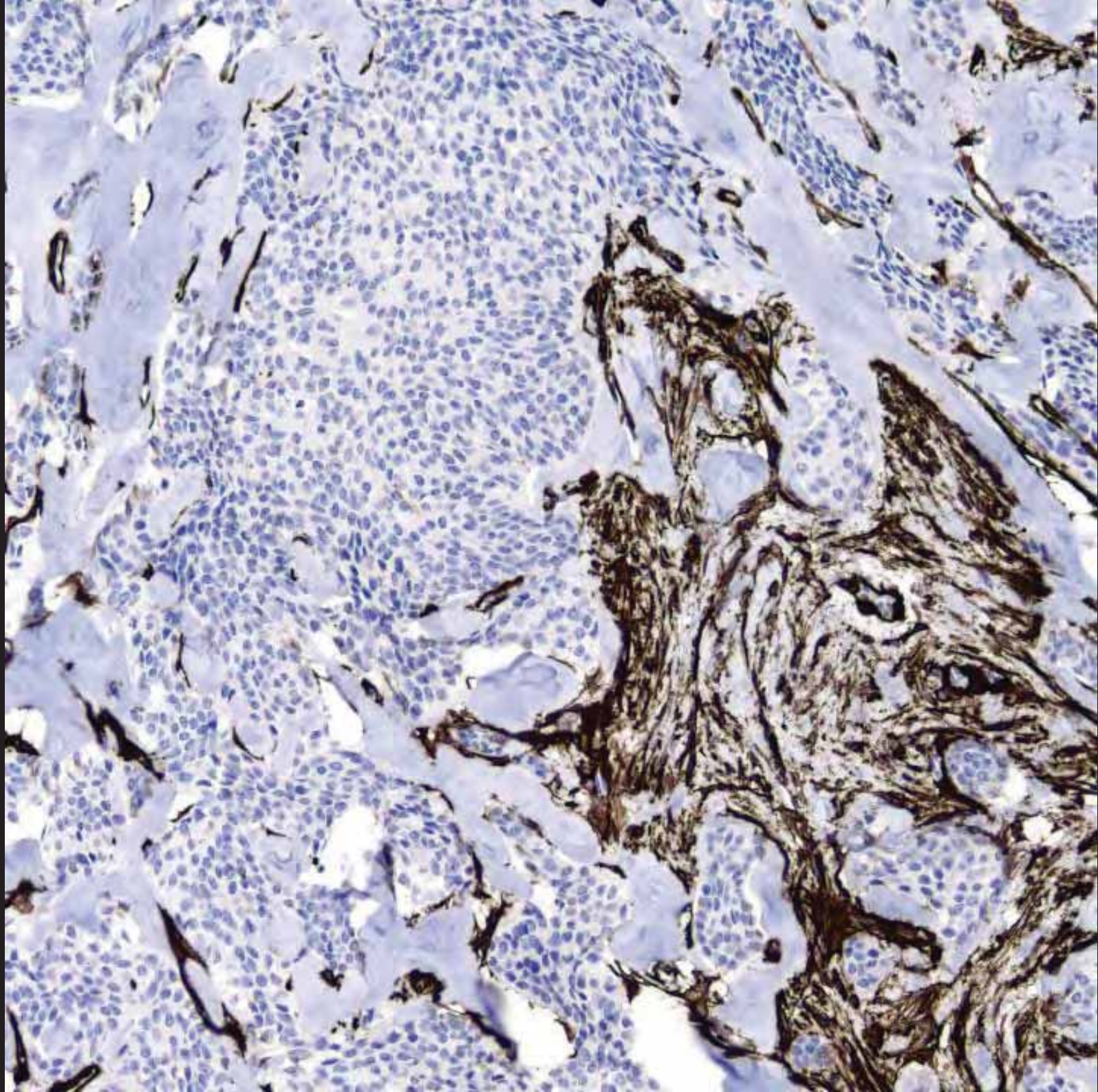












Are these just a variant of hidradenoma, or are these low grade hidradenocarcinomas?